



Assessment of functional and structural echocardiography parameters in patients with frequent premature ventricular contractions without structural heart disease

Hedieh Alimi MD⁽¹⁾ , Leila Bigdelu MD⁽²⁾ , Hoorak Poorzand MD, FASE⁽²⁾ ,
Fereshteh Ghaderi MD⁽²⁾ , Afsoon Fazlinejad MD, FASE⁽³⁾ , Maryam Emadzadeh MD⁽⁴⁾ ,
Banafsheh Ataei MD⁽⁵⁾ , Abdollah Kerachian MD⁽⁶⁾ 

Original Article

Abstract

BACKGROUND: Premature ventricular contractions (PVCs) are early depolarizations of the myocardium which originate from the ventricle. PVCs have previously been considered a benign condition. The clinical significance of PVCs in patients without structural heart disease is controversial.

METHODS: In this cross-sectional study, patients with a palpitation complaint who underwent electrocardiography (ECG) Holter recording for 48 hours were analyzed. Patients with frequent PVCs (more than ten times in 1 hour) were identified and enrolled in the study. 26 patients were in the PVC group, and 26 patients were in the control group without PVC. The identified patients underwent an echocardiographic examination with strain modality.

RESULTS: There were 15 women (57.7%) in the PVC group and 17 women (65.4%) in the control group ($P = 0.57$). Two patients in the PVC group and three patients in the control group were hypertensive ($P > 0.99$). There was only one patient with diabetes in PVC and control group ($P > 0.99$). There were two smokers in the PVC group, whereas there was no smoker in the control group ($P = 0.49$). In comparison between two groups, patients with frequent PVCs had significantly larger left ventricular end-diastolic volume index (LVEDVI) ($P = 0.048$) along with lower left ventricular ejection fraction (LVEF) ($P = 0.011$), lower (more positive) left ventricular global longitudinal strain (LVGLS) ($P = 0.001$), and lower peak systolic mitral annular velocity (S') ($P = 0.045$). The left atrial volume index (LAVI) was significantly larger in the PVC group ($P = 0.001$). In speckle tracking echocardiography (STE) parameters, global peak atrial longitudinal strain (PALS) ($P = 0.001$) and peak atrial contraction strain (PACS) ($P = 0.001$) were significantly lower and time to peak longitudinal strain (TPLS) ($P = 0.002$) was significantly higher in the PVC group.

CONCLUSION: In this study, left atrial (LA) and left ventricular (LV) function and geometry were adversely affected by frequent PVCs. Early diagnosis of these effects is possible with echocardiography along with strain analysis. It can guide the timely treatment of PVC to avoid the harmful effects of frequent PVCs on the heart.

Keywords: Premature Ventricular Complexes; Left Atrial Function; Left Ventricular Function

Date of submission: 07 Jan. 2021, *Date of acceptance:* 22 May 2021

Introduction

Premature ventricular contractions (PVCs) are early depolarizations of the myocardium which originate from the ventricle. The estimated prevalence of

PVCs is 1% to 4% in the general population.¹

PVCs have previously been considered a benign condition. The clinical significance of PVCs in patients without structural heart disease is controversial.²

1- Assistant Professor of Cardiology, Vascular and Endovascular Surgery Research Center, School of Medicine, Mashhad University of Medical Sciences, Mashhad, Iran

2- Associate Professor of Cardiology, Vascular and Endovascular Surgery Research Center, School of Medicine, Mashhad University of Medical Sciences, Mashhad, Iran

3- Professor, Department of Cardiology, School of Medicine, Mashhad University of Medical Sciences, Mashhad, Iran

4- Assistant Professor of Community Medicine, Clinical Research Development Unit, Ghaem Hospital, Mashhad University of Medical Sciences, Mashhad, Iran

5- Resident of Internal Medicine, Department of Internal Medicine, School of Medicine, Mashhad University of Medical Sciences, Mashhad, Iran

6- Echocardiologist, Mashhad University of Medical Sciences, Mashhad, Iran

Address for correspondence: Abdollah Kerachian; Echocardiologist, Mashhad University of Medical Sciences, Mashhad, Iran

Email: kerachian.a@gmail.com

How to cite this article: Alimi H, Bigdelu L, Poorzand H, Ghaderi F, Fazlinejad A, Emadzadeh M, et al. **Assessment of functional and structural echocardiography parameters in patients with frequent premature ventricular contractions without structural heart disease.** ARYA Atheroscler 2022; 18: 2359.

In recent years, it has been documented that frequent PVCs can lead to left ventricular (LV) systolic dysfunction.³ Most studies consider a frequency cutoff of 10 PVCs per hour as a threshold for increased risk.⁴ In patients with normal LV ejection fraction (LVEF), frequent PVC is associated with left atrial (LA) enlargement. In patients with frequent PVCs, atrial remodeling happens before changing in the LV geometry.⁵

It has been demonstrated that frequent PVCs in otherwise healthy patients are associated with LA remodeling, larger LA volume, and trapezoidal LA shape.⁶ Speckle tracking echocardiography (STE) revealed that in patients with PVCs, LV systolic functions decreased. This adverse effect increased with exposure time and the frequency of PVCs.² PVCs may be a modifiable risk factor for heart failure that can be successfully treated with pharmacological therapies or catheter ablation.⁷

We aimed to investigate PVCs' effects on the LV and LA function using conventional echocardiography with strain modality.

Materials and Methods

Patients: This cross-sectional study was conducted in Ghaem and Imam Reza Hospitals, Mashhad, Iran, from April 2018 to February 2019. 26 patients were in the PVC group, and 26 patients were in the control group without PVC. We did not match the patients in the case and control groups. All patients provided informed written consent. The local scientific ethics committee approved the study (IR.MUMS.MEDICAL.REC.1398.142).

In this study, patients with palpitation complaints who underwent ambulatory electrocardiography (ECG) Holter recording with portable Telesmart Holter Recorder (MEDSET, Germany) were analyzed for 48 hours. Patients with frequent PVCs (more than ten times in 1 hour) were identified and enrolled in the study group, and patients without PVCs were included in the control group. The identified patients underwent an echocardiographic examination. Measurements were not done during PVC or post PVC beats. Heart rate and blood pressure at the time of echocardiography were in the normal range.

Exclusion criteria included LV hypertrophy, ischemic heart disease (IHD), LVEF < 50%, right ventricular (RV) dysfunction, pulmonary hypertension (PH), electrolyte abnormality, uncontrolled systemic or metabolic disease, moderate or severe valvular heart disease, and low echocardiographic image quality. Patients with any history of atrial fibrillation (AF), thyroid diseases, and substance abuse were also excluded from the study.

Conventional echocardiography: Transthoracic echocardiography (TTE) was done using Siemens ACUSON SC2000 Ultrasound System with 4V1c Transducer (frequency bandwidth: 1.25-4.5 MHz). All measurements were made following the current American Society of Echocardiography (ASE) guideline recommendations.⁸

We evaluated LV end-diastolic volume index (LVEDVI), interventricular septum (IVS), posterior wall (PW), LVEF, early diastolic mitral inflow velocity (E velocity), late diastolic mitral inflow velocity (A velocity), early diastolic mitral annulus velocity (e'), late diastolic mitral annulus velocity (a'), deceleration time (DT) of E wave, peak systolic mitral annulus velocity (S' velocity), E/e' ratio, and LA volume index (LAVI).

Quantification of LV dimension, LVEDVI, and LVEF (using biplane Simpson's method) was performed according to the latest guideline of the ASE.⁸

LAVI was measured by using a biplane disk summation technique. The LAVI's normal upper limit was calculated 34 ml/m² for both genders.⁸

For diastolic function, peak E-wave velocity, peak A-wave velocity, pulsed-wave tissue Doppler imaging (TDI) e' velocity, and E/e' were calculated according to ASE recommendation.⁹⁻¹¹

Velocity vector imaging (VVI): Two-dimensional (2D) strain imaging is an echocardiographic modality that uses standard B-mode images for speckle tracking analysis. Strain examines myocardial deformation, and strain rate evaluates the rate of change in strain and can be measured throughout the cardiac cycle.^{12,13}

LA strain can be measured by TDI, 2D STE, and VVI.^{12,14} Novel quantitative techniques such as STE and TDI can reliably measure LV strain which have a more sensitive diagnostic potential.¹⁵

VVI is an endocardial border tracking technique; therefore, VVI can track the movement of a thin-walled structure such as the LA.¹⁶

For VVI analysis of LA, 2D images of apical two and four-chamber views were obtained with frame rates between 70-100 Hz. We used R-R gating for

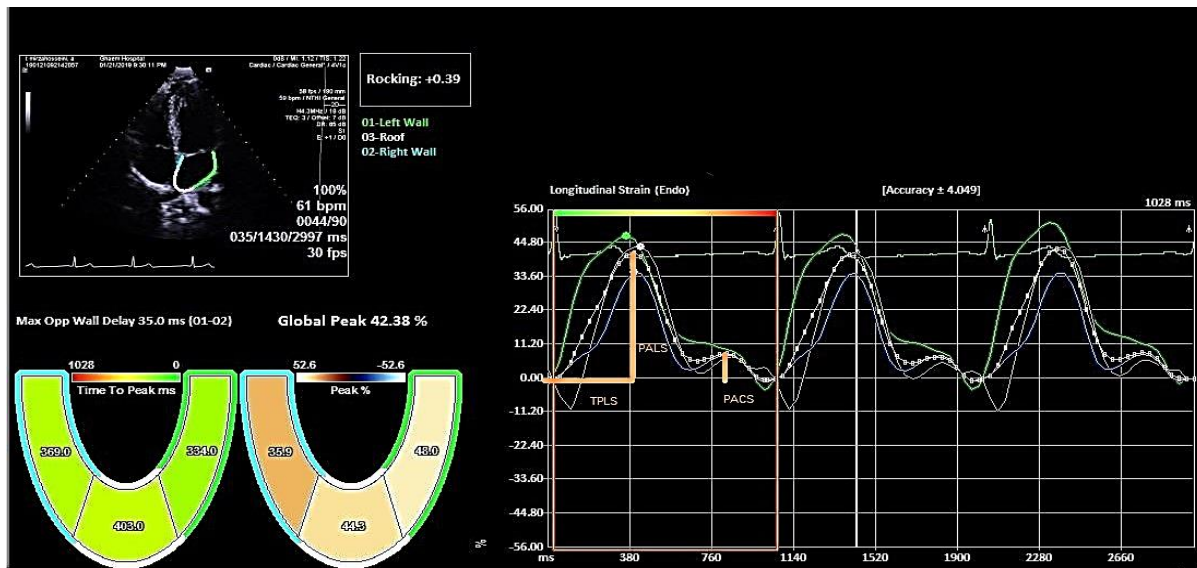


Figure 1. Strain analysis of left atrium (LA) for calculating peak atrial longitudinal strain (PALS), peak atrial contraction strain (PACS), and time to peak longitudinal strain (TPLS)

calculating LA strain. The endocardium of the LA was traced manually. The region of interest (ROI) was delineated and traced, starting from the mitral annulus's lateral side, and ending at the medial side, excluding the pulmonary veins and LA appendage (LAA) (Figure 1). The strain and strain rate measures were calculated automatically.^{12,14}

The strain analysis for LV was performed using three apical views (apical four-chamber, two-

chamber, and long-axis views). The ROI was delineated and traced, global longitudinal strain (GLS) was calculated automatically, and their average was obtained (Figure 2). Measurements began with the apical long-axis view to visualize aortic valve closure.⁸ Global peak atrial longitudinal strain (PALS), time to peak longitudinal strain (TPLS), peak atrial contraction strain (PACS), and left ventricular global longitudinal strain (LVGLS) were evaluated by the VVI method.

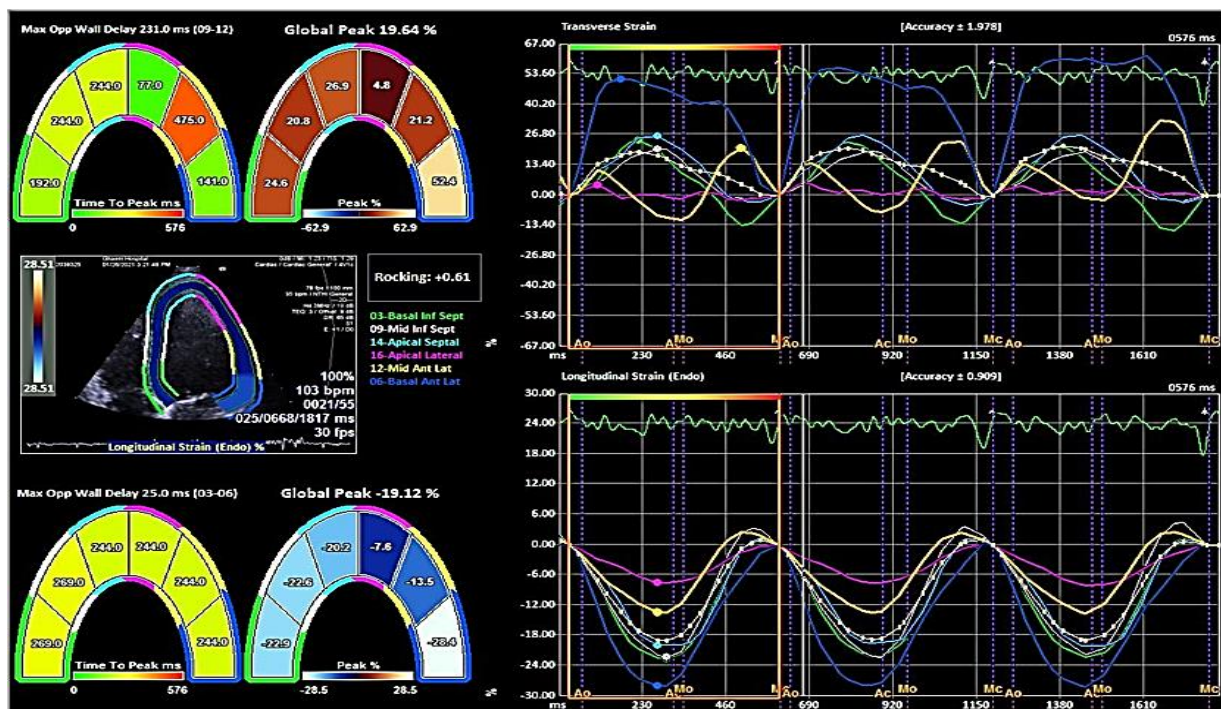


Figure 2. Strain analysis of left ventricle (LV) for calculating left ventricular global longitudinal strain (LVGLS)

Statistics: Statistical analysis was done using SPSS software (version 23.0, IBM Corporation, Armonk, NY, USA). Normality assumption was done by Kolmogorov-Smirnov test. Categorical variables were reported as frequency and percentage. Quantitative variables were described as the mean \pm standard deviation (SD). The chi-square test or Fisher's exact test was used for comparing the distribution pattern of categorical variables between two groups. For comparing quantitative variables of two groups, the independent samples t-test and Mann-Whitney test were used in normally and non-normally distributed variables, respectively. Linear regression was also applied to determine the effect of PVC on echocardiographic parameters. P-value < 0.05 was considered statistically significant.

Results

There was no statistically significant difference between the two groups concerning sex, hypertension (HTN), diabetes, and smoking. There were 15 women (57.7%) in the PVC group and 17 women (65.4%) in the control group ($P = 0.57$). Two patients in the PVC group and three patients in the control group were hypertensive ($P > 0.99$).

There was only one patient with diabetes in PVC and control group ($P > 0.99$). There were two smokers in the PVC group, whereas there was no smoker in the control group ($P = 0.49$).

The mean age of the PVC group was 43.46 ± 15.93 years, and the mean age in the control group was 44.46 ± 10.37 years ($P = 0.790$). Table 1 summarizes the echocardiographic parameters in both groups.

In comparison between two groups, patients with frequent PVCs had significantly larger LVEDVI (52.19 ± 9.60 vs. 46.95 ± 9.04 , $P = 0.048$) along with lower LVEF (57.58 ± 5.11 vs. 60.81 ± 3.58 , $P = 0.011$), lower (more positive) LVGLS (-18.25 ± 2.05 vs. -20.53 ± 1.60 , $P < 0.001$), and lower peak systolic mitral annular velocity (S') (7.11 ± 0.84 vs. 7.61 ± 0.89 , $P = 0.045$).

LAVI was found to be significantly larger in the PVC group (28.26 ± 6.86 vs. 22.86 ± 3.55 , $P = 0.01$). In VVI echocardiography analysis, PALS (30.85 ± 13.15 vs. 57.49 ± 9.13 , $P < 0.001$) and PACS (14.17 ± 5.98 vs. 21.99 ± 6.79 , $P < 0.001$) were significantly lower and TPLS (438.80 ± 77.31 vs. 380.80 ± 41.00 , $P = 0.002$) was significantly higher in PVC group.

Table 1. Echocardiographic parameters of the study population

	PVC group (n = 26)	Control group (n = 26)	P
LVEDVI (ml/m ²)	52.19 ± 9.60	46.95 ± 9.04	0.048*
IVS (cm) [§]	0.72 (0.70-0.86)	0.80 (0.70-0.80)	0.939**
PW (cm) [§]	0.72 (0.70-0.86)	0.80 (0.70-0.80)	0.939**
LVEF (%)	57.58 ± 5.11	60.81 ± 3.58	0.011*
Mitral E (cm/s)	76.15 ± 21.66	74.62 ± 14.81	0.766*
Mitral A (cm/s)	66.88 ± 16.89	67.81 ± 17.72	0.848*
DT (msec)	211.12 ± 56.52	191.42 ± 38.49	0.148*
S mitral (cm/s)	7.11 ± 0.84	7.61 ± 0.89	0.045*
Medial e' (cm/s)	8.82 ± 2.48	9.55 ± 1.93	0.245*
Medial a' (cm/s)	9.00 ± 1.98	8.86 ± 2.50	0.826*
Lateral e' (cm/s)	12.35 ± 2.97	12.76 ± 2.72	0.602*
Lateral a' (cm/s)	11.17 ± 2.77	11.03 ± 2.40	0.848*
E/e' medial	8.73 ± 3.42	7.91 ± 1.91	0.292*
PALS (%)	30.85 ± 13.15	57.49 ± 9.13	< 0.001 *
TPLS (msec) [§]	424.50 (383.75-451.70)	391.50 (352.25-414.00)	0.002**
PACS (%)	14.17 ± 5.98	21.99 ± 6.79	< 0.001 *
LVGLS (%)	-18.25 ± 2.05	-20.53 ± 1.60	< 0.001 *
LAVI (ml/m ²)	28.26 ± 6.86	22.86 ± 3.55	0.010*

Echocardiographic parameters are expressed as mean \pm standard deviation (SD). A P-value < 0.05 was defined as significant.

*Independent samples t-test; **Mann-Whitney test; §Median and interquartile range (IQR) were used due to the non-normal distribution

LVEDVI: Left ventricular end-diastolic volume index; IVS: Interventricular septum; PW: Posterior wall; LVEF: Left ventricular ejection fraction; DT: Deceleration time; E: Early diastolic mitral inflow velocity; A: Late diastolic mitral inflow velocity; e': Early diastolic mitral annulus velocity; a': Late diastolic mitral annulus velocity; PALS: Peak atrial longitudinal strain; TPLS: Time to peak longitudinal strain; PACS: Peak atrial contraction strain; LVGLS: Left ventricular global longitudinal strain; LAVI: Left atrial volume index; PVC: Premature ventricular contraction

Linear regression test showed that in people with PVC (compared to people without PVC), PALS was 26.6 units lower [confidence interval (CI): -32.9, -20.3]. The absolute value of LVGLS in those who had PVC was 2.2 units less than those who did not have PVC (CI: -3.3, -1.2).

Discussion

In the present study, we used conventional echocardiography along with VVI analysis. VVI is a new echocardiographic modality which combines speckle tracking and endocardial border detection. Like 2D STE strain imaging, VVI is angle-independent but has simpler and faster tracking and processing times than conventional STE.^{12,17} It requires only a single frame tracing of the endocardial border to extract quantitative time-motion and volume data.¹⁴

we demonstrated that LVEF, LVGLS, and S' were significantly lower in the PVC group. LVEDVI and LAVI were found to be significantly higher in the PVC group. In VVI echocardiography parameters, PALS and PACS were significantly lower, and TPLS was significantly longer in the PVC group.

A similar result was seen in Park et al. study, which demonstrated that patients with frequent PVCs had significantly larger LAVI associated with larger LV end-diastolic dimension, lower LVEF, and lower S'. They showed that atrial remodeling happened before LV geometry change and LV systolic dysfunction.⁵ However, they did not evaluate the LA or LV strain, which can diagnose the subtle changes in LA or LV function. Kostis et al. showed that the number of PVCs recorded in 24 hours increased significantly with increasing age (P = 0.001).¹⁸

Lie et al. found a moderate, significant correlation between the number of PVCs and reduced GLS (R = 0.44, P = 0.002). They declared that PVC > 8% in 24 hours could identify patients with abnormal GLS [area under curve (AUC): 0.79].¹⁹ This study emphasizes the importance of treating a small number of PVCs.

Cozma et al. evaluated the association between frequent PVCs and LA geometry. They demonstrated that frequent PVCs in otherwise healthy patients were associated with LA remodeling, larger LA volume, and trapezoidal LA.⁶ The result of the mentioned study is similar to our study that frequent PVCs could change the LA geometry.

Barutcu et al. investigated the effects of PVCs on LA function by using STE with LA strain

parameters and demonstrated that global PALS (38.39 ± 7.93 vs. 44.15 ± 6.71 , P = 0.001) and PACS (16.37 ± 4.58 vs. 20.49 ± 3.65 , P < 0.001) were significantly lower and TPLS (485.5 vs. 435.0, P < 0.001) was significantly longer in the PVC group.² The result of this study is compatible with ours, but we also evaluated LV function.

Azemi et al. reported that reduced LA strain in patients with low-risk AF was a sensitive marker for increased transient ischemic attack (TIA) and stroke risk and could be used as a helping guide for or against anticoagulation in this group.²⁰

Hirose et al. demonstrated that reduced LA function, using STE, independently predicts the risk of new-onset AF, suggesting a stronger relation between LA functional remodeling and AF than between LA size and AF.¹⁶

Echocardiography with strain analysis can show the changes in the structure and function of both LA and LV before the patient becomes symptomatic. Recent studies have emphasized the treatment of even small numbers and asymptomatic PVCs.¹⁹ Therefore, the structural or functional change of LA and LV, demonstrated by strain analysis, could be a key to the timely treatment of PVC.

It has been suggested that in patients with frequent PVCs, long-term observation is applied for evaluating LV function.²¹ Frequent PVCs may lead to a form of cardiomyopathy that can be reversed by PVCs' ablation.²²⁻²⁴ Chen et al. suggested that PVC treatment might prevent LA dilation and LVEF decline.²⁵

Conclusion

In this study, LA and LV function and geometry are adversely affected by frequent PVCs. Early diagnosis of these effects is possible with echocardiography along with strain analysis. It can guide the timely treatment of PVC to avoid frequent PVCs' harmful effects on the heart.

Limitations: The small number of patients in our study due to tight inclusion criteria was a significant limitation. Regarding the lack of follow-up of patients, the prognostic value of echocardiographic parameters in patients with recurrent PVC is uncertain.

Acknowledgments

The authors would like to thank all the subjects participating in the current study. This study was supported by Mashhad University of Medical Sciences, Mashhad.

Conflict of Interests

Authors have no conflict of interests.

Authors' Contribution

All authors contributed to this project and article equally. All authors read and approved the final manuscript.

References

- Ahn MS. Current concepts of premature ventricular contractions. *J Lifestyle Med* 2013; 3(1): 26-33.
- Barutcu A, Gazi E, Temiz A, Bekler A, Altun B, Kirilmaz B, et al. Assessment of left-atrial strain parameters in patients with frequent ventricular ectopic beats without structural heart disease. *Int J Cardiovasc Imaging* 2014; 30(6): 1027-36.
- Oomen AWGJ, Dekker LRC, Meijer A. Catheter ablation of symptomatic idiopathic ventricular arrhythmias: A five-year single-centre experience. *Neth Heart J* 2018; 26(4): 210-6.
- Zipes DP, Camm AJ, Borggrefe M, Buxton AE, Chaitman B, Fromer M, et al. ACC/AHA/ESC 2006 guidelines for management of patients with ventricular arrhythmias and the prevention of sudden cardiac death: a report of the American College of Cardiology/American Heart Association Task Force and the European Society of Cardiology Committee for Practice Guidelines (Writing Committee to Develop Guidelines for Management of Patients With Ventricular Arrhythmias and the Prevention of Sudden Cardiac Death). *J Am Coll Cardiol* 2006; 48(5): e247-e346.
- Park Y, Kim S, Shin J, Oh AR, Shin EJ, Lee JH, et al. Frequent premature ventricular complex is associated with left atrial enlargement in patients with normal left ventricular ejection fraction. *Pacing Clin Electrophysiol* 2014; 37(11): 1455-61.
- Cozma D, Streian CG, Petrescu L, Mornos C. Subclinical left atrium remodelling in patients with frequent premature ventricular contractions. *Kardiol Pol* 2014; 72(11): 1141-7.
- Sen J, Amerena J. Premature ventricular contraction-induced dilated cardiomyopathy: a case report. *Eur Heart J Case Rep* 2019; 3(1): ytz016.
- Lang RM, Badano LP, Mor-Avi V, Afilalo J, Armstrong A, Ernande L, et al. Recommendations for cardiac chamber quantification by echocardiography in adults: an update from the American Society of Echocardiography and the European Association of Cardiovascular Imaging. *J Am Soc Echocardiogr* 2015; 28(1): 1-39.
- Nagueh SF, Smiseth OA, Appleton CP, Byrd BF 3rd, Dokainish H, Edvardsen T, et al. Recommendations for the evaluation of left ventricular diastolic function by echocardiography: An update from the American Society of Echocardiography and the European Association of Cardiovascular Imaging. *J Am Soc Echocardiogr* 2016; 29(4): 277-314.
- Quinones MA, Otto CM, Stoddard M, Waggoner A, Zoghbi WA. Recommendations for quantification of Doppler echocardiography: A report from the Doppler Quantification Task Force of the Nomenclature and Standards Committee of the American Society of Echocardiography. *J Am Soc Echocardiogr* 2002; 15(2): 167-84.
- Bigdelu L, Poorzand H, Azari A, Jarahi L, Ghaderi F, Fazlinejad A, et al. Mitral leaflet separation to evaluate the severity of mitral stenosis: Validation of the index by transesophageal three-dimensional echocardiography. *Echocardiography* 2018; 35(3): 361-7.
- Gan GCH, Ferkh A, Boyd A, Thomas L. Left atrial function: Evaluation by strain analysis. *Cardiovasc Diagn Ther* 2018; 8(1): 29-46.
- Cameli M, Lisi M, Righini FM, Mondillo S. Novel echocardiographic techniques to assess left atrial size, anatomy and function. *Cardiovasc Ultrasound* 2012; 10: 4.
- Valocik G, Druzbacka L, Valocikova I, Mitro P. Velocity vector imaging to quantify left atrial function. *Int J Cardiovasc Imaging* 2010; 26(6): 641-9.
- Moaref A, Faraji M, Tahamtan M. Subclinical left ventricular systolic dysfunction in patients with metabolic syndrome: A case-control study using two-dimensional speckle tracking echocardiography. *ARYA Atheroscler* 2016; 12(6): 254-8.
- Hirose T, Kawasaki M, Tanaka R, Ono K, Watanabe T, Iwama M, et al. Left atrial function assessed by speckle tracking echocardiography as a predictor of new-onset non-valvular atrial fibrillation: Results from a prospective study in 580 adults. *Eur Heart J Cardiovasc Imaging* 2012; 13(3): 243-50.
- Vakilian F, Tavallaie A, Alimi H, Poorzand H, Salehi M. Right atrial strain in the assessment of right heart mechanics in patients with heart failure with reduced ejection fraction. *J Cardiovasc Imaging* 2021; 29(2): 135-43.
- Kostis JB, McCrone K, Moreyra AE, Gotzoyannis S, Aglitz NM, Natarajan N, et al. Premature ventricular complexes in the absence of identifiable heart disease. *Circulation* 1981; 63(6): 1351-6.
- Lie OH, Saberniak J, Dejgaard LA, Stokke MK, Hegbom F, Anfinsen OG, et al. Lower than expected burden of premature ventricular contractions impairs myocardial function. *ESC Heart Fail* 2017; 4(4): 585-94.
- Azemi T, Rabdiya VM, Ayirala SR, McCullough LD, Silverman DI. Left atrial strain is reduced in patients with atrial fibrillation, stroke or TIA, and low risk CHADS(2) scores. *J Am Soc Echocardiogr*

- 2012; 25(12): 1327-32.
21. Niwano S, Wakisaka Y, Niwano H, Fukaya H, Kurokawa S, Kiryu M, et al. Prognostic significance of frequent premature ventricular contractions originating from the ventricular outflow tract in patients with normal left ventricular function. *Heart* 2009; 95(15): 1230-7.
 22. Bogun F, Crawford T, Reich S, Koelling TM, Armstrong W, Good E, et al. Radiofrequency ablation of frequent, idiopathic premature ventricular complexes: comparison with a control group without intervention. *Heart Rhythm* 2007; 4(7): 863-7.
 23. Takemoto M, Yoshimura H, Ohba Y, Matsumoto Y, Yamamoto U, Mohri M, et al. Radiofrequency catheter ablation of premature ventricular complexes from right ventricular outflow tract improves left ventricular dilation and clinical status in patients without structural heart disease. *J Am Coll Cardiol* 2005; 45(8): 1259-65.
 24. Yarlagadda RK, Iwai S, Stein KM, Markowitz SM, Shah BK, Cheung JW, et al. Reversal of cardiomyopathy in patients with repetitive monomorphic ventricular ectopy originating from the right ventricular outflow tract. *Circulation* 2005; 112(8): 1092-7.
 25. Chen YS, Chen WD, Chen YH, Akhmerov A, Wang HC, Chang KC, et al. Atrial and ventricular response to treatment of premature ventricular complexes. *Acta Cardiol Sin* 2020; 36(5): 475-82.