

## Dabigatran, a direct thrombin inhibitor, can be a life-saving treatment in heparin-induced thrombocytopenia

Ahmad Mirdamadi<sup>(1)</sup>

### Case Report

#### Abstract

**BACKGROUND:** Several studies have emphasized thrombosis associated with thrombocytopenia as a potentially fatal complication of heparin. A number of agents are used for this condition. As a new oral, reversible direct thrombin inhibitor, dabigatran has been approved for short-term thromboprophylaxis after elective hip and knee replacement surgery. We present a case of dabigatran administration in a patient with femoral fracture.

**CASE REPORT:** A 67-year-old woman referred to the orthopedic ward of Shariati Hospital (Isfahan, Iran) due to femoral fracture following an accident. Immediately after surgery, she was found to be suffering from deep vein thrombosis (DVT) in her lower extremity despite sufficient prophylaxis by enoxaparin. Laboratory data showed severe thrombocytopenia. Considering the clinical history, an initial diagnosis of heparin-induced thrombocytopenia was made. Doppler ultrasound confirmed the diagnosis. Heparin was thus replaced with dabigatran which increased platelet count to the normal range and improved DVT.

**CONCLUSION:** Dabigatran can be a life-saving treatment in heparin-induced thrombocytopenia. However, it is contraindicated in patients with renal dysfunction since it may cause potentially catastrophic results.

**Keywords:** Heparin Induced Thrombocytopenia, Heparin, Enoxaparin, Dabigatran

*Date of submission:* 20 May 2012, *Date of acceptance:* 5 Aug 2012

#### Introduction

Thrombosis associated with thrombocytopenia has been emphasized in several studies as a potentially fatal complication of heparin. After searching PubMed, Sid and Elsevier, we found 7 case reports that described several types of heparin-induced thrombocytopenia (HIT) treatment. The use of lepirudin infusion,<sup>1,2</sup> argatroban,<sup>3,4</sup> danaparoid,<sup>5</sup> plasma exchange,<sup>6</sup> and streptokinase<sup>7</sup> has been indicated. Oral thrombin inhibitors are new agents for prevention and treatment of HIT. Melagatran, an oral thrombin inhibitor, is no longer available due to its hepatic toxicity. While several other thrombin inhibitors such as lepirudin and desirudin are used via parenteral administration, bivalirudin and argatroban are less convenient for patients and health care providers.<sup>8</sup> As a new oral, reversible direct thrombin inhibitor, dabigatran has been approved for short-term thromboprophylaxis after elective hip and knee replacement surgery.<sup>9</sup> This paper presents a case of dabigatran administration in a patient with femoral fracture.

#### Case report

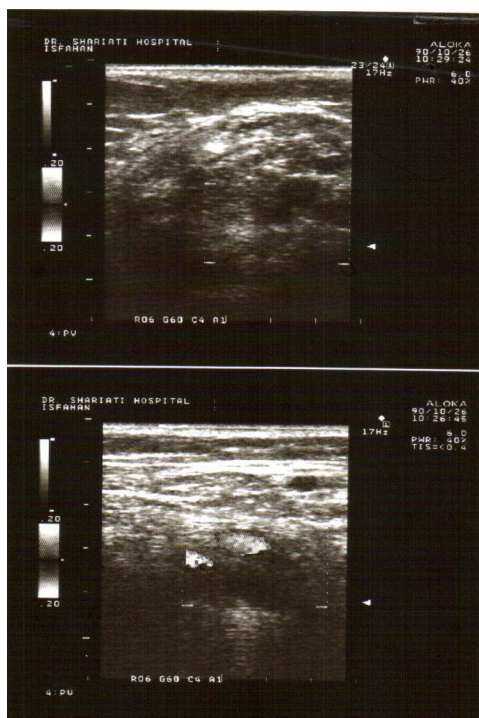
A 67-year-old woman with left femoral fracture ward of Shariati Hospital (Isfahan, Iran). She received sufficient thromboprophylaxis with enoxaparin for 6 days and then underwent orthopedic surgery.

Five days after surgery, the patient experienced swelling, pain, and tenderness in her left thigh and leg. Doppler sonography was ordered to confirm the suspected deep vein thrombosis (DVT). Dilation of the left common femoral, superficial femoral, popliteal, and posterior tibial veins was detected without any blood flow in them and with no compressibility as well. In the other hand some echogenic mass presented in those veins (Figure 1). DVT in the left lower limb was thus confirmed. Baseline platelet count was 173,000/ $\mu$ L but dropped to 32,000/ $\mu$ L two weeks after the initiation of enoxaparin (Figure 2).

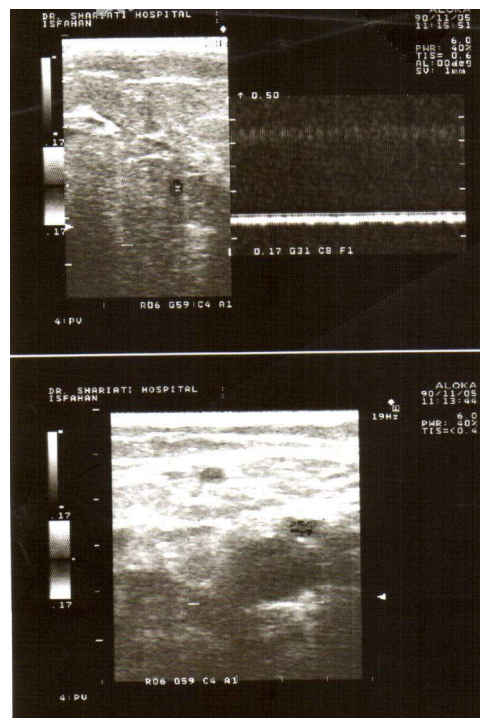
Based on clinical history and laboratory findings, the diagnosis of thrombosis associated with HIT was made. Enoxaparin was therefore discontinued

1- Assistant Professor, Department of Cardiology, School of Medicine, Najafabad Branch, Islamic Azad University, Isfahan, Iran  
Correspondence to: Ahmad Mirdamadi, Email: drsamirdamadi@yahoo.com

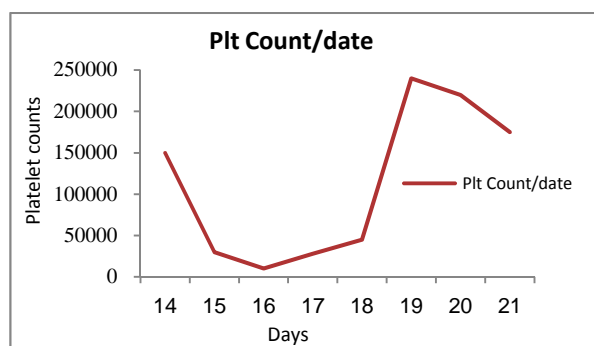
immediately and oral dabigatran was administered (110 mg twice a day). A few days later, platelet count increased to the normal range (236,000/ $\mu$ L) and the patient declared improvement in symptoms (Figure 2). On the tenth day of treatment with dabigatran, Doppler ultrasound was repeated which indicated the recanalization of the thrombosis (Figure 3).



**Figure 1.** Ultrasound before dabigatran administration (1/15/2012)



**Figure 3.** Ultrasound ten days after initiation of dabigatran (1/25/2012)



**Figure 2.** Platelet (Plt) counts before and after treatment with dabigatran

## Discussion

HIT with thrombosis, or the "white clot syndrome", is a rare but well recognized fatal complication of heparin therapy. The syndrome is idiosyncratic, immune-mediated, and not dose-dependent. It is therefore equally likely to occur with prophylactic and therapeutic heparin dosage regimens. HIT with

thrombosis is associated with significant incidence of morbidity and mortality. The frequency of HIT in orthopedic patients is about 0.5% for low molecular weight heparin (LMWH) and 3% for unfractionated heparin (UFH).<sup>9</sup> Prompt recognition of this complication and immediate withdrawal of heparin therapy are imperative.

Since HIT and thrombosis are mainly clinical diagnoses, one should not wait for objective test confirmation before stopping heparin treatment. On the other hand, LMWH should not be used to treat HIT because most HIT antibodies exhibit cross-reactivity with LMWH.<sup>10</sup> In addition, due to the consumption of protein C in this condition, administration of warfarin can trigger skin necrosis.<sup>11</sup>

The agents most frequently used in such conditions are parenteral direct thrombin-inhibitors such as lepirudin, argatroban, and bivalirudin, or factor Xa inhibitors such as fondaparinux.<sup>10</sup> However, we used dabigatran which is an oral direct thrombin inhibitor. It has been approved in the USA for prevention of stroke in patients with atrial fibrillation and is licensed in Europe and Canada for short-term thromboprophylaxis after elective hip and knee replacement surgery. Moreover, it has limited drug interactions, does not require monitoring, and has rapid peak blood level. Therefore, administration of dabigatran can be

helpful in the prevention and treatment of HIT. Nevertheless, dabigatran is contraindicated in patients with renal dysfunction since it may cause potentially catastrophic results. In this case, dabigatran was administered with no complications.

### Conclusion

All physicians who use heparin in the course of their practice need to be aware of life threatening HIT and the spectrum of its clinical presentations and management. In case of HIT, replacing UFH or LMWH with dabigatran is one of the life-saving strategies. Dabigatran is more convenient for patients and health care providers and has the potential to improve clinical outcomes. Although the use of dabigatran may result in major changes in thrombosis management and prevention, drug contraindications should not be forgotten.

### Conflict of Interests

Authors have no conflict of interests.

### References

1. Sunmez S, Okumus G, Kiyani E, Ece T, Arseven O. A case of heparin induced thrombocytopenia treated with lepirudin infusion: case report. *Tuberk Toraks* 2006; 54(2): 185-8.
2. Nippert M, De ME, Rodermann M, Vancon AC, Amrein D, Brembilla-Perrot B, et al. Treatment with lepirudin in heparin-induced thrombocytopenia. A case report. *Arch Mal Coeur Vaiss* 2002; 95(12): 1234-8.
3. Edwards JT, Hamby JK, Worrall NK. Successful use of Argatroban as a heparin substitute during cardiopulmonary bypass: heparin-induced thrombocytopenia in a high-risk cardiac surgical patient. *Ann Thorac Surg* 2003; 75(5): 1622-4.
4. Beiderlinden M, Treschan T, Gorlinger K, Peters J. Argatroban in extracorporeal membrane oxygenation. *Artif Organs* 2007; 31(6): 461-5.
5. Plassat R, Cognet F, Ternisien C, Menoret N, Dubus-Bausiere V, Brunel P, et al. Heparin induced thrombocytopenia: case report with acute thrombotic complications and literature review. *Ann Readapt Med Phys* 2002; 45(5): 216-23.
6. Poullin P, Pietri PA, Lefevre P. Heparin-induced thrombopenia: rapid regression of thrombopenia and thrombosis after plasma exchange. Case report. *Rev Med Interne* 1998; 19(11): 819-22.
7. Mehta DP, Yoder EL, Appel J, Bergsman KL. Heparin-induced thrombocytopenia and thrombosis: reversal with streptokinase. A case report and review of literature. *Am J Hematol* 1991; 36(4): 275-9.
8. Meddahi S, Samama MM. Direct inhibitors of thrombin, hirudin, bivalirudin, and dabigatran etexilate. *J Mal Vasc* 2011; 36(1): 24-32.
9. Picker SM, Gathof BS. Heparin induced thrombocytopenia. A frequently unrecognized complication after major orthopedic surgery. *Orthopade* 2004; 33(11): 1300-8.
10. Bonow RO, Mann DL, Zipes DP, Libby P. Braunwald's Heart Disease E-Book: A Textbook of Cardiovascular Medicine. Philadelphia, PA: Elsevier Health Sciences; 2011. p. 1859-60.
11. Srinivasan AF, Rice L, Bartholomew JR, Rangaswamy C, La PL, Thompson JE, et al. Warfarin-induced skin necrosis and venous limb gangrene in the setting of heparin-induced thrombocytopenia. *Arch Intern Med* 2004; 164(1): 66-70.

**How to cite this article:** Mirdamadi A. Dabigatran, a direct thrombin inhibitor, can be a life-saving treatment in heparin-induced thrombocytopenia. *ARYA Atheroscler* 2013; 9(1): 112-4.