

## Dill-normalized liver lipid accumulation, oxidative stress, and low-density lipoprotein receptor levels in high cholesterol fed hamsters

Ebrahim Abbasi-Oshaghi<sup>(1)</sup> , Iraj Khodadadi<sup>(2)</sup>, Heidar Tavilani<sup>(2)</sup>,  
Fatemeh Mirzaei<sup>(3)</sup>, Mohammad Taghi Goodarzi<sup>(4)</sup> 

### Original Article

#### Abstract

**BACKGROUND:** High lipid accumulation in hepatocyte and blood vessels can lead to non-alcoholic fatty liver disease (NAFLD) and heart diseases, respectively. These disorders are the main reasons of mortality in various countries. In this experiment, we evaluated the effect of leaf extracts of *Anethum graveolens* (AG), also known as Dill, and AG tablet on expression of low-density lipoprotein receptor (LDLR) and liver lipid in hypercholesterolemic hamsters.

**METHODS:** In this experimental study, 36 male golden hamsters were divided into 6 groups: 1) standard diet + 0.5% cholic acid + 2% cholesterol [high cholesterol diet (HCD)], 2) HCD + 100 mg/kg hydroalcoholic extract of Dill, 3) HCD + 200 mg/kg hydroalcoholic extract of Dill, 4) HCD + 100 mg/kg Dill tablet, 5) HCD + 200 mg/kg Dill tablet, 6) chow. At the end of study (30<sup>th</sup> day), hamsters were anesthetized and blood sample and liver tissue were collected. Biochemical factors and antioxidant parameters were determined. LDLR messenger ribonucleic acid (mRNA) level was measured using real time polymerase chain reaction (RT-PCR). Histopathological change of liver was determined using light microscope.

**RESULTS:** Compared to HCD group, blood lipids ( $P < 0.0010$ ) and liver enzymes ( $P < 0.0010$ ) markedly reduced in AG-treated groups. The expression of LDLR did not change significantly in animals which received low dose of hydroalcoholic extract or AG tablet, but it increased in animals receiving high dose of extract or tablet ( $P < 0.0100$ ). Liver antioxidant significantly increased by AG ( $P < 0.0010$ ). Liver histopathological changes were normalized by AG.

**CONCLUSION:** AG can significantly increase LDLR gene expression in HCD animals. This study showed that both AG extract and AG tablet had potential antioxidant and hypolipidemic effects in hamsters.

**Keywords:** *Anethum Graveolens*, Cholesterol, Hamsters, Herbal Medicine

*Date of submission:* 16 Dec. 2016, *Date of acceptance:* 29 July 2018

#### Introduction

In the recent years, heart diseases and alcoholic and non-alcoholic fatty liver disease (NAFLD) are known as the main causes of death in the world. In the recent decade, the prevalence of NAFLD strongly increased in various countries.<sup>1</sup> In these diseases, low antioxidant capacity and dyslipidemia criteria such as reduced amount of high-density lipoprotein cholesterol (HDL-C) and changes in low-density lipoprotein (LDL) particles can be observed. Many clinical trial studies have established a log-linear correlation between LDL-C levels and coronary artery disease (CAD) events. The recent evidence approves a plan of primary and potential

lowering of blood lipid levels as the primary target for prevention and treatment of CAD.<sup>2</sup> On the other hand, accumulation of lipids in the liver leads to NAFLD. This disorder is directly accompanied by obesity, dyslipidemia, and hypertension, proposing the significant role of liver in metabolic disorders.<sup>1</sup>

It has been well documented that elevated deposition of LDL-C into blood vessel walls initiate and develop atherosclerotic plaque. Clearance of blood LDL-C particles is chiefly mediated by liver LDL receptor (LDLR), a main regulator of cholesterol metabolism. LDLR has a vital role in hepatic uptake and clearance of plasma cholesterol,

1- Assistant Professor, Research Center for Molecular Medicine, Hamadan University of Medical Sciences, Hamadan, Iran

2- Professor, Department of Biochemistry, School of Medicine, Hamadan University of Medical Sciences, Hamadan, Iran

3- Fertility and Infertility Research Center, Kermanshah University of Medical Sciences, Kermanshah, Iran

4- Professor, Department of Biochemistry, Shahrood Branch, Islamic Azad University, Shahrood, Iran

Correspondence to: Mohammad Taghi Goodarzi, Email: [mtgoodarzi@yahoo.com](mailto:mtgoodarzi@yahoo.com)

and liver expresses about 80% of all LDLRs in the body.<sup>2</sup> With abnormal LDLR function or structure, plasma LDL-C level rises that can increase atherosclerosis risk.<sup>1</sup> Mutations in this gene, causing declined LDLR activity, are the chief reason for familial hypercholesterolemia (FH).<sup>2</sup> Hence, normalizing blood LDL-C levels via increase of LDLR expression by chemical drugs or herbal medicine may offer therapeutic advantages.<sup>1</sup>

Statins are used as the useful medications that inhibit cholesterol biosynthesis by suppression of 3-hydroxy-3-methylglutaryl-coenzyme A (HMG-CoA) reductase. However, statins have some adverse effects such as myopathy, myalgia, rhabdomyolysis, and myotoxicity.<sup>3</sup> In this respect, herbal medicine is suggested for management and treatment of many disorders, especially diabetes and dyslipidemia.<sup>4,6</sup>

Anethum graveolens L. (AG) is an annual plant which has been known to show hypolipidemic effects, and grows in Mediterranean region, Europe, and Asia.<sup>7</sup> In traditional medicine, AG has been applied for the handling of gastrointestinal disorder and used as an antifungal, antibacterial, antisecretory, and antispasmodic agent.<sup>7</sup> In the recent decade, the hypoglycemic properties of AG are approved by different studies.<sup>8-10</sup> Since AG has shown potential cholesterol lowering effects, it is prescribed for dyslipidemia in Iran as Anethum tablet. It contains AG (68%), Citrus aurantifolia (4%), Cichorium intybus (5%), and Fumaria parviflora (5%).<sup>11</sup> Although the hypolipidemic effect of AG has been revealed in different experiments, its mechanism remained unknown. On the other hand, the hepatoprotective effects of Dill during high-fat/high-cholesterol fed is not understood. Hence, the main purpose of this experiment was to evaluate the influence of Dill on the liver lipid accumulation and LDLR levels in hypercholesterolemic animals.

### Materials and Methods

Fresh Dill was collected and identified by our colleague in the Department of Biology (School of Sciences, Bu-Ali Sina University, Hamadan, Iran), then dried at shadow, and coarsely powdered. A 100 g of dried powder was defatted with 500 ml water and ethanol (1:1) and incubated at room temperature for 72 hours. The obtained solution was filtered 3 times through Whatman (No.2) filter paper and evaporated under the vacuum at 40 °C (yield: 23%). Sample was stored in dark vials at -20 °C until use.<sup>12</sup> Anethum tablet was prepared from Iran Darouk Company, Tehran, Iran.

Male Syrian hamsters ( $130 \pm 10$  g) were obtained from Hamadan University of Medical Sciences, Hamadan City. They were maintained at standard situations with temperature at  $24 \pm 1$  °C, and 12-hour dark/light cycles were used throughout the study. After one week of adaptation, animals were divided into 6 groups of 6 hamsters and treated as follows: 1) standard diet + 2% cholesterol + 0.5% cholic acid [high-cholesterol diet (HCD)], 2) HCD + 100 mg/kg hydroalcoholic extract of Dill, 3) HCD + 200 mg/kg hydroalcoholic extract of Dill, 4) HCD + 100 mg/kg Dill tablet, 5) HCD + 200 mg/kg Dill tablet, 6) chow. Dill doses were selected based on previous reports.<sup>13</sup> Various studies selected these doses of various experiments.<sup>14,15</sup> The Desai and Patel conducted an experiment to determine the acute oral toxicity in animal model, and the results revealed that prescription of Dill at the dose of 1, 2, 3 and 5 g/kg did not show any mortality and behavior changes after 24 hours. They also showed that acute administration of these doses for about 1 month did not show any mortality and behavior changes.<sup>16</sup>

After one month, hamsters were anesthetized with diethyl ether after overnight fasting and then sacrificed. Blood was prepared from the heart of animals and liver tissue was removed and rapidly frozen with liquid nitrogen. All samples ( $n = 6$ ) were blind for laboratory and pathologist. All the procedures of this experiment were permitted by Ethics Committee of Hamadan University of Medical Sciences. Exclusion criteria included old hamsters, unhealthy animals, and weighting more or less than  $130 \pm 10$  g.

Total cholesterol (TC) and triglycerides (TG) of liver were determined according to a modified method of a previous published paper.<sup>10</sup> The liver tissue was homogenized and supernatant was used for determination of biochemical factors. For total antioxidant assay, 10  $\mu$ l of butylated hydroxytoluene (BHT) (0.5 M in acetonitrile) was added to all samples to prevent oxidative reaction, and then total antioxidant capacity (TAC), superoxide dismutase (SOD), and malondialdehyde (MDA) were determined according to the formerly published paper.<sup>17,18</sup> Serum TAC, MDA, and SOD were also determined.

**Quantitative real time-polymerase chain reaction (QRT-PCR) assay:** Ribonucleic acid (RNA) was isolated from liver of each hamster ( $n = 6$ ) using TrIzol (Invitrogen) according to manufacturer's instruction. The concentration and purity of RNA was evaluated by NanoDrop spectrophotometer and its integrity was determined

by agarose gel electrophoresis. 1 µg of template was used for complementary deoxyribonucleic acid (cDNA) synthesis using QuantiTect Reverse Transcription Kit (Fermentas Life Sciences).<sup>19</sup> Determination of LDLR gene expression was done by RT-PCR. Primer was designed as follows: LDLR (F: 5'-CTC CAC TCT ATC TCC AGC ATT-3' and LDLR R: 5'-GAC AAG AGG TTT TCA GCCACC AAA -3') and glyceraldehyde-3-phosphate dehydrogenase (GAPDH) (F: 5'-TGGCCTTCCTTCCTACG-3' and R: 5'-TAGCCCAGGATGCCCTTCAG-3') as internal control.

For histological examination, a small portion of each animal's liver (n = 6) was removed and fixed with 10% formalin. Sections were cut and stained with hematoxylin-eosin (H&E) and were photographed by light microscopy. Analysis was done by a pathologist who did not know the former information about the different groups.

All results were presented as mean ± standard error of the mean (SEM). Comparisons between the groups were performed by one-way analysis of variance (ANOVA) followed by Tukey test using SPSS software (version 20, IBM Corporation, Armonk, NY, USA). The P-values < 0.05 were regarded statistically significant.

## Results

Liver's levels of TC and TG in HCD animals were higher compared with normal hamsters (P = 0.0005). Liver's TC amount markedly decreased in the animals treated by both doses of Anethum tablet (P = 0.0200 and P = 0.0080, respectively) and also in Anethum extract (200 mg/kg) receiving group (P = 0.0150) (Table 1).

Liver's levels of TG markedly decreased by Anethum tablet at both doses (P = 0.0340 and P = 0.0006, respectively) and Anethum extract at the dose of 200 mg/kg (P = 0.0060) (Table 1). The reduction of liver lipid was much more in 200 mg/kg Anethum tablet-treated animals in comparison to that of Anethum extract-receiving group (Table 1). Anethum extract and Anethum tablet markedly alleviated lipid profile and blood glucose in all treated groups compared with HCD animals (previously published data).

Serum total antioxidant levels of HCD animals were lower compared with normal hamsters (P = 0.0002). Hamsters treated by both doses of Anethum tablet and the 200 mg/kg Anethum

extract receiving group (P = 0.0066) revealed potential rise in TAC levels compared to HCD group (Table 1). Liver total antioxidant levels of HCD animals were also lower compared with normal hamsters (P = 0.0001). Anethum-treated animals at the doses of 100 and 200 mg/kg (P = 0.0029 and P < 0.0001, respectively) and Anethum extract receiving group at the dose of 100 and 200 mg/kg (P = 0.0160 and P = 0.0081, respectively) exhibited significant rise in total antioxidant levels compared to those of HCD animals (Table 1).

The serum level of MDA significantly increased in HCD group compared to that of normal animals (P < 0.0001). Furthermore, treatment of animals with Anethum tablet at doses of 100 and 200 mg/kg (P = 0.0023 and P < 0.0001, respectively) and Anethum extract at the dose of 200 mg/kg (P = 0.0015) led to a significant reduction in MDA level. In the liver, the change in MDA level had almost the same pattern. However, the reduction in MDA when treated with 200 mg/kg Anethum tablet was more significant (P = 0.0047) compared with other groups (Table 1).

The serum SOD activity was markedly reduced in HCD animals (P = 0.0017). SOD is well recognized as the primary defense against free radicals. Treatment with Anethum tablet at doses of 100 and 200 mg/kg (P = 0.0300 and P < 0.0001, respectively) and Anethum extract at the dose of 200 mg/kg (P = 0.0032) caused notable rise in SOD levels in comparison with untreated animals (Table 1).

The activity of SOD in the liver also decreased in HCD animals compared with healthy hamsters (P = 0.0350). Treatment with Anethum extract and tablet caused significant increase in SOD levels in comparison with control animals (P = 0.0380 and P = 0.0410, respectively) (Table 1).

Figure 1 shows the fold change of LDLR in the hepatocyte of animals. Anethum extract or Anethum tablet-treated animals (200 mg/kg) showed rise in LDLR gene markedly, as compared with HCD or normal animals (P < 0.0001 and P < 0.0001, respectively), whereas the change by 100 mg/kg was not significant.

The liver sections of normal groups showed usual histological form. The liver destructive changes were revealed in HCD hamsters. In these animals, normal concentric organization of hepatocytes was changed and sinusoids and portal vessels of liver were congested.

**Table 1.** Comparison of the oxidative stress markers in different-treated rats

Groups	Serum TAC (nmol/ml)	Liver TAC (nmol/mg pro)	Serum MDA (nmol/ml)	Liver MDA (nmol/mg pro)	Serum SOD (U/ml)	Liver SOD (U/ml)	Liver TG (mg/g)	Liver TC (mg/g)
Control	109.5 ± 4.5	85.5 ± 4.3	10.0 ± 2.0	3.0 ± 0.5	150.7 ± 6.5	157.5 ± 7.3	7.5 ± 1.2	6.8 ± 0.8
HCD	80.5 ± 4.0 <sup>£</sup>	58.0 ± 4.2 <sup>£</sup>	16.5 ± 1.5 <sup>£</sup>	7.0 ± 0.8 <sup>£</sup>	118.2 ± 6.3 <sup>£</sup>	131.3 ± 3.4 <sup>£</sup>	13.5 ± 0.8 <sup>£</sup>	12.0 ± 0.7 <sup>£</sup>
HCD + AE (100 mg/kg)	79.0 ± 2.0	67.0 ± 2.0 <sup>*</sup>	14.6 ± 2.8	6.8 ± 0.5	130.5 ± 4.5	155.4 ± 3.8 <sup>*</sup>	12.0 ± 2.0	12.2 ± 0.7
HCD + AT (100 mg/kg)	101.9 ± 4.5 <sup>**</sup>	81.8 ± 5.0 <sup>**</sup>	12.5 ± 1.4 <sup>**</sup>	5.0 ± 0.4 <sup>*</sup>	136.2 ± 3.7 <sup>*</sup>	152.3 ± 12.6	10.0 ± 1.3 <sup>*</sup>	9.5 ± 1.3 <sup>*</sup>
HCD + AE (100 mg/kg)	106.6 ± 3.5 <sup>**</sup>	82.2 ± 3.5 <sup>**</sup>	12.2 ± 1.0 <sup>**</sup>	5.5 ± 0.5 <sup>*</sup>	143.0 ± 4.2 <sup>**</sup>	153.0 ± 5.7 <sup>*</sup>	9.7 ± 0.7 <sup>**</sup>	9.0 ± 1.0 <sup>*</sup>
HCD + AT (100 mg/kg)	112.5 ± 4.4 <sup>***</sup>	91.0 ± 5.7 <sup>***</sup>	10.3 ± 1.4 <sup>***</sup>	5.0 ± 0.6 <sup>**</sup>	144.4 ± 5.8 <sup>***</sup>	155.4 ± 6.2 <sup>*</sup>	7.3 ± 0.6 <sup>***</sup>	7.0 ± 1.4 <sup>**</sup>

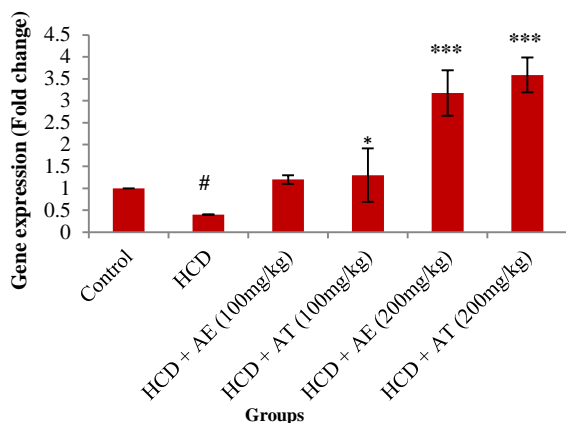
Data were expressed as mean ± standard error of the mean (SEM)

<sup>£</sup>P < 0.0010 compared with the normal control animals; <sup>\*</sup>P < 0.0500; <sup>\*\*</sup>P < 0.0100; <sup>\*\*\*</sup>P < 0.0010 compared with high cholesterol diet (HCD) group

AT: Anethum tablet; AE: Anethum extract; HCD: High cholesterol diet; TC: Total cholesterol; TG: Triglyceride, MDA: Malondialdehyde; TAC: Total antioxidant capacity; SOD: Superoxide dismutase



In HCD animals leukocyte infiltration, foam cell formation, and fat accumulation were observed. Treatment with Anethum tablet or its extract at the dose of 200 mg/kg markedly alleviated histological change of liver in high fat diet animals (Figure 2).



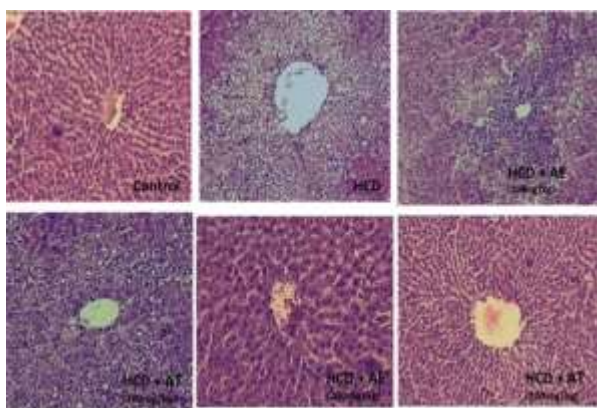
**Figure 1.** The fold change of low-density lipoprotein receptor (LDLR) in liver of different-treated rats

\*  $P < 0.0500$ ; \*\*\*  $P < 0.0010$  compared with high cholesterol diet (HCD) group; #  $P < 0.0010$  compared with the normal control animals.

HCD: High cholesterol diet; AT: Anethum tablet; AE: Anethum extract

## Discussion

Pervious experiments have reported that HCD leads to reactive oxygen species (ROS) generation in the liver, causing liver injury in human and animal models. Impairment of membrane by  $\text{OH}^-$  and peroxy nitrite ( $\text{ONOO}^-$ ) rises lipid peroxides which is able to react with redox metals to generate MDA, a main biomarker for oxidative stress assessment.<sup>20</sup>



**Figure 2.** Histological changes of liver of different groups. The liver of Anethum graveolens (AG) extract- and AG tablet- treated animals showed restoration (at the dose of 200 mg/kg was more significant,  $\times 400$ ).

HCD: High cholesterol diet; AT: Anethum tablet; AE: Anethum extract

Final product of lipid peroxidation such as MDA has been recognized as an atherogenic and toxic agent. Clinical experiments established that patients with high levels of MDA and low levels of total antioxidant have increased susceptibility to atherosclerosis, diabetes, and other metabolic disorders. Different studies showed that declining of MDA and increasing of antioxidant levels with different medicine therapy is probably an advantage in management of metabolic disorders.<sup>21</sup> In this study, total antioxidant in the liver significantly declined and MDA increased in hypercholesterolemic hamsters compared to normal group. Treatment of animals with AG tablet and AG extract normalized total antioxidant and MDA levels in hypercholesterolemic hamsters. We recently demonstrated the valuable properties of AG administration in improving dyslipidemia in animal models, proposing that it can be used as an alternative option for management of cardiovascular disease (CVD).<sup>22-24</sup> For instance, 8-week use of AG tablet revealed markedly a decline in circulating levels of TC and LDL-C in diabetic rats.<sup>11</sup> In addition, we showed that 4-week supplementation of AG tablet and AG extract reduced LDL-C levels and raised HDL-C levels in hypercholesterolemic hamsters.<sup>22</sup>

We reported that TC, TG, very-low-density lipoprotein cholesterol (VLDL-C) and LDL-C were markedly reduced by AG tablet and AG extract, whereas HDL-C level was elevated in the treated groups. Our findings are similar to the previous results reported by Yazdanpanah.<sup>25</sup>

Setorki et al.<sup>26</sup> and Souri et al.<sup>27</sup> established the lipid lowering properties of AG. Mobasseri et al.<sup>28</sup> also showed that supplementation of Anethum in diabetic patients restored insulin sensitivity and normalized blood lipid levels.

In the current experiments, AG increased the LDLR gene expression, lower value of delta cycle threshold ( $\Delta\text{Ct}$ ) means higher gene expression, and consequently modulated circulating cholesterol and LDL-C levels. High levels of LDLR are well established to decline serum LDL-C by increasing removal of circulating LDL-C. LDL-C clearance may suppress accumulation of cholesterol in the blood and result in a decline in the atherosclerosis risk. We showed that high cholesterol regimen decreased LDLR expression, which is probable because of the feedback mechanism motivated by high levels of cellular cholesterol in the hepatocyte. It has been reported that dietary cholesterol inhibits hepatic LDLR expression.<sup>29</sup> Our results indicated

that LDLR expression significantly increased by AG extract and AG tablet. The hamsters in HCD group treated by AG extract or AG tablet at the dose of 200 mg/kg exhibited increase in LDLR gene expression. However, supplementation of AG tablet showed more increase in the LDLR expression compared with other groups. The exact lipid lowering mechanism of AG is not completely understood; but previously, Souri *et al.*<sup>27</sup> reported that AG was able to change HMG-CoA/mevalonate ratio. We previously reported that AG could decrease HMG-CoA reductase in the animal models.<sup>22</sup> Also, the HMG-CoA reductase activity was reduced by AG extract and AG tablet at the dose of 200 mg/kg. The HMG-CoA reductase suppression causes reduction of liver cholesterol production and leads to low levels of VLDL-C secretion by the liver. Some studies showed that rutin and quercetin (main components of AG) reduced serum LDL-C, TC, and liver lipid accumulation.<sup>30</sup> It has been shown that quercetin inhibits HMG-CoA reductase activity.<sup>31</sup>

In this study, AG administration significantly reduced the liver TC and TG. Previously, we showed that AG contained flavonoid, phenolic, and tannin.<sup>11</sup> According to our previous report, the total phenolic and flavonoid compounds in AG extract were 160 and 120 mg/g and in AG tablet were 190 and 151 mg/g, respectively.<sup>22</sup> Many studies reported that these compounds had hypocholesterolemic, hypoglycemic, antioxidant as well as anti-atherogenesis and anti-thrombosis effects.<sup>32,33</sup> Reduction of TC and TG levels in hepatocyte by AG may result in inhibition of cholesterol biosynthesis and stimulation of cholesterol conversion to bile acids.

The histopathological findings revealed that AG regenerated liver structure in HCD hamsters. Regeneration effects by Anethum may enlighten the positive effects of this medicine on liver antioxidants and fat accumulation. This useful effect of AG only was observed at high doses.

### Conclusion

The findings of this experiment indicated that AG could be used in liver disease. Hypocholesterolemic activity of AG probably is through increasing LDLR gene expression in liver.

### Acknowledgments

We would like to thank Hamadan University of Medical Sciences (grant number: 9110193723) for financial support.

### Conflict of Interests

Authors have no conflict of interests.

### References

1. Corey KE, Chalasani N. Management of dyslipidemia as a cardiovascular risk factor in individuals with nonalcoholic fatty liver disease. *Clin Gastroenterol Hepatol* 2014; 12(7): 1077-84.
2. Nikkila K, Aberg F, Isoniemi H. Transmission of LDLR mutation from donor through liver transplantation resulting in hypercholesterolemia in the recipient. *Am J Transplant* 2014; 14(12): 2898-902.
3. Sinzinger H, Wolfram R, Peskar BA. Muscular side effects of statins. *J Cardiovasc Pharmacol* 2002; 40(2): 163-71.
4. Shahsavari G, Raoufi A, Toolabi A, Hosseninejadmir N, Ahmadvand H, Safaribrahimsarabie M. The effect of atorvastatin treatment duration on oxidative stress markers and lipid profile in patients with coronary artery diseases: A case series study. *ARYA Atheroscler* 2017; 13(6): 282-7.
5. Ahmadvand H, Ghasemi-Dehnoo M. Antiatherogenic, hepatoprotective, and hypolipidemic effects of coenzyme Q10 in alloxan-induced type 1 diabetic rats. *ARYA Atheroscler* 2014; 10(4): 192-8.
6. Mirzaei F, Khazaei M, Komaki A, Amiri I, Jalili C. Virgin coconut oil (VCO) by normalizing NLRP3 inflammasome showed potential neuroprotective effects in Amyloid-beta induced toxicity and high-fat diet fed rat. *Food Chem Toxicol* 2018; 118: 68-83.
7. Jana S, Shekhawat GS. Anethum graveolens: An Indian traditional medicinal herb and spice. *Pharmacogn Rev* 2010; 4(8): 179-84.
8. Goodarzi MT, Khodadadi I, Tavilani H, Abbasi Oshaghi E. The role of Anethum graveolens L. (Dill) in the Management of Diabetes. *J Trop Med* 2016; 2016: 1098916.
9. Al-Snafi AE. The pharmacological importance of Anethum graveolens: A review. *Int J Pharm Pharm Sci* 2014; 6(4): 11-3.
10. Abbasi Oshaghi E, Khodadadi I, Mirzaei F, Khazaei M, Tavilani H, Goodarzi MT. methanolic extract of dill leaves inhibits AGEs formation and shows potential hepatoprotective effects in CCl4 Induced liver toxicity in rat. *J Pharm (Cairo)* 2017; 2017: 6081374.
11. Abbasi Oshaghi E, Tavilani H, Khodadadi I, Goodarzi MT. Dill tablet: A potential antioxidant and anti-diabetic medicine. *Asian Pac J Trop Biomed* 2015; 5(9): 720-7.
12. Gholampour F, Behzadi Ghiasabadi F, Owji SM, Vatanparast J. The protective effect of hydroalcoholic extract of Ginger (Zingiber

- officinale Rosc.) against iron-induced functional and histological damages in rat liver and kidney. *Avicenna J Phytomed* 2017; 7(6): 542-53.
13. Arash A, Mohammad MZ, Jamal MS, Mohammad TA, Azam A. Effects of the aqueous extract of anethum graveolens leaves on seizure induced by pentylenetetrazole in mice. *Malays J Med Sci* 2013; 20(5): 23-30.
  14. Panda S. The effect of *Anethum graveolens* L. (dill) on corticosteroid induced diabetes mellitus: involvement of thyroid hormones. *Phytother Res* 2008; 22(12): 1695-7.
  15. Askari M, Hosseini S. Effect of hydroalcoholic extracts of *Anethum graveolens* L. with swimming training on lipid profile of diabetic rats. *Horizon Med Sci* 2016; 22(4): 345-51. [In Persian].
  16. Desai SN, Patel D. Acute and sub-chronic toxicological evaluation of *Anethum graveolens* L. seed extract. *J global Biosci* 2016; 5(6): 4213-20.
  17. Mohammadi A, Mirzaei F, Jamshidi M, Yari R, Pak S, Sorkhani A. The in vivo biochemical and oxidative changes by ethanol and opium consumption in syrian hamsters. *International Journal of Biology Archives* 2013; 5(4): 14.
  18. Mohammadi A, Abbasi Oshaghi E, Noori Sorkhani A, Oubari F, Hosseini Kia R, Rezaei A. Effect of opium on lipid profile and expression of liver x receptor alpha (LXRα) in Normolipidemic Mouse. *Food Nutr Sci* 2012; 3(2): 249-54.
  19. Mohammadi A, Vafaei SA, Nabi Moradi M, Ahmadi M, Pourjafar M, Abbasi Oshaghi E. Combination of ezetimibe and garlic reduces serum lipids and intestinal niemann-pick c1-like 1 expression more effectively in hypercholesterolemic mice. *Avicenna J Med Biochem* 2015; 3(1): e23205.
  20. Wouters K, van Gorp PJ, Bieghs V, Gijbels MJ, Duimel H, Lutjohann D, et al. Dietary cholesterol, rather than liver steatosis, leads to hepatic inflammation in hyperlipidemic mouse models of nonalcoholic steatohepatitis. *Hepatology* 2008; 48(2): 474-86.
  21. Balkan J, Dogru-Abbasoglu S, Aykac-Toker G, Uysal M. The effect of a high cholesterol diet on lipids and oxidative stress in plasma, liver and aorta of rabbits and rats. *Nutrition Research* 2004; 24(3): 229-34.
  22. Abbasi Oshaghi E, Khodadadi I, Saidijam M, Yadegarazari R, Shabab N, Tavilani H, et al. Lipid Lowering Effects of Hydroalcoholic Extract of *Anethum graveolens* L. and Dill Tablet in High Cholesterol Fed Hamsters. *Cholesterol* 2015; 2015: 958560.
  23. Abbasi Oshaghi E, Khodadadi I, Tavilani H, Goodarzi MT. Effect of dill tablet (*Anethum graveolens* L) on antioxidant status and biochemical factors on carbon tetrachloride-induced liver damage on rat. *Int J Appl Basic Med Res* 2016; 6(2): 111-4.
  24. Abbasi Oshaghi E, Khodadadi I, Tavilani H, Goodarzi MT. Aqueous extract of *Anethum Graveolens* L. has potential antioxidant and antiglycation effects. *Iran J Med Sci* 2016; 41(4): 328-33. [In Persian].
  25. Yazdanpanah K. Effects of dill juice on serum low density lipoprotein, triglyceride and high density lipoprotein in patients with hyperlipidemia. *Sci J Kurdistan Univ Med Sci* 2016; 5(3): 1-4. [In Persian].
  26. Setorki M, SHahinfar N, Ansari R, Forouzandeh Z., Asgharzadeh S, Rafieyan M. Comparison between the effects of hydroalcoholic extract of dill and statins on lipid profile. *J Kerman Univ Med Sci* 2013; 20(2): 158-68. [In Persian].
  27. Souri E, Amin G, Farsam H, Barazandeh Tehrani M. Screening of antioxidant activity and phenolic content of 24 medicinal plant extracts. *DARU* 2008; 16(2): 83-7.
  28. Mobasserri M, Ostadrahimi A, Khaje Bishak Y, Asghari Jafarabadi M, Mahluji S. *Anethum graveolens* supplementation improves insulin sensitivity and lipid abnormality in type 2 diabetic patients. *Pharm Sci* 2014; 20(2): 40-5.
  29. Berge KE, Tian H, Graf GA, Yu L, Grishin NV, Schultz J, et al. Accumulation of dietary cholesterol in sitosterolemia caused by mutations in adjacent ABC transporters. *Science* 2000; 290(5497): 1771-5.
  30. Arai Y, Watanabe S, Kimira M, Shimoi K, Mochizuki R, Kinae N. Dietary intakes of flavonols, flavones and isoflavones by Japanese women and the inverse correlation between quercetin intake and plasma LDL cholesterol concentration. *J Nutr* 2000; 130(9): 2243-50.
  31. Sung JH, Lee SJ, Park KH, Moon TW. Isoflavones inhibit 3-hydroxy-3-methylglutaryl coenzyme A reductase in vitro. *Biosci Biotechnol Biochem* 2004; 68(2): 428-32.
  32. Abbasi Oshaghi E, Goodarzi MT, Higgins V, Adeli K. Role of resveratrol in the management of insulin resistance and related conditions: Mechanism of action. *Crit Rev Clin Lab Sci* 2017; 54(4): 267-93.
  33. Knekt P, Kumpulainen J, Jarvinen R, Rissanen H, Heliovaara M, Reunanen A, et al. Flavonoid intake and risk of chronic diseases. *Am J Clin Nutr* 2002; 76(3): 560-8.

**How to cite this article:** Abbasi-Oshaghi E, Khodadadi I, Tavilani H, Mirzaei F, Goodarzi MT. **Dill-normalized liver lipid accumulation, oxidative stress, and low-density lipoprotein receptor levels in high cholesterol fed hamsters.** *ARYA Atheroscler* 2018; 14(5): 218-24.