



Unusual trifurcation of left main coronary artery in a patient with hypertrophic obstructive cardiomyopathy: Issues in management strategy

Santosh Sinha DM, FACC, FEESC, FSCAI⁽¹⁾ , Puneet Aggarwal DM⁽²⁾ ,
Sidhdarth Samrat DM⁽²⁾ , Mahmudullah Razi DM⁽²⁾ , Awadesh Sharma DM⁽²⁾ ,
Umeshwar Pandey DM⁽²⁾ 

Case Report

Abstract

BACKGROUND: Hypertrophic cardiomyopathy (HCM) and anomalous coronary artery arising from the opposite sinus are independently associated with increased risk of sudden cardiac death (SCD). Their coexistence in a single patient further complicates the issue by affecting management strategy and increasing the risk of sudden death.

CASE REPORT: A 21-year-old woman with hypertrophic obstructive cardiomyopathy (HOCM) having strong family history of SCD presented with exertional fatigue and palpitation. Cardiac catheterization and computed tomography (CT) coronary angiography revealed single left coronary artery where left main trunk was trifurcating into left anterior descending (LAD), left circumflex (LCX), and right coronary artery (RCA). The course of RCA was retro-aortic. There were no appreciable septal arteries to be ablated by alcohol injection. The patient was managed with implantable cardioverter-defibrillator (ICD) and metoprolol.

CONCLUSION: Single coronary artery (SCA) and HOCM are of great clinical significance as both of these conditions are independently associated with SCD. Medical management in form of beta blocker and ICD is an acceptable treatment strategy in appropriately selected symptomatic obstructive HCM. To the best of our knowledge, this is the first ever case report of RCA following a retro-aortic course arising from left main in a patient with obstructive HCM.

Keywords: Cardiomyopathy; Hypertrophic; Sudden cardiac death

Date of submission: 02 Feb 2020, *Date of acceptance:* 17 May. 2022

Introduction

Hypertrophic cardiomyopathy (HCM) is an inherited cardiomyopathy affecting approximately 1 in 500 adults and is one of the most common causes of sudden cardiac death (SCD) in young healthy individuals.¹ Malformation within coronary buds during fetal development leads to coronary artery anomalies. Incidence of anomalous right coronary artery (RCA) from left aortic sinus is 0.92% and by nature, is benign but at times, may have a malignant course because of intermittent ischemia and SCD.² Their coexistence in a single patient is extremely rare. There are multiple substrates accounting for ischemia in patients with HCM like impaired coronary flow reserve, disease of small intramuscular arteries, coronary vessel size mismatch to hypertrophied myocardium, impaired coronary flow during systole,

coexistent coronary artery disease (CAD), and rare coronary artery anomalies.³

Case Report

A 21-year-old woman presented for evaluation of exertional palpitation and fatigue for last 2 years of New York Heart Association (NYHA) functional class II. She also had experienced two episodes of syncope in past 2 months. She had a positive history of premature CAD in first-degree relatives which included her mother, maternal sister, and her sister.

How to cite this article: Sinha S, Aggarwal P, Samrat S, Razi M, Sharma A, Pandey U. **Unusual trifurcation of left main coronary artery in a patient with hypertrophic obstructive cardiomyopathy: Issues in management strategy.** ARYA Atheroscler 2022; 18: 2115.

1- Associate Professor, Department of Cardiology, LPS Institute of Cardiology, G.S.V.M. Medical College, Kanpur, Uttar Pradesh, India
2- Department of Cardiology, LPS Institute of Cardiology, Ganesh Shankar Vidyarthi Memorial Medical College, Kanpur, Uttar Pradesh, India

Address for correspondence: Santosh Sinha; Associate Professor, Department of Cardiology, LPS Institute of Cardiology, G.S.V.M. Medical College, Kanpur, Uttar Pradesh, India; Email: fionasan@rediffmail.com

On clinical examination, blood pressure was 112/84 mmHg in left arm in supine position. Pulse rate was 76/minute, regular, normal in volume, with bisferiens character, and no radio-radial or radio-femoral delay, and all pulses were equally palpable. On palpation, there was double apical impulse. On auscultation, S1 was normal, S2 was normal with delayed A2 component, and S4 was present. There was prolonged grade 3/6 ejection systolic murmur which was best heard in 2nd and 3rd left intercostal space which increased on standing and decreased on handgrip. Electrocardiogram (ECG) showed sinus rhythm, left anterior hemiblock, left atrial enlargement (LAE), T↓ in lead aVL, V₂₋₄, and Q waves in precordial leads V₂₋₅. Bisferiens character of pulse, increased intensity of murmur on standing, absence of delayed carotid upstroke, and radiation of murmur to carotids ruled out valvular type of left ventricular outflow tract obstruction (LVOTO) (aortic stenosis). Supravalvular aortic stenosis (SVAS) was ruled out by absence of any diastolic murmur, and any supra-aortic membrane on echocardiogram.

Chest X-ray [postero-anterior (PA) view] showed normal cardiac size. Her routine haemogram and biochemistry were within normal limits. Transrthoracic echocardiography (TTE) revealed asymmetric septal hypertrophy (interventricular septum: 2.3 cm, posterior wall: 1.1 cm) resulting in a peak instantaneous left ventricular outflow tract (LVOT) gradient of 64 mmHg and a mean gradient of 48 mmHg. Further, mild mitral regurgitation due to systolic anterior motion (SAM) of anterior mitral leaflet was noted. She had grade II diastolic dysfunction while her systolic function was normal [ejection fraction (EF): 58%]. Coronary angiography was performed after obtaining her informed consent through right transradial route, which revealed a single coronary artery (SCA) arising from left sinus of Valsalva (Figure 1). The left main coronary trunk was trifurcating into left anterior descending (LAD) artery, left circumflex (LCX), and RCA. LCX was dominant as it was giving rise to posterior descending artery (PDA) and posterolateral branch (PLB) (Figure 2). The coronary arteries were otherwise normal. On cardiac catheterisation, left ventricular end-diastolic pressure (LVEDP) was 18 mmHg and pullback gradient between left ventricle (LV) and sub-aortic outflow tract was 44 mmHg. Furthermore, no significant septal perforator was seen as there were multiple septal feeders which ruled out any option of transcatheter ablation of septal hypertrophy (TASH).

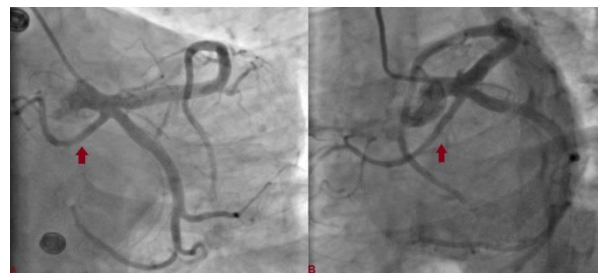


Figure 1. Left main coronary artery (LMCA) trifurcating into left anterior descending (LAD), left circumflex (LCX), and right coronary artery (RCA) (red arrow) (A: Antero-posterior (AP) caudal view; B: Left anterior oblique view with caudal angulation)

To better delineate anomalous origin and course of RCA, multidetector computed tomography (MDCT) coronary angiography was performed which revealed its retro-aortic course (Figures 3, 4).

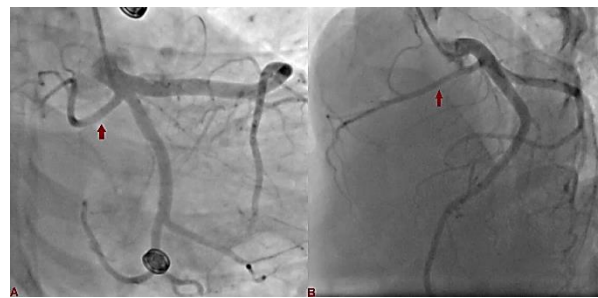


Figure 2. Trifurcation of left main coronary artery (LMCA) in right anterior oblique view with caudal angulation (A), and antero-posterior (AP) cranial view (B). Right coronary artery (RCA) is shown with red arrow.

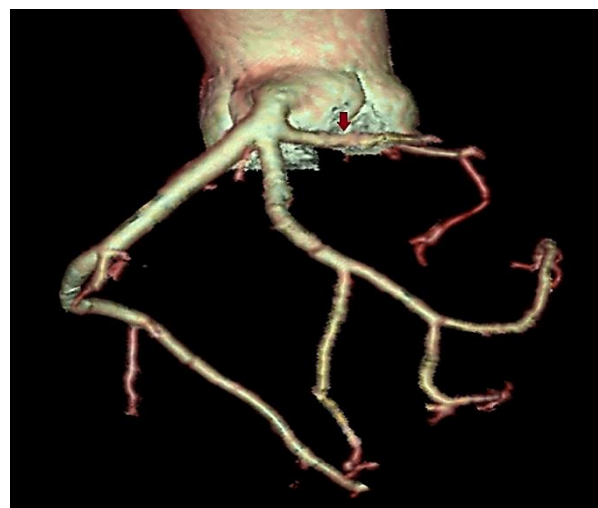

Figure 3. Multidetector computed tomography (MDCT) coronary angiography showing trifurcation of left main artery into left anterior descending (LAD), left circumflex (LCX), and right coronary artery (RCA) (red arrow: RCA)

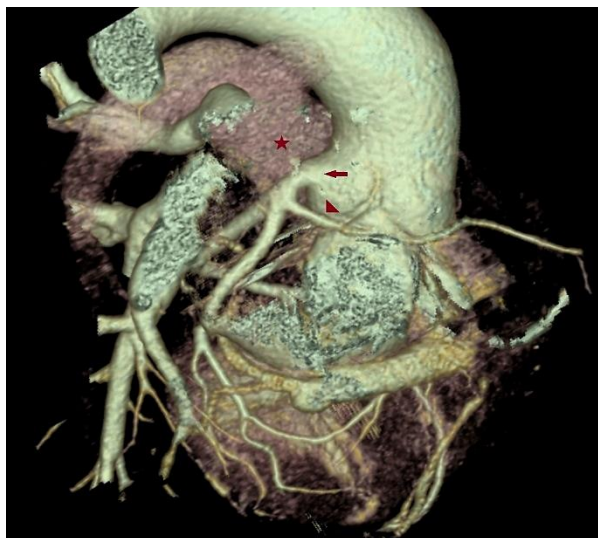

Figure 4. Multidetector computed tomography (MDCT) with volume rendered reconstruction (VR) showing trifurcation of left main artery into coronary angiography showing trifurcation of left main artery into left anterior descending (LAD), left circumflex (LCX), and right coronary artery (RCA) (red arrow: RCA; asterisk: Pulmonary trunk)

On holter monitoring, she had multiple runs of non-sustained ventricular tachycardia (NSVT). Based on family history, clinical presentation, and findings of ambulatory ECG, implantable cardioverter-defibrillator (ICD) (Boston Scientific, USA) was implanted. As she refused surgical myectomy, she was discharged in stable condition on metoprolol 100 mg twice daily with strict advice for restriction of strenuous physical activity. She was doing fine on follow-up.

Discussion

Coronary anomalies encompass heterogeneous group of diseases which include their morphology, anatomy in form of origin, course, and termination.⁴ Both HCM and coronary anomalies are the most common causes of SCA among the young athletes.⁵ Anomalous origin of RCA from left sinus of the Valsalva is a very rare coronary artery anomaly which has an incidence of 0.03%-0.9% in patients undergoing coronary angiography.⁶ Anomalous origin of coronary artery from contralateral sinus is usually considered to be benign, but at times, may have stormy outcome if it runs between two great arteries (interarterial course) because of repetitive ischaemia particularly in association with physical exertion. In a review by Taylor et al. among 242 patients with isolated coronary anomalies, an anomalous RCA from the left sinus of the Valsalva

was identified among 52 patients, of whom 13 patients had SCD.⁵ Repetitive ischemic substrate, mechanical compression, slit-like orifice, acute take-off angle, and vasospasm were the possible mechanisms.⁵

The association of hypertrophic obstructive cardiomyopathy (HOCM) with anomalous RCA is extremely rare and only few cases have been reported so far.^{7,8} This rare combination of two distinctly defined clinical entities further multiplies the risk of sudden death associated with physical exertion in young individuals. Echocardiography, magnetic resonance angiography (MRA), MDCT, and cardiac catheterization are diagnostic tools for evaluating anomalous coronary arteries. Catheter-based angiography fails to give information about angulations and slit-like ostia, and therefore, MRA and MDCT are considered the gold standards for its diagnosis. The optimal treatment for patients with anomalous coronary arteries arising from the contralateral sinus remains unclear, and therefore, requires individualized approach. Patients with symptomatic HOCM and coexistent anomalous RCA with interarterial course should undergo surgical correction in the form of coronary artery bypass, coronary re-implantation, and coronary unroofing for the relief of symptoms and prevention of untoward outcomes. Till now, there are only four case reports of patients of HOCM having single left coronary artery.⁷ Anomalous RCA was arising from left main trunk in one case where it had an interarterial course, while in remaining three cases, it was arising as an extension of distal LCX (two cases) and as extension of distal LAD (one case).⁷ Our case is the second where RCA was arising from left main trunk, and first one of RCA having retro-aortic course.⁷

Beta blockers or calcium channel blockers (verapamil) are the mainstay of medical therapy as they increase diastolic filling time by slowing the heart rate and ameliorate exercise-induced outflow tract gradients. For patients with obstructive HCM (resting gradient ≥ 50 mmHg) who are symptomatic despite optimal medical management, surgical myectomy is the gold standard, though TASH is another option. For patients deemed to be at increased risk of ventricular arrhythmias, ICD should be implanted to abort SCD. Our case highlights the need for an individualized approach to treatment of symptomatic obstructive HCM which further supports for medical management as an acceptable treatment strategy in appropriately selected cases.

Acknowledgments

None.

Conflict of Interests

Authors have no conflict of interests.

Authors' Contribution

SS, PA, and SS contributed to idea, study design, and evaluation. SS, PA, and MR participated in data collection. PA, SS, MR, and AS contributed to writing. AS, UP, and SS did the data analysis and statistical analysis. PA, UP, and AS contributed to editing and literature search.

References

1. Alqarqaz M, Zaidan M, Al-Mallah MH. Hypertrophic cardiomyopathy and anomalous left coronary artery: a rare combination. *J Cardiovasc Med (Hagerstown)* 2011; 12(12): 915-8.
2. Yamanaka O, Hobbs RE. Coronary artery anomalies in 126,595 patients undergoing coronary arteriography. *Cathet Cardiovasc Diagn* 1990; 21(1): 28-40.
3. Harjai KJ, Cheirif J, Murgu JP. Ischemia and atherosclerotic coronary artery disease in patients with hypertrophic cardiomyopathy: A review of incidence, pathophysiological mechanisms, clinical implications and management strategies. *Coron Artery Dis* 1996; 7(3): 183-7.
4. Angelini P, Velasco JA, Flamm S. Coronary anomalies: Incidence, pathophysiology, and clinical relevance. *Circulation* 2002; 105(20): 2449-54.
5. Taylor AJ, Rogan KM, Virmani R. Sudden cardiac death associated with isolated congenital coronary artery anomalies. *J Am Coll Cardiol* 1992; 20(3): 640-7.
6. Basso C, Maron BJ, Corrado D, Thiene G. Clinical profile of congenital coronary artery anomalies with origin from the wrong aortic sinus leading to sudden death in young competitive athletes. *J Am Coll Cardiol* 2000; 35(6): 1493-501.
7. Efthimiadis GK, Theofilogiannakos EK, Gossios TD, Paraskevaidis S, Vassilikos VP, Styliadis IH. Hypertrophic cardiomyopathy associated with an anomalous origin of right coronary artery. Case report and review of the literature. *Herz* 2013; 38(4): 427-30.
8. Liddy S, Roy AK, McCreery C. Double trouble: Hypertrophic cardiomyopathy coexistent with malignant anomalous right coronary artery. *BMJ Case Rep* 2014; 2014: bcr2013203344.