

Right ventricular thrombosis as a manifestation of Behçet's syndrome

Payam Ebrahimifar⁽¹⁾, Javad Shahabi⁽²⁾

Case Report

Abstract

BACKGROUND: Behçet's disease (BD) is a rare condition with a classic triad of oral and genital ulceration and eye disease. Cardiovascular complication is a rare finding in BD.

CASE REPORT: In this report, we present a seventeen years old patient with a history of fever for 20 days, who developed a clot in right ventricle (RV). Cardiac magnetic resonance imaging (MRI) and echocardiography demonstrated a thrombosis in RV and a thoracic multi detector computed tomographic image showed pulmonary thromboembolism (PTE) in patient. The patient was administered with methylprednisolone, cyclophosphamide and anticoagulant. A regular follow-up was carried out. Two months later, the RV clot had disappeared on transthoracic echocardiography (TTE).

CONCLUSION: In BD, early cardiac MRI and echocardiography should be performed for the detection of cardiac involvement, and medical treatment is the first choice of treatment.

Keywords: Behçet's Disease, Cardiac Complication, Thrombosis, Magnetic Resonance Imaging

Date of submission: 17 Nov. 2015, *Date of acceptance:* 07 May 2016

Introduction

Behçet's disease (BD) is a rare condition with a classic triad of oral and genital ulceration and eye disease. The other manifestations of BD are rare and include cardiovascular, gastrointestinal, musculoskeletal and central nervous systems.¹ Intracardiac thrombosis is a rare and serious complication that can occur in half of the BD cases although cardiac involvement is not common.² The management of this complication is difficult due to recurrence even after surgical resection of the thrombus. Intracardiac thrombosis is a rare complication of BD which has not been established much in the literature. We report here a case of BD who had thrombosis in right ventricle (RV) due to BD.

Case Report

In March 2015, a 17-year-old man was referred to our hospital by infectious disease specialists for the evaluation of fever for over 20 days. He was treated for viral infection at first by infectious disease specialists. Then antibiotic therapy was conducted due to painful oral and skin lesions on scrotum. Patient suffered from bilateral vision loss and photophobia initiated 3 days before admission to hospital. His body temperature was 38.8 °C, systolic/diastolic blood pressure was 115/70 mmHg and heart rate was

96 bpm when physically examined.

The heart sounds were normal without any murmurs and the lung fields were clear to auscultation. The electrocardiogram showed normal sinus rhythm. The chest X ray was normal. We noted an inflammatory syndrome in the laboratory results (white blood cell count: 113,000 mm³, neutrophil: 60%, C-reactive protein: 62 mg/l, erythrocyte sedimentation rate: 71 mm/hour). Therefore, antibiotics were started due to endocarditis. Blood cultures and serology tests for fever, Legionella, Bartonella, Tropheryma whipplei, Chlamydia, Mycoplasma, and Brucella were negative. The transthoracic echocardiography (TTE) showed a left ventricle ejection fraction of about 65% and a mobile mass seen in RV apex which was hyperechoic and well circumscribed (Figure 1).

A thoracic multi detector computed tomography (MDCT) confirmed the diagnosis of bilateral segmental pulmonary thromboembolism (PTE) and infarction. A transesophageal echocardiogram (TEE) did not show the nature of RV mass. Three differential diagnosis were introduced for RV mass including fever including infection, malignancy and clot. Thus, cardiac magnetic resonance imaging (MRI) was performed and showed that the nature of mass was clot in RV trabeculae (Figure 2).

1- Cardiologist, Isfahan Cardiovascular Research Center, Cardiovascular Research Institute, Isfahan University of Medical Sciences, Isfahan, Iran

2- Assistant Professor, Cardiac Rehabilitation Research Center, Cardiovascular Research Institute, Isfahan University of Medical Sciences, Isfahan, Iran

Correspondence to: Payam Ebrahimifar, Email: payame1383@yahoo.com

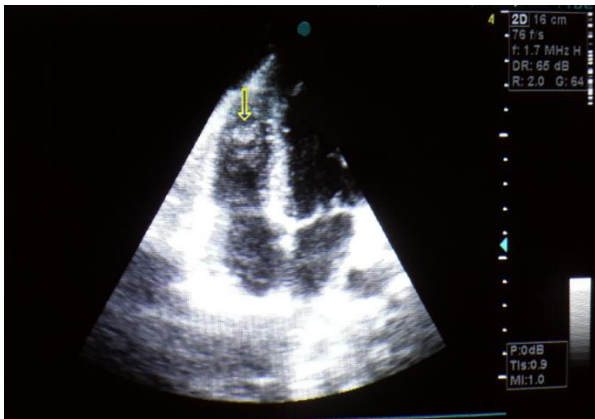


Figure 1. Transthoracic echocardiography (parasternal short-axis view) shows a cardiac mass in the right ventricle (RV)

Oral ulcers had a nonspecific pathology with a variable infiltrate of lymphocytes, macrophages, and neutrophils at the base of the ulcer that showed autoimmune disorder in histopathologic examination. We started treatment with anticoagulant since the patient was at risk of PTE and RV clot caused by leukocytoclastic and lymphocytic vasculitis which may also be seen in severe inflammation. The thrombophilia study did not show any abnormalities, and antinuclear antibody, anti-DNA antibody, anti-extractable nuclear antigen (anti-ENA) antibody, and anti-neutrophil cytoplasmic antibody tests and tumor markers were all negative. We noted a positive HLA-B51 and HLA-B5 serologic typing. Taking these findings together, the patient was diagnosed with BD.

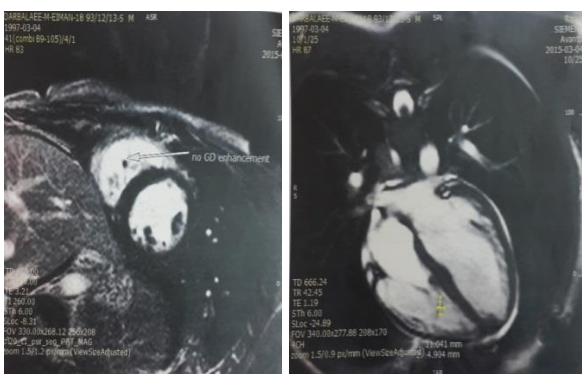


Figure 2. Cardiac magnetic resonance imaging (MRI) shows a clot in the right ventricle (RV)

Corticosteroid (methylprednisolone 1 g per day for 3 days and followed by oral prednisone 1 mg/kg) with cyclophosphamide (1 gram monthly) treatment was started. In addition, warfarin was administered to maintain the international

normalized ratio (INR) at 2.5 or above. Two months later, the RV clot had disappeared on TTE.

Discussion

Behçet's syndrome has been known since Hulusi Behçet, a Turkish dermatologist, described the triple symptom-complex including orogenital ulcerations and iritis with hypopyon.³ Although, the prevalence of vascular involvement in BD varies from 7.7% to 43%, vascular involvement is very important in BD due to serious complications and death.⁴ The underlying pathological mechanism of thrombosis among BD patients is not well known. Several causal factors have been established including endothelial cell disruption, antiphospholipid antibodies,⁵⁻⁷ deficiencies of protein S, protein C, and antithrombin,⁸ increase in von Willebrand factor antigen levels,⁹ and fibrinolysis abnormalities¹⁰ which increase the risk of thrombosis in BD patients. Arachidonic acid metabolism plays an important role in the process of hemostasis and thrombosis. Stimulation of endothelium and platelets results in formation of eicosanoid derivatives including thromboxane B2 (TXB2) and 6-keto-prostaglandin F1 alpha (PGF1a).¹¹

Thrombosis in veins and arteries is one of the most frequent complications in BD which is associated with ocular involvement.¹² Cardiac involvement can be found in 1 to 5 percent of clinical series.¹³

Only 50 cases had been reported with intracardiac thrombi which is a very rare complication.^{14,15} This condition is often associated with deep vein and vena cava thrombosis (50% and 22% of cases, respectively),⁵ and pulmonary complications including pulmonary artery aneurysm or pulmonary embolism were also found.¹⁶⁻¹⁸ Intracardiac thrombosis usually involves the right side of the heart in 78% of cases,¹⁹⁻²² however some studies^{23,24} have reported left ventricle involvement. In our patient, the thrombus was found in the right ventricle, like most of the studies.

Transesophageal and transthoracic echocardiography are appropriate methods for the diagnosis of cardiac thrombosis which show a mass, heterogeneous and echogenic²⁵ that could also be seen in intracardiac tumors such as a myxoma or endomyocardial fibrosis.¹⁶ Imaging tests such as chest computer tomography (CT) and MRI could be helpful in the assessment of thoracic manifestations of BD including thrombus of the systemic veins, heart and pulmonary arteries.

In the present observation, the diagnosis of the

thrombus was obvious on cardiac MRI. Lack of pathognomonic symptoms and diagnostic laboratory tests makes BD difficult to diagnosis. In addition to performing lab tests and imaging, epidemiologic data should also be evaluated such as residing in Mediterranean area, young age and male sex, which increase the risk of BD. The aim of intracardiac thrombosis treatment is to control the underlying disease and resolve the thrombus. Anticoagulant and antithrombotic agents are the first line of therapy.⁷ Surgery might become necessary in cases of massive or recurrent cardiac thrombosis.² In the case presented here, we found that Behçet's syndrome was controlled by immunosuppressive drugs and corticosteroids in our patient.

As a conclusion, one of the possible complications of BD is the thrombosis of the right heart cavities that can lead to pulmonary embolism. Early cardiac MRI and echocardiography should be performed to detect cardiac involvement, and medical treatment is the first choice of treatment.

Acknowledgments

None.

Conflict of Interests

Authors have no conflict of interests.

References

1. Khammar Z, Berrady R, Boukhrissa A, Lamchachi L, Amrani K, Rabhi S, et al. Intracardiac thrombosis in Behcet disease: Clinical presentation and outcome of three cases. *J Mal Vasc* 2011; 36(4): 270-3.
2. Darie C, Knezinsky M, Demolombe-Rague S, Pinede L, Perinetti M, Ninet JF, et al. Cardiac pseudotumor revealing Behcet's disease. *Rev Med Interne* 2005; 26(5): 420-4.
3. Behcet H. Uber rezidivierende aphthose, durch ein virus verursachte Geschwure am Mund, am Auge und an den Genitalien. *Dermatol Wochenschr* 1937; 105: 1152-7.
4. Criteria for diagnosis of Behcet's disease. International Study Group for Behcet's Disease. *Lancet* 1990; 335(8697): 1078-80.
5. Wechsler B, Du LT, Kieffer E. Cardiovascular manifestations of Behcet's disease. *Ann Med Interne (Paris)* 1999; 150(7): 542-54.
6. Baykan M, Celik S, Erdol C, Baykan EC, Durmus I, Bahadir S, et al. Behcet's disease with a large intracardiac thrombus: A case report. *Heart* 2001; 85(4): E7.
7. Mogulkoc N, Burgess MI, Bishop PW. Intracardiac thrombus in Behcet's disease: A systematic review. *Chest* 2000; 118(2): 479-87.
8. Akar N. Site specific mutagenesis: Usage for the mutation detection in thrombosis. *Turk J Haematol* 1998; 15: 123-4.
9. Kiraz S, Ertenli I, Ozturk MA, Haznedaroglu IC, Celik I, Calguneri M. Pathological haemostasis and "prothrombotic state" in Behcet's disease. *Thromb Res* 2002; 105(2): 125-33.
10. Gul A, Ozbek U, Ozturk C, Inanc M, Konice M, Ozelik T. Coagulation factor V gene mutation increases the risk of venous thrombosis in behcet's disease. *Br J Rheumatol* 1996; 35(11): 1178-80.
11. Haznedaroglu IC, Dundar S, Kirazh S. Eicosanoids in the prethrombotic state of Behcet's disease. *Thromb Res* 1995; 80(5): 445-6.
12. Ames PR, Steuer A, Pap A, Denman AM. Thrombosis in Behcet's disease: A retrospective survey from a single UK centre. *Rheumatology (Oxford)* 2001; 40(6): 652-5.
13. Koc Y, Gullu I, Akpek G, Akpolat T, Kansu E, Kiraz S, et al. Vascular involvement in Behcet's disease. *J Rheumatol* 1992; 19(3): 402-10.
14. Hammami S, Mahjoub S, Ben-Hamda K, Brahem R, Gamra H, Ben Farhat M. Intracardiac thrombus in Behcet's disease: Two case reports. *Thromb J* 2005; 3: 9.
15. Buge A, Escourolle R, Chomette G, Rancurel G, Dechy H, Hauw JJ, et al. Behcet's disease with neurologic manifestations and endocardial fibrosis of the right heart. Anatomoclinical study of a case. *Ann Med Interne (Paris)* 1977; 128(5): 411-9.
16. Marc K, Iraqui G, Jniene A, Benamor J, Bourkadi JE. Intracardiac thrombus and pulmonary artery aneurysm in Behcet's disease. *Rev Mal Respir* 2008; 25(1): 69-72.
17. Sayin AG, Vural FS, Bozkurt AK, Oz B, Uygun N. Right atrial thrombus mimicking myxoma and bilateral pulmonary artery aneurysms in a patient with Behcet's disease-a case report. *Angiology* 1993; 44(11): 915-8.
18. Houman M, Ksontini I, Ben Ghorbel I, Lamloum M, Braham A, Mnif E, et al. Association of right heart thrombosis, endomyocardial fibrosis, and pulmonary artery aneurysm in Behcet's disease. *Eur J Intern Med* 2002; 13(7): 455.
19. Louali FE, Tamdy A, Soufiani A, Oukerraj L, Omari D, Bounjoum F, et al. Cardiac thrombosis as a manifestation of Behcet syndrome. *Tex Heart Inst J* 2010; 37(5): 568-71.
20. Gopathi S, Hurt RT, Guardiola J. Intracardiac thrombus in Behcet's disease: A rare case in the United States. *Respir Med CME* 2011; 4(4): 154-6.
21. Fekih M, Fennira S, Ghodbane L, Zaouali RM.

- Intracardiac thrombosis: Unusual complication of Behcet's disease. *Tunis Med* 2004; 82(8): 785-90.
22. Nouredine M, Charei N, Drighil A, Chraibi N. Right intracardiac thrombus in Behcet's disease. *Arch Mal Coeur Vaiss* 2004; 97(9): 925-8.
23. Sacre K, Ducrocq G, Hernigou A, Laissy JP, Papo T. Unusual cardiovascular events in Behcet's disease. *Clin Exp Rheumatol* 2010; 28(4 Suppl 60): S82-S85.
24. Vanhaleweyk G, el-Ramahi KM, Hazmi M, Sieck JO, Zaman L, Fawzy M. Right atrial, right ventricular and left ventricular thrombi in (incomplete) Behcet's disease. *Eur Heart J* 1990; 11(10): 957-9.
25. Islim IF, Gill MD, Situnayake D, Watson RD. Successful treatment of right atrial thrombus in a patient with Behcet's disease. *Ann Rheum Dis* 1994; 53(8): 550-1.

How to cite this article: Ebrahimifar P, Shahabi J, et al. **Right ventricular thrombosis as a manifestation of Behçet's syndrome.** *ARYA Atheroscler* 2017; 13(2): 91-4.