



## Management of iliofemoral vein injury during open inguinal hernia repair

Afshin Farhanchi MD<sup>(1)</sup> , Maziar Bazrafshan MD<sup>(2)</sup> , Maryam Sadeghi-Ghahareh MD<sup>(3)</sup> 

### Case Report

#### Abstract

**BACKGROUND:** Vascular injuries during inguinal hernia repair are rarely reported. Especially in children, we have little information about vascular management.

**CASE REPORT:** In this article, we present a 6-year-old girl with right iliac vein ligation during inguinal hernia repair who was referred to our center and managed at the day of surgery. We recommended prior surgeon to order therapeutic heparin in dispatch time. The patient was treated with primary anastomosis of iliac vein and was admitted to pediatric intensive care unit (PICU). On the day following the operation, she had minimal dyspnea with low oxygen saturation and the investigations revealed pulmonary micro-embolization. Blood flow in lower extremity was normal and after a few days, she was discharged with good health and oral anticoagulation.

**CONCLUSION:** Any unusual bleeding at the time of inguinal hernia repair should be considered as major vascular injury by the surgeon, and to prevent more injuries, minimum attempt must be performed to control the bleeding.

**Keywords:** Femoral Vein; Inguinal Hernia; Anastomosis; Vascular Injuries; Iatrogenic Disease

*Date of submission:* 23 Nov. 2020, *Date of acceptance:* 03 Apr. 2021

#### Introduction

Venous iatrogenic injuries during general and orthopedic surgeries are rarely reported. Over 17 years, only 44 major injuries are reported during abdominal surgery with a mortality rate of 18%.<sup>1</sup> Vascular complications of inguinal hernia surgery are more frequent in laparoscopic repair than open repair, including inferior epigastric injury, venous plexus injury around the pubic symphysis, aberrant obturator vein injury and the most dangerous, iliac vessels injury.<sup>2</sup> It is better to repair the vein injuries during same operation if the surgeon has enough experience, otherwise it is better to refer the patient to vascular surgery center. If bleeding from venous injury is severe resulting in hemodynamic instability, the extremity vein can be ligated when the contralateral vein is patent.<sup>3</sup> As we know repair and management of pediatric vascular injuries are more difficult and need experience and specialized team work at operation and post-operation time.

#### Case Report

A 6-year-old girl was consulted to our vascular center because of suspicion of femoral vein injury

during left inguinal hernia repair. According to the first general surgeon, she had unusual bleeding from the surgical site which inevitably ligated the vessel. He ordered bedside Doppler ultrasound and noticed femoral vein ligation. We advised him to prescribe intravenous heparin with loading dose (80 IU/Kg) then refer the patient to our hospital. After 5 hours and as soon as the patient arrived our center, we visited her. She was awake, oriented, and hemodynamically stable, and had pressure bandage in her left lower limb. After reserve of packed red blood cells (RBCs), she was transferred to the operation room. The inguinal surgery site wound was opened and extended. The inguinal ligament was partially cut and beneath that, the femoral vein was separated and ligated. The femoral artery was explored and had normal appearance and continuity. The defect between distal and proximal ends of the femoral vein was about 1.5 cm (Figure 1).

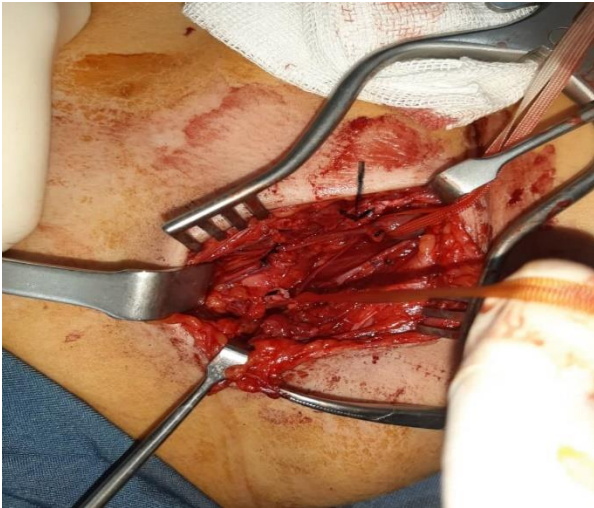
**How to cite this article:** Farhanchi A, Bazrafshan M, Sadeghi-Ghahareh M. Management of iliofemoral vein injury during open inguinal hernia repair. *ARYA Atheroscler* 2022; 18: 2337.

1- Assistant Professor, Department of Anesthesiology, School of Medicine, Hamadan University of Medical Sciences, Hamadan, Iran

2- Assistant Professor, Department of Vascular Surgery, School of Medicine, Hamadan University of Medical Sciences, Hamadan, Iran

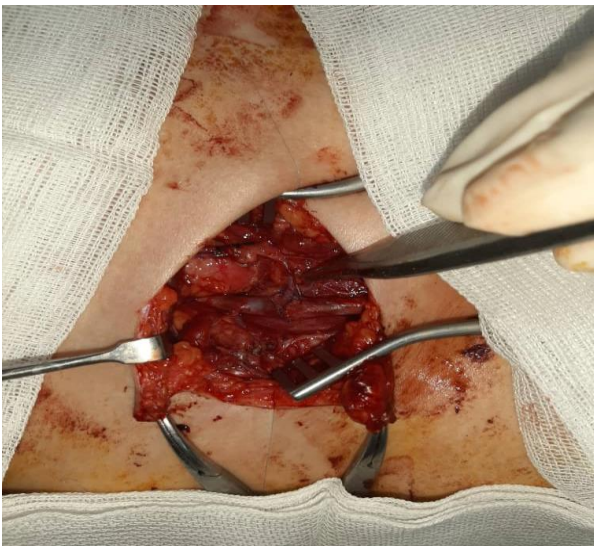
3- Radiologist, Department of Radiology, Hamadan University of Medical Sciences, Hamadan, Iran

Address for correspondence: Maziar Bazrafshan; Assistant Professor, Department of Vascular Surgery, School of Medicine, Hamadan University of Medical Sciences, Hamadan, Iran; Email: [m.bazrafshan@umsha.ac.ir](mailto:m.bazrafshan@umsha.ac.ir)



**Figure 1.** Defect between distal and proximal ends of femoral vein; the arrow shows the collateral proximal vein

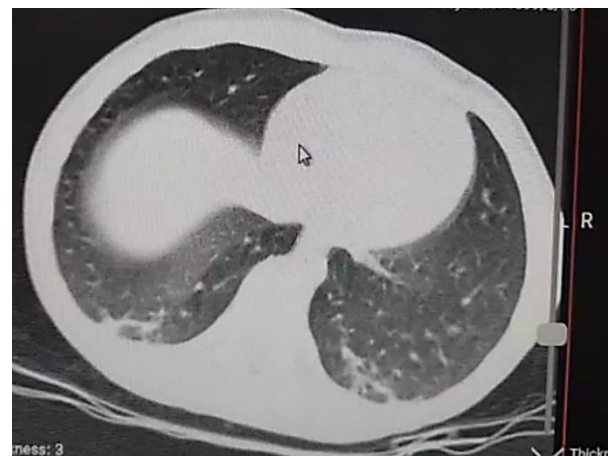The superficial epigastric collateral vein was normal and drained the blood of the limb. Because of the low diameter of the saphenous vein and the disadvantages of artificial graft, we decided to do primary anastomosis of the vein with inevitably mild tension. After release of both ends of the femoral vein with preservation of collaterals, the anastomosis was made with end-to-end method with 7-0 non-absorbable monofilament suture (Figure 2).



**Figure 2.** End-to-end anastomosis between two ends of femoral vein; Pickup forceps shows preserved proximal collateral vein.

It should be noted that most important concern of operation was distal limb thrombosis and subsequent venous thromboembolic events. After

control of distal end of the femoral vein, and in coordination with the anesthesia team, we milked the limb from distal to proximal with pressure band and evacuated about 300 cc blood and a few clots. At the end of operation, the inguinal canal floor was repaired. The patient was stable and extubated with good respiratory function and was transferred to the intensive care unit (ICU). The limb was in compression bandage and elevated. Heparin infusion (18 IU/Kg) was prescribed with control of partial thromboplastin time (PTT) (therapeutic range 60-80). In the first 12 hours of the post-operation time, she had normal urine output with normal blood pressure and heart rate. However, the blood oxygen saturation gradually decreased to 92% without any respiratory distress, which with nasal oxygenation, the saturation increased up to 97%. The body temperature was 36.8 degrees Celsius. Our first differential diagnosis was pulmonary emboli, so we performed echocardiography. The function of the right heart chamber was normal. To rule out other respiratory pathologies such as the coronavirus disease-2019 (COVID-19) pneumonia, we performed chest spiral computed tomography (CT) scan and found non-specific lesions in lower part of right lung (Figure 3).



**Figure 3.** Spiral computed tomography (CT) scan of lungs (notice the lower parts slice)

On the 3<sup>rd</sup> post-operation day, the patient's general condition was good with no change. The limb was soft and non-tender, the foot passive and active flexion were normal, but the blood oxygen saturation was still low and the same as before. So we performed pulmonary CT angiography and found no pathologic signs compatible with pulmonary emboli. The COVID-19 antigen test was negative. We did not find definite diagnosis for her low oxygen saturation. Color Doppler ultrasound

showed patent vein continuity with no leg and thigh thrombosis. The patient was discharged at the 5<sup>th</sup> post operation day with good health and under treatment with 2.5 mg warfarin daily. We visited the patient weekly. After a month, we performed Doppler ultrasound and the blood flow was normal in the femoral and popliteal veins.

### Discussion

Iliofemoral vessel injury during inguinal hernia repair, albeit being rare, is a very serious complication. These injuries can occur in adults and children, but it is more challenging in pediatric patients because of the lower diameter of vessels and low experience in repair. The injury can occur separately or involve both artery and vein. The arterial injury diagnosis is easier because of the loss of distal pulses and ischemic appearance of the limb, but vein injury sometimes has no signs and symptoms except limb swelling. So Doppler ultrasonography should be used for the diagnosis of femoral vein injury because of its high accuracy in detection of venous pathologies.<sup>4</sup> After diagnosis of the venous injury, decision about the kind of treatment is important. If the patient develops deep vein thrombosis due to delay in diagnosis, management of thrombosis will be another problem. Currently, the catheter directed approaches such as catheter directed thrombolysis (CDT), pharmacomechanical CDT, and percutaneous mechanical thrombectomy have become the first choice for treatment of acute deep vein thrombosis.<sup>5</sup> However for patients with iatrogenic venous injury, recanalization of distal veins seems to be ineffective. Therefore, because of the short time from injury, we decided to milk the distal part of the limb with extreme attention to the amount of bleeding. The postoperative intensive care unit (ICU) admission and warning about the signs of pulmonary thromboembolism either micro or macro embolism is important in the first day. Revascularization of the injured vein in children is another issue. Because of the diameter mismatch between the recipient and donor veins, the durability of the bypassed vein is poor. If we can bypass the defect with direct end-to-end anastomosis, it is the best choice. Although the use of greater saphenous vein graft as conduit is preferred, it is important to be aware of its late expansion and aneurysmal degeneration.<sup>6</sup> The use of antiplatelet or anticoagulant drugs as adjuvant treatment in children with vascular injuries, which has major differences with adults due to their

dynamic and clearance, is discussed in literature.<sup>7</sup> Because our patient lacked any underlying pathology, we decided to begin heparin for 3 days and then continue treatment with aspirin up to one month.<sup>3</sup> Another issue in pediatric patients is anesthesia and perioperative care. In contrast to adults, the common method of anesthesia is inhalation agents and postoperative nausea and vomiting are more common.<sup>8</sup> The rehabilitation period of the patient was excellent with no morbidity or restriction in daily activities.

### Conclusion

Iliofemoral vascular complications after inguinal hernia repair in children is rare but serious. Because of the small diameter of vessels, any unusual bleeding from the operation field should raise suspicion of major vascular damage, and the surgeon should monitor the patient for development of clinical signs. If the clinical sign is negative but suspicion is high, then the use of Doppler ultrasound would be very helpful. We recommend early surgical repair in a vascular surgery center and primary end-to-end anastomosis with more exploration and dissection of the vein. The one-month anticoagulation with warfarin seems to be sufficient in these patients.

### Acknowledgments

Authors thank the hospital's ICU team for helping treat the patient.

### Conflict of Interests

Authors have no conflict of interests.

### Authors' Contribution

MB: Surgeon, managing the patient and writing the case report  
 AF: Anesthesiologist, managing the patient and co-author  
 MS, Radiologist, interpretation of the scans and revising the text.

### References

1. Oderich GS, Panneton JM, Hofer J, Bower TC, Cherry KJ, Sullivan T, et al. Iatrogenic operative injuries of abdominal and pelvic veins: a potentially lethal complication. *J Vasc Surg* 2004; 39(5): 931-6.
2. Chowbey PK, Pithawala M, Khullar R, Sharma A, Soni V, Baijal M. Complications in groin hernia surgery and the way out. *J Minim Access Surg* 2006; 2(3): 174-7.

3. Sidawy AP, Perler BA. Rutherford's vascular surgery and endovascular therapy (vol. 2). Philadelphia, PA: Elsevier Health Sciences; 2018. p. 51-2466.
4. Ketenciler S, Boyacioglu K, Akdemir I, Erentug V, Kayalar N. Late surgical treatment of iatrogenic femoral vein ligation during open inguinal hernia repair. *Bagcilar Medical Bulletin* 2016; 1(1): 26-2.
5. Fleck D, Albadawi H, Shamoun F, Knuttinen G, Naidu S, Oklu R. Catheter-directed thrombolysis of deep vein thrombosis: literature review and practice considerations. *Cardiovasc Diagn Ther* 2017; 7(Suppl 3): S228-S237.
6. Cardneau JD, Henke PK, Upchurch GR, Wakefield TW, Graham LM, Jacobs LA, et al. Efficacy and durability of autogenous saphenous vein conduits for lower extremity arterial reconstructions in preadolescent children. *J Vasc Surg* 2001; 34(1): 34-40.
7. Monagle P, Chalmers E, Chan A, deVeber G, Kirkham F, Massicotte P, et al. Antithrombotic therapy in neonates and children: American College of Chest Physicians Evidence-Based Clinical Practice Guidelines (8th Edition). *Chest* 2008; 133(6 Suppl): 887S-968S.
8. Gregory GA, Andropoulos DB. *Gregory's pediatric anesthesia*. 5<sup>th</sup> ed. Hoboken, NJ: Willey-Blackwell; 2012.