

A rare anomalous origin of left subclavian artery from the circle of Willis in combination with right sided aortic arch: A case report

Alireza Ahmadi⁽¹⁾, Seyed Ali Sonbolestan⁽²⁾

Case Report

Abstract

BACKGROUND: One of the rare aortic congenital abnormalities is right sided aortic arch which is occurred in approximately 0.1% of the population. The anomalous origin of the subclavian arteries has also been reported.

CASE REPORT: In this study, a case of a right-sided aortic arch with anomalous left subclavian artery origin from the cerebral arteries is presented which was diagnosed in Computed tomography angiogram (CT angiogram) and angiography of a 10-year-old boy referred due to recurrent chest pains during two weeks before admission and pulselessness of his left upper limb and left carotid artery.

CONCLUSION: Many of the congenital vascular anomalies may have no obvious signs or symptoms and therefore the exact history and physical examination could help us in better diagnosis. Besides, some of these anomalies are associated with other abnormalities of other body organs particularly the cardiac system.

Keywords: Congenital Anomaly, Great Arteries, Pediatric

Date of submission: 08 Dec 2012, *Date of acceptance:* 01 Jun 2013

Introduction

Congenital abnormalities of the aortic arch are sometimes diagnosed in imaging. These abnormalities usually are recognized by accident during imaging for other purposes but it is very important to differentiate the life threatening forms from the other ones.¹ A right sided aortic arch could be diagnosed in about 0.1% of general population and about 50% of these have an aberrant left subclavian artery.^{2,3} The aberrant left subclavian artery may happen without any concurrent anomaly however it is the most frequent anomaly which is associated with a right aortic arch.^{4,5}

In this study, a case of a right-sided aortic arch with anomalous left subclavian artery origin from cerebral arteries is presented which was diagnosed in computed tomography angiogram (CT angiogram) and angiography of a 10-year-old boy who referred due to recurrent chest pains during two weeks before admission and had pulselessness on left carotid and left upper limb arteries.

Case Report

A 10-year-old boy referred to the pediatric cardiology clinic of Chamran Hospital, Isfahan

University of Medical Sciences, Isfahan, Iran on 1-May-2012 with a chief complaint of recurrent chest pain from two weeks ago. He had an atypical chest pain in the 4th and 5th left intercostals areas without any radiation which lasted for several minutes. He had no other symptoms though.

In physical examination, the pulses of left upper limb and left carotid artery were not detected; however, the other pulses were normal. He had no cyanosis or clubbing in his extremities. In heart auscultation, the S1 and S2 sounds were normal and a grade I-II/VI systolic ejection-type murmur was heard on the left sternal border. The other examinations were normal.

No abnormal findings were revealed in electrocardiography.

The cardiothoracic ratio was in upper normal range and the pulmonary vascular markings were normal in chest X-ray (CXR). The right sided aortic arch was observed in figure 1.

The main abnormal findings in echocardiography included mild mitral valve prolapse (MVP) and tricuspid regurgitation (TR) with a pressure gradient of 25 mmHg. Besides, the

1- Assistant Professor, Isfahan Cardiovascular Research Center, Isfahan Cardiovascular Research Institute, Isfahan University of Medical Sciences, Isfahan, Iran

2- Resident, Department of Ophthalmology, Isfahan University of Medical Sciences, Isfahan, Iran

Correspondence to: Seyed Ali Sonbolestan, Email: sonbolestan_ali@yahoo.com

right sided aortic arch was observed.

In CT angiogram, the left carotid artery was significantly narrower than the right one which seemed to be dilated for enough cerebral circulation. Moreover, as a rare anomalous finding, the left subclavian artery aroused from this narrow carotid artery and the left vertebral artery originated from this subclavian artery (Figures 2.A and 2.B).

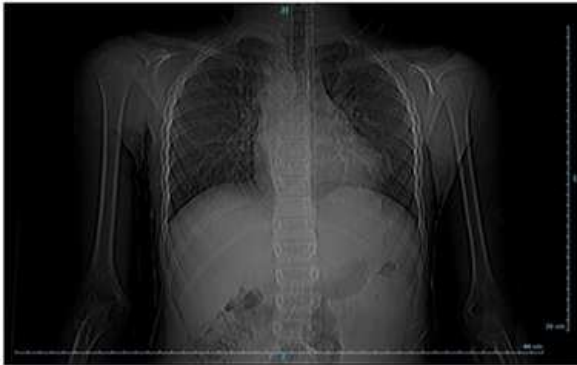

Figure 1. The patient's chest X-ray

Thereafter, the patient underwent the left heart catheterization. The arterial catheter passed from

the femoral artery into descending aorta (DAO), ascending aorta (AAO), and left ventricle (LV), respectively. It entered into the right and left coronary arteries (RCA and LCA) normally.

Systemic sample was saturated. In addition, it entered into the right subclavian and right carotid arteries, but it could not enter into the left brachiocephalic artery.

LV, coronary arteries and aortic root injections revealed no pathologic findings. The right sided aortic arch was observed again. Aortic arch injection in the right anterior oblique view showed normal right subclavian and right carotid arteries and also showed with no connection of the left subclavian artery to the aortic arch.

Selective right carotid artery injection showed opacified left subclavian artery. The left subclavian and left vertebral arteries supplied from the circle of Willis (right vertebral artery). Selective right subclavian artery showed no anomaly (Figures 3.A, 3.B, and 3.C).

Following the whole procedures, the patient was discharged and was advised to refer periodically for clinical follow-up.

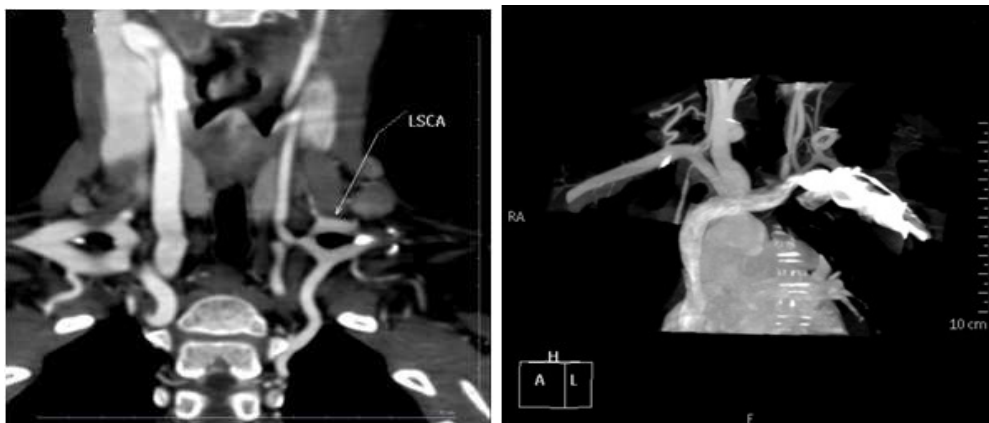


Figure 2. Patient's CT angiogram; (A, left image,) and (B, right image); (A) left carotid artery was significantly narrower than the right one; (B) the left subclavian artery aroused from this narrow carotid artery

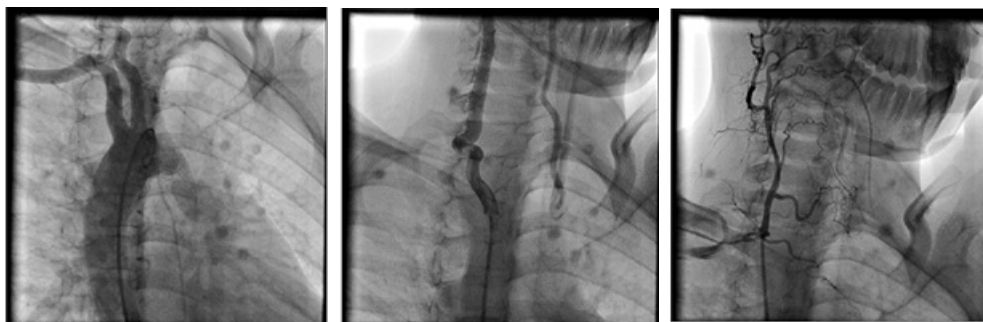

Figure 3. The catheterization findings of the patient; (A, left image), (B, middle image), and (C, right image)

Discussion

In this rare case, a child was presented who had no signs and symptoms except an atypical chest pain and the pulselessness of his left upper limb and left carotid arteries, and finally was diagnosed as the right sided aortic arch with isolated left brachiocephalic artery.

The right sided aortic arch is an anomaly which is seen in different types. One of them is its association with an isolated left subclavian artery. In this rare anomaly, the left subclavian artery does not originate from the aortic arch but it is connected to the left vertebral artery and therefore the circle of Willis provides its blood flow and it may cause subclavian steal syndrome in some cases.⁶

According to the embryologic bases, the left subclavian and the left carotid arteries are derived from the left seventh inter segmental artery and the left third aortic arch, respectively.⁷ Besides, the right sided aortic arch is the consequence of a breakage in the left fourth arch of primal vascular ring and the isolated subclavian artery is the result of breakage in two places of the left fourth arch.

Due to the amplified blood flow of the vertebral artery in an inverted direction, in this anomaly some degrees of ischemia may happen in vertebrobasilar territory and this ischemia may cause some abnormalities during the fetal development.⁸

On the other hand, increased upper limb activity may result in reduction of cerebral blood flow and cause some steal syndrome symptoms.

In another study, this anomaly was observed in association with patent ductus arteriosus (PDA) and ventricular septal defect (VSD)⁶ which were not detected in our patient. In different studies, it was mentioned that it is very rare to have a right sided aortic arch without any concurrent congenital heart anomaly.^{9,10}

In this study, the echocardiography, CT angiography and catheterization were used for the diagnosis. One of the other suitable procedures in patients like this is Doppler ultrasound which could show the flow in neck or cranial arteries. Furthermore, findings of CT scan and magnetic resonance imaging (MRI) can show the effects of this anomaly on the brain tissue per se.

In conclusion, many of the congenital vascular anomalies may have no obvious signs or symptoms and therefore -particularly in the field of pediatrics- the exact history and physical examination could help us in better and faster diagnosis. Besides, some of these anomalies are associated with other abnormalities of other body organs particularly the cardiac system. Imaging modalities can be used in these diagnoses.

Written informed consent was obtained from the patient's parents for publication of this case report and any accompanying images.

Conflict of Interests

Authors have no conflict of interests.

References

1. Davies M, Guest PJ. Developmental abnormalities of the great vessels of the thorax and their embryological basis. *Br J Radiol* 2003; 76(907): 491-502.
2. Vucurevic G, Tanaskovic S, Ilijevski N, Kovacevic V, Kecmanovic V, Radak D. Right-sided aortic arch with anomalous origin of the left subclavian artery: case report. *Srp Arh Celok Lek* 2011; 139(9-10): 666-8.
3. Salanitri J. MR angiography of aberrant left subclavian artery arising from right-sided thoracic aortic arch. *Br J Radiol* 2005; 78(934): 961-6.
4. Franquet T, Erasmus JJ, Gimenez A, Rossi S, Prats R. The retrotracheal space: normal anatomic and pathologic appearances. *Radiographics* 2002; 22(Spec No): S231-S246.
5. Donnelly LF, Fleck RJ, Pacharn P, Ziegler MA, Fricke BL, Cotton RT. Aberrant subclavian arteries: cross-sectional imaging findings in infants and children referred for evaluation of extrinsic airway compression. *AJR Am J Roentgenol* 2002; 178(5): 1269-74.
6. Hayabuchi Y, Inoue M, Sakata M, Ohnishi T, Kagami S. Subclavian and pulmonary artery steal phenomenon in a patient with isolated left subclavian artery and right aortic arch. *J Clin Ultrasound* 2013; 41(4): 265-8.
7. Congdon ED. Transformation of the aortic arch system during the development of the human embryo. *Contrib Embryol* 1922; 14: 47-110.
8. Predey TA, McDonald V, Demos TC, Moncada R. CT of congenital anomalies of the aortic arch. *Semin Roentgenol* 1989; 24(2): 96-113.
9. McElhinney DB, Hoydu AK, Gaynor JW, Spray TL, Goldmuntz E, Weinberg PM. Patterns of right aortic arch and mirror-image branching of the brachiocephalic vessels without associated anomalies. *Pediatr Cardiol* 2001; 22(4): 285-91.
10. Mart CR, Zachary CH, Kupferschmid JP, Weber HS. Tetralogy of Fallot with right aortic arch and isolation of the left innominate artery from a left-sided patent ductus arteriosus. *Pediatr Cardiol* 2001; 22(1): 58-9.

How to cite this article: Ahmadi A, Sonbolestan SA. A rare anomalous origin of left subclavian artery from the circle of Willis in combination with right sided aortic arch: A case report. *ARYA Atheroscler* 2013; 9(5): 303-5.