



Intramyocardial dissecting hematoma: A systematic review and pooled analysis of available literature

Reihaneh Zavar⁽¹⁾ , Azam Soleimani⁽¹⁾, Marzieh Tajmirrahi⁽²⁾, Afshin Amirpour⁽¹⁾, Shaghayegh Mahmoudiandehcordi⁽³⁾, Faezeh Farhang⁽⁴⁾ 

Review Article

Abstract

BACKGROUND: The current systematic review and pooled analysis were conducted to answer several questions using findings from case reports and case series as follows: (1) Demographic characteristics; (2) clinical findings; (3) management approach; and (4) prognosis of individuals diagnosed with intramyocardial dissecting hematoma.

METHODS: Electronic databases, including PubMed (Medline), Scopus, and Web of Science, were systematically searched from the earliest available date up to February 2023 using selected keywords. All analyses were performed using SPSS software version 27 (IBM Corp, Armonk, NY, USA), and a P-value less than 0.05 was considered statistically significant.

RESULTS: A total of 77 patients diagnosed with Intramyocardial dissecting hematoma (IDH) comprised the study population, with a mean (standard deviation) age of 58.72 (13.99) years, of which 22.1% were women. Patients of higher age experienced a higher risk for mortality compared to younger subjects (OR=1.05, 95% CI: 1.01, 1.10; P=0.014). In addition, the implementation of angiography (OR=0.25, 95% CI: 0.08, 0.71; P=0.010) and cardiac magnetic resonance (OR=0.19, 95% CI: 0.06, 0.60; P=0.004) in the context of diagnosis reduced the risk of death compared to those who did not receive these interventions. Similarly, the diagnosis of pericardial effusion significantly increased the risk of mortality compared to those without pericardial effusion (OR=3.92, 95% CI: 1.27, 12.07; P=0.017).

CONCLUSION: The authors found that older patients experience a poor prognosis compared to younger ones. In addition, the utilization of angiography and cardiac magnetic resonance improves the prognosis of individuals. Likewise, the diagnosis of pericardial effusion in patients with IDH increases the odds of mortality.

Keywords: Intramyocardial Dissecting Hematoma; Prognosis; Systematic Review

Date of submission: 11/2/2023, *Date of acceptance:* 12/9/2023

Introduction

Intramyocardial Dissecting Hematoma (IDH) is a rare form of cardiac rupture that can primarily occur as a complication following Acute Myocardial Infarction (MI) or during the remodeling process¹. It can also occur following trauma, during Percutaneous Coronary Angioplasty, ablation of Ventricular Tachycardia, and as a complication of cardiac surgery². It is typically caused by a hemorrhagic dissection through the myocardium¹. The diagnosis

of IDH is considered a challenging approach in practical medicine³. In most cases, it generally occurs several days following the initiation of symptoms and may lead to a myocardial rupture, termed subacute myocardial rupture, which could be fatal³. Up until the 1980s, the diagnosis of IDH mostly relied on the post-mortem approach. The first diagnosis of IDH via echocardiography was reported by Hodsdon in 1981⁴. Differential diagnosis includes prominent ventricular trabeculations, intracavitary thrombosis,

1- Cardiac Rehabilitation Research Center, Cardiovascular Research Institute, Isfahan University of Medical Sciences, Isfahan, Iran.

2- Hypertension research center, cardiovascular research institute, Isfahan University of Medical Sciences, Isfahan, Iran.

3- School of Medicine, Isfahan University of Medical Sciences, Isfahan, Iran.

4- Department of Cardiology, School of Medicine, Chamran Hospital, Isfahan University of Medical Sciences, Isfahan, Iran.

Address for correspondence: Faezeh Farhang; Department of Cardiology, Chamran Cardiovascular Medical and Research Hospital, Isfahan University of Medical Sciences, Isfahan, Iran; Email: faezeh6584@gmail.com

and pseudoaneurysm⁵. With the development of high-resolution echocardiography, more patients were referred for surgery as the diagnosis became possible⁵. Following the introduction of magnetic resonance into clinical practice, the diagnosis of IDH became more accurate⁵.

Depending on various pathological and anatomical parameters, IDH may spread out into the pericardium or adjacent cavity, therefore, it may retract with acceptable outcomes or may increase the clinical risk⁶⁻⁸. There is no consensus regarding the management of IDH. Two main approaches to IDH treatment include conservative medical therapy or surgical repair. Although IDH is also referred to as subacute rupture, some cases may be managed conservatively, and hence not all patients need to be operated on^{9,10}.

Despite the growing awareness of clinical practitioners regarding IDH, there are many unknown issues regarding diagnosis, management, and prognosis¹¹. Moreover, the authors' understanding is mostly reliant upon case control and case series studies with a limited number of participants. Therefore, the current systematic review and pooled analysis were carried out to answer several questions using findings from case reports and case series as follows: (1) Demographic characteristics; (2) clinical

findings; (3) management approach; and (4) prognosis of individuals diagnosed with IDH. The authors' findings may contribute to the existing literature and improve clinical practitioners' understanding of IDH.

Methods and Materials

Search strategy

Electronic databases, including PubMed (Medline), Scopus, and Web of Science, were systematically searched from the earliest available date up to February 2023 using selected keywords. The following keywords were used: "myocardial dissection" OR "myocardial dissecting" OR "myocardial dissecting hematoma" OR "intramyocardial dissecting hematoma" OR "dissection intramyocardial hematoma", and tailored to each database as needed. Google Scholar was manually searched to cover grey literature. The reference list of the enrolled studies was also screened.

Eligibility criteria

All of the search results were exported to the EndNote 20 software (Thomson Corporation, Stamford, USA) to be screened by two independent investigators (R.Z. and A.S.). Original case reports/series reporting IDH diagnosis and treatment

Table 1. General characteristics of enrolled patients with intramyocardial dissecting hematoma

Variables	Total patients (n=77)	Patients who died (n=26)	Patients who survived (n=51)	P-value
Age [mean ± SD (year)]	58.72 ± 13.99	64.46 ± 11.47	55.80 ± 14.34	0.009 ¹
Women [number (%)]	17 (22.1)	7 (26.9)	10 (19.6)	0.464 ²
Due to MI [number (%)]	58 (75.3)	18 (69.2)	40 (78.4)	0.376 ²
ST elevation at ECG [number (%)]	48 (62.3)	17 (65.4)	31 (60.8)	0.694 ²
Angiography [number (%)]	56 (72.7)	14 (53.8)	42 (82.4)	0.008 ²
LVEF [mean ± SD (%)]	31.29 ± 14.08	31.89 ± 14.46	30.93 ± 14.07	0.817 ¹
VSD [number (%)]	5 (6.5)	2 (7.7)	3 (5.9)	0.761 ²
Nonhomogeneous mass/cavity [number (%)]	70 (90.9)	22 (84.6)	48 (94.1)	0.170 ²
Pericardial effusion [number (%)]	17 (22.1)	10 (38.5)	7 (13.7)	0.013 ²
CMR [number (%)]	33 (42.9)	5 (19.2)	28 (54.9)	0.003 ²
CT [number (%)]	18 (23.4)	5 (19.2)	13 (25.5)	0.539 ²
Contrast echocardiography [number (%)]	13 (16.9)	4 (15.4)	9 (17.6)	0.802 ²
Surgery [number (%)]	30 (39.0)	8 (30.8)	22 (43.1)	0.293 ²

¹Calculated by Independent-Samples T test.

²Calculated by Chi-square test.

P<0.05 was considered statistically significant.

MI: Myocardial Infarction; ECG: Electrocardiogram; LVEF: Left Ventricular Ejection Fraction; VSD: Ventricular Septal Defect; CMR: Cardiac Magnetic Resonance; CT: Computerized Tomography.

were included if they provided a separate clinical description for each case regarding etiology, diagnosis, management, and prognosis. However, non-English studies were excluded. No exclusion was made regarding the published years of studies.

Data Extraction

The process of data extraction was carried out by two independent investigators (R.Z. and A.S.) using predefined excel sheets. The authors extracted data of interest including patients' sex, and age. Moreover, data regarding the etiology, echocardiographic data, electrocardiographic data, clinical data, management, and outcome, were extracted if available.

Statistical Analysis

All of the analyses were performed using SPSS software version 27 (IBM Corp, Armonk, NY, USA) and a P-value less than 0.05 was considered statistically significant. Continuous outcomes are presented as mean \pm standard deviation (SD) and categorical ones as number (percentage). Participants were categorized according to the prognosis of surviving and dying patients. The difference in continuous variables across the two groups was assessed by an independent t-test. Distribution of categorical variables across two groups was investigated via Chi-square test. To examine the influence of each demographic and clinical data on the prognosis of individuals with IDH, binary logistic regression was implemented and odds ratio (OR) with a corresponding 95% confidence interval (CI) was reported.

Results

Following a search of electronic databases, a total of 210 studies were found. After de-duplication, 106 remaining citations were screened for title/abstract by two independent investigators. The remaining 95 articles were assessed for eligibility criteria and finally, 63 citations met the inclusion criteria and were enrolled in the current systematic review and pooled-analysis study. The process of the study selection is presented in [Figure 1](#).

In total, 58 case reports^{3,7,12-67} and 5 case series^{2,68-71} studies were included. A total of 77 patients diagnosed with IDH comprised the study population, with a mean (SD) age of 58.72 (13.99)

years, of which 22.1% were women (n=17). Enrolled patients were categorized according to the prognosis of IDH into those who died (poor prognosis) and those who survived (good prognosis), with a sample size of 26 and 51, respectively. Patients with poor prognoses were older with a mean (SD) age of 64.46 (11.47) compared to those with a good prognosis (P=0.009). Moreover, those with a good prognosis were more likely to undergo angiography (P=0.008) and cardiac magnetic resonance (P=0.003). In addition, individuals who survived, compared to those who died, complained less of pericardial effusion (P=0.013). No other significant difference was observed for studied parameters across patients with good and poor prognoses (all P > 0.05). The general characteristics of the enrolled patients with IDH are indicated in [Table 1](#).

The OR and corresponding 95% CI for the influential factors on the prognosis of patients with IDH are shown in [Table 2](#). Patients of higher age experienced a higher risk for mortality compared to younger subjects (OR=1.05, 95% CI: 1.01, 1.10; P=0.014). In addition, the implementation of angiography (OR=0.25, 95% CI: 0.08, 0.71; P=0.010) and cardiac magnetic resonance (OR=0.19, 95% CI: 0.06, 0.60; P=0.004) in the context of diagnosis reduced the risk of death compared to those who did not receive these interventions. Similarly, the diagnosis of pericardial effusion significantly increased the risk of mortality compared to those without pericardial effusion (OR=3.92, 95% CI: 1.27, 12.07; P=0.017). No other significant relationship was observed between the studied parameters and the risk of mortality in patients with IDH (all P > 0.05).

Discussion

The current systematic review and pooled analysis were conducted to summarize available data regarding the diagnosis, management, and prognosis of IDH using case reports and case series. A total of 63 citations, including 58 case reports and 5 case series, were eligible to be enrolled in the current study. The authors found that older patients experience poor prognoses compared to younger ones. In addition, utilizing angiography and cardiac magnetic resonance improves the prognosis of individuals. Likewise, the diagnosis of pericardial effusion in patients with IDH increases the odds of mortality.

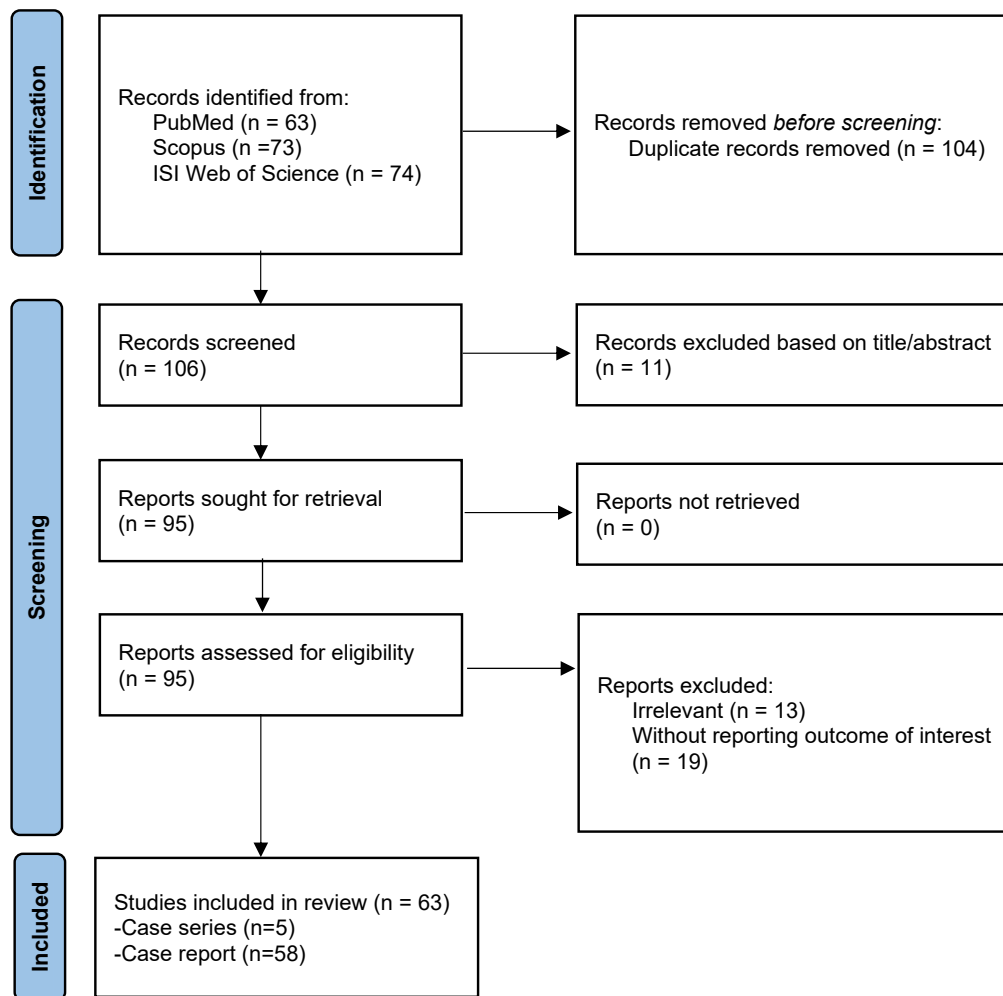


Figure 1. PRISMA flow diagram of the study selection process.

Table 2. OR and 95% confidence interval for influential factors of prognosis in patients with intramyocardial dissecting hematoma

Variables	Good prognosis	Poor prognosis	P-value
Age	Ref	1.05 (1.01, 1.10)	0.014
Women	Ref	1.51 (0.49, 4.57)	0.466
Due to MI	Ref	0.61 (0.21, 1.79)	0.378
ST elevation at ECG	Ref	1.21 (0.45, 3.26)	0.694
Angiography	Ref	0.25 (0.08, 0.71)	0.010
LVEF	Ref	1.005 (0.96, 1.04)	0.813
VSD	Ref	1.33 (0.20, 8.52)	0.761
Nonhomogeneous mass/cavity	Ref	0.34 (0.07, 1.66)	0.185
Pericardial effusion	Ref	3.92 (1.27, 12.07)	0.017
CMR	Ref	0.19 (0.06, 0.60)	0.004
CT	Ref	0.69 (0.21, 2.22)	0.541
Contrast echocardiography	Ref	0.84 (0.23, 3.06)	0.802
Surgery	Ref	0.58 (0.21, 1.59)	0.295

Data are presented as OR (95% confidence interval)

P<0.05 was considered statistically significant.

MI: Myocardial Infarction; ECG: Electrocardiogram; LVEF: Left Ventricular Ejection Fraction; VSD: Ventricular Septal Defect; CMR: Cardiac Magnetic Resonance; CT: Computerized Tomography.

There is limited evidence regarding the diagnosis, management, and prognosis of IDH, and therefore most of the authors' current knowledge is based on case reports. A previous literature review in 2016 among 68 IDH patients revealed that there is no difference between surgical and medical management of IDH concerning survival, although it mentioned that those with right ventricular free wall dissection significantly benefit from surgical repair⁷¹. Another review in 2018 among 40 individuals with IDH concluded that low ejection fraction and age are both determinants of in-hospital mortality¹¹. Hajsadeghi and co-workers in 2020 also reviewed 37 cases of postinfarction IDH and concluded that the mortality rate is higher among those who managed conservatively compared to surgically treated subjects⁷². Although the authors' findings are mostly in agreement with previous reports, some discrepancies are observed mainly due to eligibility criteria and sample size.

IDH is a rare catastrophic complication of myocardial infarction, with over 75% of IDH cases in the authors' study due to myocardial infarction. Becker proposed that a slit-like rupture of the ventricular free wall is linked with collagen breakdown, plasmin generation, and intramyocardial hemorrhage, and may have been exacerbated by previous thrombolytic therapy⁷³. It was also suggested that IDH may occur subsequently to inadequate reperfusion¹¹. Inadequate blood supply led to necrosis, with a tear of cell membranes, capillaries disruption, and hemorrhage, with hypoxia-induced endothelial disruption proposed as the primary mechanism for hemorrhage¹¹. Occlusion of coronary arteries resulted in an inflammatory response, disruption of the endothelial junction, swelling, and increased endothelial stress⁷⁴. In addition, reperfusion leads to extravasation of red blood cells into the tissue interspaces, damage to the endothelial junction, and leakiness. Moreover, activation of metalloproteinases - proteolytic enzymes - disrupts the basal and interstitial membrane collagen matrix and augments hemorrhage⁷⁴. A total of 62.3% of the authors' study population presented persistent ST elevation and clinical evidence of recent myocardial infarction. These subjects are at higher risk for IDH and therefore should be taken into account while managing these patients.

As mentioned in a previous literature review,

IDH mostly affects the left ventricle-free wall and to a lesser extent septum and right ventricle-free wall, respectively⁷¹. Moreover, it frequently occurs within 7-10 days post myocardial infarction; however, the rare cases with old myocardial infarction may also progress to IDH. Therefore, its early and accurate diagnosis needs a high level of suspicion. Echocardiography is one of the first diagnosis approaches demonstrating IDH as a hypochoic segment or a non-homogeneous neo-cavitation⁷¹. The authors demonstrated that the presence of pericardial effusion increases the risk of mortality by 3.92 times. Pericardial effusion may be the sign of evolving myocardial rupture, as it demonstrates the communication with the pericardial space. Likewise, the authors showed that a ventricular septal defect may increase the risk of poor prognosis by 1.33 times, although it was statistically non-significant. In those with anterior myocardial infarction, the apical septum is often involved and therefore the presence of a ventricular septal defect may complicate the course⁷⁵.

Cardiac Magnetic Resonance (CMR) is considered the gold standard for IDH diagnosis¹¹. Additionally, the explanation of Late Gadolinium Enhancement (LGE) and T2-weighted combination with LGE images, rest perfusion, and evaluation of Early Gadolinium Enhancement (EGE) might provide more details and differentiate it from intraluminal thrombus⁷⁶. Accordingly, the authors also revealed that implementing this tool decreased the risk of mortality by 71%. T1 and T2 relaxation approaches usually assist in the diagnosis of IDH due to their sensitivity to blood products⁷⁷. The T1-weighted technique presents hyperintense lesions in the affected areas, which can be inferred in clinical practice as blood products related to subacute hemorrhage⁷⁷. Hyperintense foci that are consistent with fat or edema can be detected via the T2-weighted approach⁷⁷.

Patients with IDH can be managed conservatively or surgically considering various factors. Individuals with low ejection fraction, compromised hemodynamics, ventricular septal defect, and the expansion of the dissection on serial echocardiographic studies, especially in those with anterior myocardial infarction, should undergo surgery. IDH limited to the apex has a high probability of spontaneous reabsorption, and an

initial conservative approach may be reasonable. In the absence of a complete tear of the myocardium, conservative management is the recommendation of choice because of the high risk of surgery and the possibility that the myocardium may heal over time. Medical treatment of heart failure and hemodynamic stabilization with close follow up and serial echocardiography are used in these cases. Anticoagulation can be considered to reduce the risk of thromboembolism but its use must be balanced against the risk of progression of dissection and bleeding into the pericardial space⁶⁰. Therefore, patients without dangerous predictors (i.e., pericardial effusion and ventricular septal defect), those with a small lesion localized to the apex, and with stable hemodynamics, especially in subjects whom the culprit artery had been opened, may benefit from conservative management^{11,78}. According to the authors' findings, using angiography and CMR may also be considered for these patients in the early stage of diagnosis to improve the prognosis.

Strength and limitation

The current systematic review and pooled analysis can be considered the most updated resource regarding the diagnosis, management, and prognosis of individuals with IDH. Moreover, the authors comprehensively searched various databases to empower the robustness of their findings. However, some limitations warrant consideration. The authors used case reports and case series with known inherent bias and limitations owing to the methodological nature. Moreover, since patients were enrolled from different parts of the world and health centers, imaging of each case, types of surgical intervention, and clinical circumstances, are likely to be different.

Conclusion

IDH is indeed considered a rare complication with a challenging diagnosis. Therefore, a high level of suspicion and awareness among clinical practitioners are vital for early and accurate diagnosis. The authors found that older patients experience a poor prognosis compared to younger ones. In addition, utilizing angiography and CMR improves the prognosis of individuals. Likewise, the diagnosis of pericardial effusion in patients with IDH increases the odds of mortality. These findings highlight the importance

of early diagnosis and appropriate management strategies in improving the outcomes for patients with IDH.

Conflict of Interest

The authors declare no conflict of interest.

Funding

The current study was supported by the Isfahan University of Medical Sciences, Isfahan, Iran

Authors' contribution

R.Z. and A.S.: Conceptualization, Methodology, Formal analysis, Writing - Original Draft, Writing - Review & Editing. F. F.: Conceptualization, Writing - Original Draft, Writing - Review & Editing, Supervision. The author(s) read and approved the final manuscript

References

1. Mohan JC, Agarwala R, Khanna SK. Dissecting intramyocardial hematoma presenting as a massive pseudotumor of the right ventricle. *Am Heart J* 1992;124(6):1641-2. [https://doi.org/10.1016/0002-8703\(92\)90091-9](https://doi.org/10.1016/0002-8703(92)90091-9)
2. Leitman M, Tyomkin V, Sternik L, Copel L, Goitein O, Vered Z. Intramyocardial dissecting hematoma: Two case reports and a meta-analysis of the literature. *Echocardiography* 2018;35(2):260-6. <https://doi.org/10.1111/echo.13796>
3. Pliam MB, Sternlieb JJ. Intramyocardial Dissecting Hematoma: An Unusual Form of Subacute Cardiac Rupture. *J Card Surg* 1993;8(6):628-37. <https://doi.org/10.1111/j.1540-8191.1993.tb00422.x>
4. Hodsden J, Nanda NC. Dissecting aneurysm of the ventricular septum following acute myocardial infarction: diagnosis by real time two-dimensional echocardiography. *Am Heart J*. 1981 May;101(5):671-2. [https://doi.org/10.1016/0002-8703\(81\)90236-2](https://doi.org/10.1016/0002-8703(81)90236-2)
5. Vargas-Barrón J, Romero-Cárdenas A, Roldán F-J, Molina-Carrión M, Avila-Casado C, Villavicencio R, et al. Long-term follow-up of intramyocardial dissecting hematomas complicating acute myocardial infarction. *J Am Soc Echocardiogr*. 2005 Dec;18(12):1422. <https://doi.org/10.1016/j.echo.2005.03.010>
6. Drozd J, Kasprzak JD, Krzeminska-Pakula M. Spontaneous closure (thrombosis) of the intramyocardial dissection: 40-month follow-up. *J Am Soc Echocardiogr*. 2002 Sep;15(9):1023-4. <https://doi.org/10.1067/mje.2002.122081>
7. Dias V, Cabral S, Gomes C, Antunes N, Sousa

- C, Vieira M, et al. Intramyocardial dissecting haematoma: a rare complication of acute myocardial infarction. *Eur J Echocardiogr.* 2009 Jun;10(4):585-7. <https://doi.org/10.1093/ejehocardiography/jep027>
8. Özpelit E, Badak Ö, Özpelit ME, Kozan Ö. Rapid retraction of a post-infarction intramyocardial dissecting hematoma. *Turk Kardiyol Dern Ars.* 2014 Jun;42(4):380-3. <https://doi.org/10.5543/tkda.2014.43896>
 9. Schram G, Essadiqi B, Doucet M, Bouchard D, Amyot R. Ventricular septal rupture and right ventricular free wall dissection after inferior myocardial infarction: a case report and review of the literature. *J Am Soc Echocardiogr.* 2010 Jul;23(7):791.e1-3. <https://doi.org/10.1016/j.echo.2009.11.020>
 10. Tighe DA, Paul JJ, Maniet AR, Flack JE 3rd, Mannion JD, Rifkin RD, Raichlen JS. Survival in Infarct Related Intramyocardial Dissection Importance of Early Echocardiography and Prompt Surgery. *Echocardiography.* 1997 Jul;14(4):403-408. <https://doi.org/10.1111/j.1540-8175.1997.tb00742.x>
 11. Leitman M, Tyomkin V, Sternik L, Copel L, Goitein O, Vered Z. Intramyocardial dissecting hematoma: Two case reports and a meta-analysis of the literature. *Echocardiography.* 2018 Feb;35(2):260-6. <https://doi.org/10.1111/echo.13796>
 12. Scanu P, Lamy E, Commeau P, Grollier G, Charbonneau P. Myocardial dissection in right ventricular infarction: two-dimensional echocardiographic recognition and pathologic study. *Am Heart J.* 1986 Feb;111(2):422-5. [https://doi.org/10.1016/0002-8703\(86\)90167-5](https://doi.org/10.1016/0002-8703(86)90167-5)
 13. Patoli D, Alghanem H, Tung A. A Rare Cause of a Left Atrial Mass. *J Cardiothorac Vasc Anesth* 2020;34(10):2827-9. <https://doi.org/10.1053/j.jvca.2020.06.053>
 14. Fernandez MG, Reyes G. Intramyocardial Dissecting Hematoma After AMI. *Rev Esp Cardiol* 2019;72(9):774. <https://doi.org/10.1016/j.rec.2018.06.034>
 15. Vargas-Barrón J, Roldán FJ, Romero-Cárdenas A, Espinola-Zavaleta N, Keirns C, González-Pacheco H. Two- and three-dimensional transesophageal echocardiographic diagnosis of intramyocardial dissecting hematoma after myocardial infarction. *J Am Soc Echocardiogr.* 2001 Jun;14(6):637-40. <https://doi.org/10.1067/mje.2001.109984>
 16. Lee TJ, Roslan A, Teh KC, Ghazi A. Intramyocardial dissecting haematoma mimicking left ventricular clot, a rare complication of myocardial infarction: a case report. *Eur Heart J Case Rep.* 2019 Jun 1;3(2):ytz056. <https://doi.org/10.1093/ehjcr/ytz056>
 17. Rezaei-Kalantari K, Saedi S, Alizadeasl A, Naghshbandi M. Left ventricular intramyocardial dissection after myocardial infarction. *Echocardiography.* 2020 Dec;37(12):2160-62. <https://doi.org/10.1111/echo.14843>
 18. Hernandez CM, Nanda NC, Puebla MDS, Rivera AR, Campos JS, Bernal CLP, et al. Incremental value of live/real-time three-dimensional transthoracic echocardiography over the two-dimensional technique in the assessment of left ventricular endocardial rupture with myocardial dissection and contained apical epicardial rupture following myocardial infarction. *Echocardiography.* 2021 Jun;38(6):1064-69. <https://doi.org/10.1111/echo.15056>
 19. Roldán FJ, Vargas-Barrón J, Aguirre-Espinosa M, Romero-Cárdenas A, Vázquez-Antona C, Erdmenger-Orellana J, et al. Subepicardial aneurysm: echocardiographic evaluation and evolution. *Echocardiography.* 2009 May;26(5):504-7. <https://doi.org/10.1111/j.1540-8175.2008.00843.x>
 20. Okada M, Watanuki H, Sugiyama K, Futamura Y, Matsuyama K. Unusual rupture of left ventricular pseudo-false aneurysm secondary to subacute anterolateral myocardial infarction: a case report. *J Cardiothorac Surg.* 2019 May 17;14(1):93. <https://doi.org/10.1186/s13019-019-0915-x>
 21. Escutia-Cuevas HH, Rodríguez-Serrano JG, Torres-Medina Y, Fernández-Ceseña E, Rosales-Uvera SG, Castro-Gutiérrez A, et al. Intramyocardial dissecting hematoma of the right ventricle secondary to acute myocardial infarction. Case report. *Rev Mex Cardiol* 2017;28(1):40-6.
 22. Kulkarni SK, Rangan K, Beeresh P. A rare complication of acute myocardial infarction: Intramyocardial dissecting hematoma. *Echocardiography* 2019;36(1):182-3. <https://doi.org/10.1111/echo.14195>
 23. Aggeli C, Lampropoulos K, Giannopoulos G, Pitsavos C, Stefanadis C. Dissecting intramyocardial haematoma diagnosed by contrast echocardiography. *Hellenic J Cardiol.* 2010 Mar-Apr;51(2):166-9.
 24. Panduranga P, Valliattu J, Al-Mukhaini M. Right ventricular free wall intramyocardial hematoma after coronary bypass. *Asian Cardiovasc Thorac Ann.* 2013 Jun;21(3):355-7. <https://doi.org/10.1177/0218492312454744>
 25. Agarwal G, Kumar V Jr, Srinivas KH, Manjunath CN, Prabhavathi B. Left Ventricular Intramyocardial Dissecting Hematomas. *JACC Case Rep.* 2020 Oct 7;3(1):94-8. <https://doi.org/10.1016/j.jaccas.2020.07.038>
 26. Vuruşkan E, Alıç E, Düzen İ, Kaplan M, Altunbaş G, Sucu M. An unusual complication due to a standard coronary angioplasty procedure: Intramyocardial dissecting hematoma. *Anatol J Cardiol.* 2021 Jun;25(6):E22-E23. <https://doi.org/10.5152/AnatolJCardiol.2021.62702>

27. Prashanth P, Mukhaini M, Maddali MM. Intramyocardial dissecting haematoma causing cardiac tamponade: an unusual complication after mitral valve replacement surgery. *Ann Card Anaesth.* 2009 Jan-Jun;12(1):79-80. <https://doi.org/10.4103/0971-9784.45019>
28. Barbone A, Iaccarino A, Tosi P, Regazzoli Lancini D, Crescenzi G, Reimers B, et al. Intracardiac hematoma treated conservatively by ECMO support. *Artif Organs.* 2022 Jul;46(7):1436-1438. <https://doi.org/10.1111/aor.14273>
29. Zavar R, Vakhshoori M, Mirmohammadsadeghi M, Hashemi-Jazi M. A rare case of takotsubo syndrome led to intra-myocardial dissection and left ventricular apical aneurysm. *ARYA Atheroscler.* 2019 Jan;15(1):33-37. <http://dx.doi.org/10.22122/arya.v15i1.1885>
30. Bapat VN, Naik AM, Lokhandwala Y, Tendolkar AG. Intramyocardial dissecting hematoma. *Circulation* 1998;97(24):2470-2. <https://doi.org/10.1161/01.CIR.97.24.2470>
31. Alyousef T, Malhotra S, Iskander F, Gomez J, Basu A, Tottleben J, et al. Left Ventricular Intramyocardial Dissecting Hematoma: A Multimodality Imaging Diagnostic Approach. *Circ Cardiovasc Imaging.* 2021 Jul;14(7):e012410. <https://doi.org/10.1161/CIRCIMAGING.121.012410>
32. Gattani R, Bakhshi H, Ofosu-Somuah A, Qian X, Atkins M. Multimodality Imaging Assessment of Ventricular Septal Rupture and Intramyocardial Dissecting Hematoma Post Late-Presenting Acute Myocardial Infarction. *Circ Cardiovasc Imaging* 2021;14(10):e013185. <https://doi.org/10.1161/CIRCIMAGING.121.013185>
33. Osuna JGG, Barcos AM, Diarte EC, Lezcano JSR, Gonzalez JJS, Peralta LJP. Conservative management of a post infarction intramyocardial dissecting hematoma. *Rev Esp Cardiol* 2003;56(7):735-7. <https://doi.org/10.1157/13049656>
34. Degrauwe S, Monney P, Muller O, Ruchat P, Qanadli SD, Eeckhout E, et al. Subepicardial hematoma of the left ventricle mimicking acute anterior myocardial infarction. *Circulation.* 2015 Jan 13;131(2):222-4. <https://doi.org/10.1161/CIRCULATIONAHA.114.013594>
35. Deora S, Gurmukhani SN, Shah S, Patel T. Post myocardial infarction ventricular septal defect causing left ventricular intramyocardial dissecting hematoma: a very rare complication. *J Echocardiogr.* 2013 Sep;11(3):113-4. <https://doi.org/10.1007/s12574-013-0173-1>
36. Koch KE, Raiszadeh F, Godelman A, Palma E, Forman R. Giant Left Ventricular Pseudoaneurysm and Myocardial Dissection as a Complication of Multiple Ventricular Tachycardia Ablations in a Patient with Cardiac Sarcoidosis. *Clin Med Insights Cardiol.* 2015 Nov 9;9:105-7. <https://doi.org/10.4137/CMC.S23863>
37. Özpelit E, Badak Ö, Özpelit ME, Kozan Ö. Rapid retraction of a post-infarction intramyocardial dissecting hematoma. *Turk Kardiyol Dern Ars.* 2014 Jun;42(4):380-3. <https://doi.org/10.5543/tkda.2014.43896>
38. Faludi R, Tóth L, Komócsi A, Varga-Szemes A, Papp L, Simor T. Chronic postinfarction pseudo-pseudoaneurysm diagnosed by cardiac MRI. *J Magn Reson Imaging.* 2007 Dec;26(6):1656-8. <https://doi.org/10.1002/jmri.21165>
39. Gandhi S, Wright D, Salehian O. Getting over a Broken Heart: Intramyocardial Dissecting Hematoma as Late Presentation of Myocardial Infarction. *CASE (Phila).* 2017 Oct 19;1(6):245-9. <https://doi.org/10.1016/j.case.2017.07.008>
40. Yaman M, Arslan U, Aksakal A, Ates AH. Giant Intramyocardial Dissecting Hematoma: A Rare Sequela of Subacute Myocardial Infarction. *Tex Heart Inst J.* 2016 Jun 1;43(3):277-8. <https://doi.org/10.14503/THIJ-15-5142>
41. Harpaz D, Kriwisky M, Cohen AJ, Medalion B, Rozenman Y. Unusual form of cardiac rupture: sealed subacute left ventricular free wall rupture, evolving to intramyocardial dissecting hematoma and to pseudoaneurysm formation--a case report and review of the literature. *J Am Soc Echocardiogr.* 2001 Mar;14(3):219-27. <https://doi.org/10.1067/mje.2001.110780>
42. Hrudka J. Intramyocardial dissecting hematoma: fatal complication of reperfusion damage in myocardial infarction - an autopsy case report. *Cardiovasc Pathol.* 2020 Jan-Feb;44:107151. <https://doi.org/10.1016/j.carpath.2019.107151>
43. Ni B, Wu H, Zhu X, Shao Y. Myocardial dissection caused by Takayasu's arteritis complicated with sinus of Valsalva aneurysm. *Eur Heart J Cardiovasc Imaging.* 2022 Nov 17;23(12):e541. <https://doi.org/10.1093/ehjci/jeac181>
44. Kovacevic DV, Cankovic Z, Vodopivec Z, Vujin B, Vuckovic D, Topalov V. Myocardial dissection due to temporary cardiac pacemaker. *Herz.* 2009 Dec;34(8):643-4. <https://doi.org/10.1007/s00059-009-3261-2>
45. Kovacic JC, Horton MDA, Campbell TJ, Wilson SH. Left atrial hematoma complicating inferior myocardial infarction. *J Am Soc Echocardiogr.* 2004 Nov;17(11):1201-3. <https://doi.org/10.1016/j.echo.2004.06.003>
46. Lovasz D, Camboni D, Zeller J, Schmid C. Case report: Recovery after large intramyocardial dissecting haematoma of the ventricular septum--a rare complication of myocardial infarction. *Eur*

- Heart J Case Rep. 2021 Feb 18;5(2):ytaa579. <https://doi.org/10.1093/ehjcr/ytaa579>
47. Yuen HC, Shek J, Wong CK, Tsui PT, Mok NS, Chan NY, et al. An Unusual Case of Intramyocardial Dissecting Hematoma. *CASE (Phila)*. 2021 Aug 26;6(1):16-20. <https://doi.org/10.1016/j.case.2021.07.015>
 48. Maselli D, Micalizzi E, Pizio R, Audo A, De Gasperis C. Posttraumatic left ventricular pseudoaneurysm due to intramyocardial dissecting hematoma. *Ann Thorac Surg*. 1997 Sep;64(3):830-1. [https://doi.org/10.1016/S0003-4975\(97\)00547-X](https://doi.org/10.1016/S0003-4975(97)00547-X)
 49. Méjean S, Lairez O, Boudou N, Carrié D. Intramyocardial dissecting haematoma of the left ventricle apex after an anterior myocardial infarction. *Eur Heart J*. 2013 Mar;34(9):683. <https://doi.org/10.1093/eurheartj/ehs448>
 50. Miura A, Uemura Y, Takemoto K, Uchikawa T, Koyasu M, Ishikawa S, et al. Early Spontaneous Remission of Intramyocardial Dissecting Hematoma. *Intern Med*. 2017;56(9):1067-70. <https://doi.org/10.2169/internalmedicine.56.7967>
 51. Muehling OM, Huber A, Schmoeckel M, Behr J. Non-invasive diagnosis of an intramyocardial dissecting haematoma of the left ventricular free wall by cardiac magnetic resonance. *Heart*. 2007 Jan;93(1):71. <https://doi.org/10.1136/hrt.2006.088237>
 52. Mollace R, Cau R, Guglielmo M, Brusoni D, Pontone G. Multimodality imaging of intramyocardial dissecting haematoma. *Eur Heart J Cardiovasc Imaging*. 2021 Sep 20;22(10):e154. <https://doi.org/10.1093/ehjci/jeab100>
 53. Kądzioła O, Molek P, Zalewski J, Urbańczyk-Zawadzka M, Nessler J, Gackowski A. Apical intramyocardial dissecting hematoma: a rare complication of acute myocardial infarction. *Pol Arch Intern Med*. 2021 Oct 27;131(10):16055. <https://doi.org/10.20452/pamw.16055>
 54. Politi MT, Vivas MF, Filipini E, Chillik I, Riznyk LM, Avegliano G, et al. Three-dimensional echocardiography for predicting postoperative ventricular volumes after surgical ventricular reconstruction of left ventricular aneurysm: A case-based presentation. *Echocardiography*. 2017 Aug;34(8):1250-3. <https://doi.org/10.1111/echo.13617>
 55. Wei Y, Zhang B. Progressive intramyocardial dissecting hematoma in the apex of the left ventricle after percutaneous coronary intervention. *Quant Imaging Med Surg*. 2020 Dec;10(12):2370-3. <https://doi.org/10.21037/qims-20-508>
 56. Akinseye O, Nayyar M, Weiman D, Fan TH. Left Atrial Intramyocardial Dissecting Hematoma From Blunt Trauma Mimicking Left Atrial Tumor. *J Am Coll Cardiol* 2019;73(9_Supplement_1):2269. [https://doi.org/10.1016/S0735-1097\(19\)32875-X](https://doi.org/10.1016/S0735-1097(19)32875-X)
 57. Tey YS, Jalaluddin MS, Rahim AAA. Misfortune Upon Misfortune: Intramyocardial Dissecting Hematoma With Pulmonary Embolism. *J Am Coll Cardiol* 2021;77(18_Supplement_1):2336. [https://doi.org/10.1016/S0735-1097\(21\)03691-3](https://doi.org/10.1016/S0735-1097(21)03691-3)
 58. Pandat S, Saleh Y, Chebrolu LHB, Kassi M, Chou LCP, Kleiman NS. A Case of Intramyocardial Dissecting Hematoma Recovered With Va-Ecmo Support. *J Am Coll Cardiol* 2022;79(9_Supplement):3003. [https://doi.org/10.1016/S0735-1097\(22\)03994-8](https://doi.org/10.1016/S0735-1097(22)03994-8)
 59. Xie J, Chen A, Ma Z, Xu X, Wei X. Intramyocardial dissecting hematoma associated with a coronary sinus diverticulum: a rare cause of chest pain. *Intern Emerg Med*. 2023 Mar;18(2):667-669. <https://doi.org/10.1007/s11739-022-03111-9>
 60. Tanabe J, Okazaki K, Endo A, Tanabe K. Left Ventricular Intramyocardial Dissecting Hematoma. *CASE (Phila)*. 2021 Sep 3;5(6):349-353. <https://doi.org/10.1016/j.case.2021.07.016>
 61. Sakrana AA, Alzubaidi SAA, Shahat AM, Mahmoud AS, Naeim HA. Cardiovascular magnetic resonance and echocardiographic findings of a large thrombosed intramyocardial dissecting hematoma: a case report and a brief review of literature. *BJR Case Rep*. 2020 Jun 3;6(4):20200028. <https://doi.org/10.1259/bjrcr.20200028>
 62. Charfeddine S, Feki W, Maaloul I, Hammami R, Daoud E. An apical mass of the left ventricle after a myocardial infarction: Imaging contribution. *J Saudi Heart Assoc* 2020;32(4):454-7. <https://doi.org/10.37616/2212-5043.1227>
 63. Slepian R, Salemi A, Min J, Skubas N. A hypo-echoic, intramyocardial space: echocardiographic characteristics of an intramyocardial dissecting hematoma. *Anesth Analg*. 2007 Dec;105(6):1564-6. <https://doi.org/10.1213/01.ane.0000287251.23400.df>
 64. Urmeneta Ulloa J, Molina Boraio I, Portolés Ocampo A, Lapuente González P, Moreno Esteban E, Calvo Cebollero I. Intramyocardial Dissecting Hematoma: Cardiac Trauma and Ischemic Heart Disease: Multimodality Imaging Techniques. *Echocardiography*. 2016 Aug;33(8):1262-4. <https://doi.org/10.1111/echo.13253>
 65. Verna E, Repetto S, Saveri C, Forgiione N, Merchant S, Binaghi G. Myocardial dissection following successful chemical ablation of ventricular tachycardia. *Eur Heart J*. 1992 Jun;13(6):844-6. <https://doi.org/10.1093/oxfordjournals.eurheartj.a060267>
 66. Yilmaz F, Guler GB, Karaca O, Guler E, Kizilirmak F, Sensoy B. Subacute anterior wall myocardial infarction complicated by intramyocardial dissection. *Am J Emerg Med*. 2012 Jun;30(5):834.e5-6. <https://doi.org/10.1016/j.ajem.2011.03.005>

67. Apostolović S, Kostić T, Laban N, Stanković V. Conservatively treated intramycardial dissecting haematoma of the interventricular septum as a rare complication of acute myocardial infarction: A case report. *Eur Heart J Case Rep* 2022;6(7). <https://doi.org/10.1093/ehjcr/ytac295>
68. Allende NG, Santos R, Sokn FJ, Merino SA, Accastello GM, Medina JC, et al. Unusual presentations of cardiac rupture during COVID-19 pandemic. *Echocardiography*. 2021 Mar;38(3):469-472. <https://doi.org/10.1111/echo.15006>
69. Rossi Prat M, de Abreu M, Reyes G, Wolcan JD, Saenz JX, Kyle D, et al. Intramycardial Dissecting Hematoma: A Mechanical Complication Needing Surgical Therapy? *JACC Case Rep* 2022;4(21):1443-8. <https://doi.org/10.1016/j.jaccas.2022.07.025>
70. Roslan A, Jauhari Aktifanus AT, Hakim N, Megat Samsudin WN, Khairuddin A. Intramycardial Dissecting Hematoma in Patients with Ischemic Cardiomyopathy: Role of Multimodality Imaging in Three Patients Treated Conservatively. *CASE (Phila)*. 2017 Aug 28;1(4):159-62. <https://doi.org/10.1016/j.case.2017.05.004>
71. Zhao Y, He YH, Liu WX, Sun L, Han JC, Man TT, et al. Intramycardial Dissecting Hematoma after Acute Myocardial Infarction-Echocardiographic Features and Clinical Outcome. *Echocardiography*. 2016 Jul;33(7):962-9. <https://doi.org/10.1111/echo.13198>
72. Hajsadeghi S, Amirfarhangi A, Pakbaz M, Pazoki M, Tanha K. Postinfarction intramycardial dissection, an interesting case report and systematic review. *Echocardiography*. 2020 Jan;37(1):124-131. <https://doi.org/10.1111/echo.14565>
73. Becker AE, van Mantgem JP. Cardiac tamponade. A study of 50 hearts. *Eur J Cardiol*. 1975 Dec;3(4):349-58.
74. Ghugre NR, Pop M, Thomas R, Newbigging S, Qi X, Barry J, et al. Hemorrhage promotes inflammation and myocardial damage following acute myocardial infarction: insights from a novel preclinical model and cardiovascular magnetic resonance. *J Cardiovasc Magn Reson* 2017;19(1):1-13. <https://doi.org/10.1186/s12968-017-0361-7>
75. Crenshaw BS, Granger CB, Birnbaum Y, Pieper KS, Morris DC, Kleiman NS, et al. Risk factors, angiographic patterns, and outcomes in patients with ventricular septal defect complicating acute myocardial infarction. GUSTO-I (Global Utilization of Streptokinase and TPA for Occluded Coronary Arteries) Trial Investigators. *Circulation*. 2000 Jan 4-11;101(1):27-32. <https://doi.org/10.1161/01.CIR.101.1.27>
76. Wu KC. Wu KC. CMR of microvascular obstruction and hemorrhage in myocardial infarction. *J Cardiovasc Magn Reson*. 2012 Sep 29;14(1):68. <https://doi.org/10.1186/1532-429X-14-68>
77. Sakrana AA, Alzubaidi SAA, Shahat AM, Mahmoud AS, Naeim HA. Cardiovascular magnetic resonance and echocardiographic findings of a large thrombosed intramycardial dissecting hematoma: a case report and a brief review of literature. *BJR Case Rep*. 2020 Jun 3;6(4):20200028. <https://doi.org/10.1259/bjrcr.20200028>
78. Osuna JG, Barcos AM, Diarte EC, Lezcano JS-R, Gonzalez JS, Peralta LP. Conservative management of a post infarction intramycardial dissecting hematoma. *Ediciones Doyma Sa Trav De Gracia* 17-21, 08021 Barcelona, Spain; *Rev Esp Cardiol* 2003;56(7):735-7.

How to cite this article: Zavar R, Soleimani A, Tajmirriahi M, Amirpour A, Mahmoudiandehcordi S, Farhang F. **Intramycardial dissecting hematoma: A systematic review and pooled analysis of available literature.** *ARYA Atheroscler* 2024; 20(1): 62-71.