



The effect of risperidone and electroconvulsive therapy on corrected QT interval in electrocardiogram of psychiatric patients

Bahareh Rezaei⁽¹⁾ , Hossein Javdani⁽²⁾ , Maryam Soleimannejad⁽³⁾ ,
Samira Dodangeh⁽⁴⁾ 

Original Article

Abstract

BACKGROUND: Some types of antidepressants and antipsychotic medications have cardiovascular side effects that can be life-threatening. Electroconvulsive therapy (ECT) is capable of generating physiological stress and may lead to increased QT interval followed by arrhythmias. Risperidone can also increase the risk of arrhythmia by increasing the corrected QT (QTc) interval. Since many patients require co-administration of risperidone and ECT, this study aimed to investigate the concurrent effect of ECT and risperidone administration on the QTc interval.

METHODS: For this cross-sectional study, 60 patients (18-65 years) admitted in 22 Bahman Psychiatric Hospital (Qazvin, Iran) that were candidate for treatment with risperidone, ECT, or both methods were concurrently divided into three groups. The groups included patients treated with ECT, risperidone, and combination treatment (risperidone and ECT). At the beginning of the study, electrocardiogram (ECG) was obtained for all patients and QT was performed manually, and finally, QTc interval was measured two times for each group. Required information was collected through medical records. Then, inferential statistics, analysis of variance (ANOVA), was used to determine differences between different variables.

RESULTS: A significant increase in heart rate (HR) in the third group compared to first and second groups was observed. None of the treatments had a significant effect on QTc interval, but the QTc interval increased slightly in groups treated with the ECT alone and particularly, the ECT plus risperidone in comparison to the baseline values.

CONCLUSION: Our study showed that risperidone, ECT, and their concomitant combination did not affect the QTc interval. Therefore, risperidone and ECT are safe and their combination can also be a good option for refractory patients undergoing ECG monitoring and cardiopulmonary devices.

Keywords: Antipsychotic; Arrhythmia; Electroconvulsive Therapy; QTc Interval; Risperidone

Date of submission: 06 Jan. 2021, *Date of acceptance:* 25 Feb. 2021

Introduction

There have been many reports of cardiovascular morbidity and mortality in patients with mental illness.¹ Antipsychotic medications have cardiovascular side effects that lead to cardiac arrhythmias and even death of patients without a history of heart disease.¹ Prolonged corrected QT (QTc) interval due to heart disease or treatment complications can increase the risk of cardiac arrhythmias, leading to ventricular fibrillation (VF) and sudden cardiac arrest.²⁻⁴

In 2013, a study introduced antipsychotic medications with cardiovascular complications including ziprasidone, olanzapine, risperidone, and quetiapine on the QTc interval.

How to cite this article: Rezaei B, Javdani H, Soleimannejad M, Dodangeh S. **The effect of risperidone and electroconvulsive therapy on corrected QT interval in electrocardiogram of psychiatric patients.** ARYA Atheroscler 2021; 17: 2335.

1- Psychiatrist, Department of Psychiatry, Clinical Research Development Unit, 22 Bahman Hospital, Qazvin University of Medical Sciences, Qazvin, Iran

2- Assistant Professor, Department of Psychiatry, Clinical Research Development Unit, 22 Bahman Hospital, Qazvin University of Medical Sciences, Qazvin, Iran

3- Assistant Professor, Department of Psychiatry, School of Medicine, Qazvin University of Medical Sciences, Qazvin, Iran

4- PhD, Children Growth Research Center, Research Institute for Prevention of Non-Communicable Diseases, Qazvin University of Medical Sciences, Qazvin, Iran

Address for correspondence: Hossein Javdani; Assistant Professor, Department of Psychiatry, Clinical Research Development Unit, 22 Bahman Hospital, Qazvin University of Medical Sciences, Qazvin, Iran; Email: javdani_md@yahoo.com

These drugs were classified into three categories: high risk, moderate risk, and low risk for increasing QTc interval and torsades de pointes (TdP).⁵

Risperidone, in the moderate risk group, is one of the important, effective, and widely-used medications in psychiatric patients, which in many cases cannot be eliminated or even delayed due to the patient's condition.^{5,6}

Many patients receiving risperidone, concurrently receive electroconvulsive therapy (ECT). ECT is one of the most effective psychiatric treatments. Nowadays, this procedure that is carefully refined with anesthesia interventions is considered safe and effective for patients with major depressive disorder (MDD), mania, schizophrenia, and other severe psychiatric disorders. ECT may relieve severe depression within a week, but its full benefits may require several treatment sessions over several weeks.⁷ Complications of ECT are headache, confusion, delirium, memory loss, tooth fracture, back pain, muscle pain, nausea, and vomiting.⁸ Mortality of this method is 0.002% per session and in other words, a mortality rate of 0.01 per patient.

The most common cause of death after ECT is myocardial infarction (MI) and cardiac dysrhythmias, so that electrocardiogram (ECG) changes are similar to myocardial ischemia.⁹ In addition, studies have shown that ECT is directly associated with increased QTc dispersion immediately after treatment.^{10,11}

Up to the present time, no study has surveyed effect of two widely-used simultaneous treatments, risperidone + ECT, on QTc interval. Therefore, the researchers of this study decided to compare the effect of both single and simultaneous administration of risperidone and ECT on QTc interval. The importance of this study is evident if it finds synergistic effect of risperidone and ECT on increase of QTc interval; a solution should be searched for reducing the risk of this increase in patients receiving these two treatments at the same time. On the other hand, if this hypothesis is rejected, we can more safely select combination therapy for mental patients.

Materials and Methods

This cross-sectional study included patients who were admitted in psychiatry ward of 22 Bahman Hospital of Qazvin, Iran, from January 2018 to January 2019. After obtaining the approval of the Ethics Committee with code of IR.QUMS.REC.1396.152 from the Research Center of Qazvin University of Medical

Sciences, participants aged 18-65 years and candidate for treatment with risperidone, ECT, or both methods concurrently were included. In addition, exclusion criteria were: 1) concurrent administration of risperidone with drugs that affect the QTc interval such as pimozide and chlorpromazine as well as thioridazine and ziprasidone (drugs at risk of developing TdP), 2) the low levels of magnesium and potassium in the studied patients were < 1.8 and < 3.5 (meq/l), respectively, 3) patients with a history of QTc interval above 500 milliseconds.

The sample size was calculated 60 when $\alpha = 0.5$ and the power of study assumed to be 0.8; patients were selected randomly according to inclusion and exclusion criteria.

The selected patients were divided into three groups and were matched for sex and age. The first group consisted of patients treated with ECT alone during the hospitalization. The second group consisted of patients treated with risperidone alone during 2 weeks and the third group consisted of patients receiving combination treatment of risperidone (for 2 weeks) and ECT. At the beginning of the study, ECG was obtained for all patients and QT was performed manually on all leads (avF, avR, avL, I, II, III, V1-V6). QT numbers were measured at three heart rates (HRs) and their averages were recorded; then QT correction was performed using Hodges formulae $[(QT + 1.75 (HR-60))]$. Finally, QTc interval was measured two times for group 1 (immediately after the first ECT and 24 hours after the last ECT), one time for group 2 (after at least 2 weeks of treatment with risperidone), and two times for group 3 (immediately after the first ECT and 24 hours after the last ECT). The normal QTc interval of the general population is 400 milliseconds (maximum rate in women is equal to 460 milliseconds and in men 450 milliseconds); and if the QTc interval values are greater than 500 milliseconds, it is considered a high risk factor for TdP.

Required information collected through medical records included demographic variables such as age, gender, disease diagnosis, history of heart disease (QTc < 500), average length of stay in hospital, the number of ECTs prescribed and ECG changes (QTc, QT, and HR interval), and energy levels received during the study.

Statistical analysis: All statistical analyses were performed with SPSS software (version 20.0, IBM Corporation, Armonk, NY, USA). Continuous and categorical variables were reported as mean \pm standard deviation (SD) and number (percent), respectively. Comparing differences between groups

was evaluated with analysis of variance (ANOVA) and chi-square test for continuous and categorical variables, respectively. In this study, P-values less than 0.05 were considered statistically significant.

Results

The mean age of the patients in the study was 35.50 ± 9.39 years and there was no significant difference between the three groups in terms of mean age ($P = 0.26$). Whereas, there was a statistically significant difference between the three groups in terms of gender; from all patients 18 (30%) were women (Table 1).

Among the diagnosed diseases of participants, schizophrenia (38.3%) was the most prevalent type of disorder, whereas there was no significant difference in mental disorders between the three groups ($P = 0.036$). MDD (35%), bipolar disorder (25%), and schizophrenia (20%) were the most frequent types of disorders among ECT group. The most prevalent disorders among ECT + risperidone group were schizophrenia (45%) and bipolar disorder (35%), followed by schizoaffective disorder (SAD) (10%), other specified psychotic disorders (5%), and MDD (5%), while no chronic conversion and substance-induced psychotic disorder was seen in any of the patients. In risperidone group, only two diseases, bipolar disorder (50%) and schizophrenia (50%), were reported.

Of all patients, only three patients in group 3 had a history of heart disease. The mean duration of use of risperidone for the patients was 21.55 ± 6.51 days and the mean final dose of risperidone was 6.37 ± 1.31 .

The average length of stay in hospital was 26.30 ± 5.93 days and there was no significant difference between patients in the three groups ($P = 0.056$). Average number of ECT sessions prescribed for patients (groups 1 and 2) was 6.83 times and there was no significant difference between the two groups ($P = 0.089$). The average amount of energy received during sessions was 448.26 Joules, which was significantly different

between the two groups receiving ECT ($P = 0.002$).

The results showed that ECT immediately caused a slight increase in HR ($P = 0.08$), while it decreased at 24 hours after the last ECT compared to the value after the first ECT ($P = 0.10$); but these differences were not statistically significant (Figure 1). In addition, the results of changes in HR at two different times in the risperidone group did not show a statistically significant difference ($P = 0.91$).

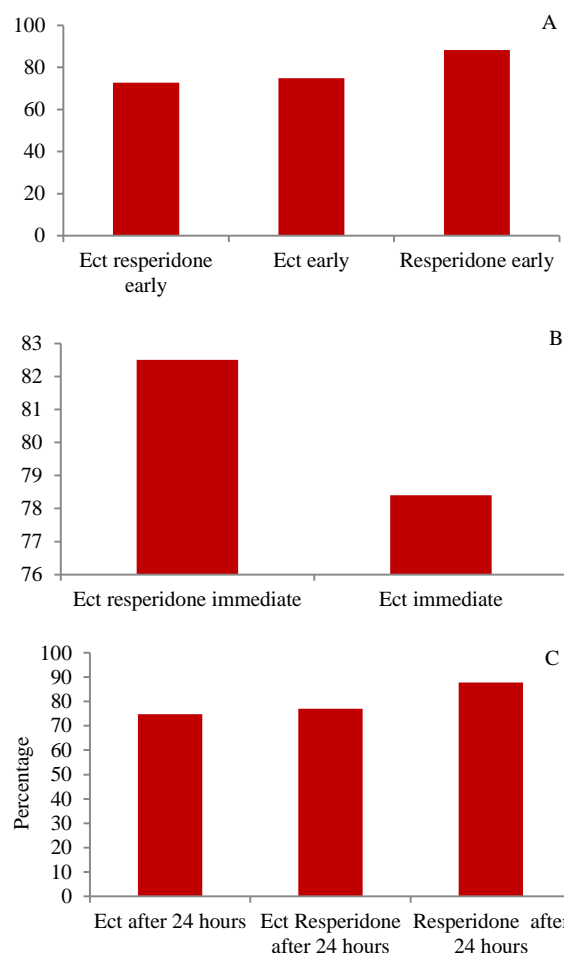


Figure 1. Mean measures of heart rate (HR) between three groups in different stages

A: Early stage; B: Immediate stage; C: After 24 hours

Table 1. Demographics and clinical characteristics between the study participants

	ECT (n = 20)	Risperidone (n = 20)	ECT + risperidone (n = 20)	P
Age (year)	36.50 ± 9.62	32.80 ± 8.67	37.40 ± 9.57	0.267
Gender (women)	7 (35)	9 (45)	2 (10)	0.040
History of heart disease*	0 (0)	0 (0)	3 (15)	0.040
Length of stay in hospital (day)	27.15 ± 5.97	23.75 ± 3.76	28.00 ± 7.10	0.054
Number of ECT sessions prescribed	6.80 ± 1.00	-	6.85 ± 1.22	0.889
Energy received during sessions (Joules)	398.90 ± 39.48	-	497.62 ± 124.33	0.002

Data are reported as mean \pm standard deviation (SD) or number (percent); analysis of variance (ANOVA) and chi-square (or Fisher's exact) test were used

*Such as arrhythmia, congenital long-QT syndrome (LQTS), congenital heart disease, cardiovascular disease (CVD)

ECT: Electroconvulsive therapy

Table 2. Mean measures of corrected QT (QTc) intervals between the study patients

	ECT (n = 20)	Risperidone (n = 20)	ECT + risperidone (n = 20)	P
Early*	385.15 ± 14.43	395.52 ± 30.42	378.60 ± 26.08	0.230
Late**	386.17 ± 19.17	385.73 ± 24.50	375.58 ± 29.02	0.400

Data are reported as mean ± standard deviation (SD); analysis of variance (ANOVA) was used to compare three groups

*Before starting electroconvulsive therapy (ECT) and risperidone; **In group 1 and 3, 24 hours after the last electroconvulsive therapy (ECT), in group 2, at least 2 weeks after treatment with risperidone
ECT: Electroconvulsive therapy

Therefore, it can be concluded that risperidone had no effect on HR in this group (Figure 1), whereas HR at three different time points in the ECT + risperidone group showed a statistically significant difference ($P = 0.03$). Therefore, combination treatment of ECT + risperidone had a significant effect on patients' HR (Figure 1).

There are non-significant differences between QTc measures in three groups of study as mentioned in table 2. Whereas only one case of arrhythmia (sinus tachycardia with 127 beats per minute immediately after the first ECT) was observed in the ECT + risperidone group.

Discussion

The aim of this study was to compare the simultaneous or single effect of two commonly-used treatments (risperidone and ECT) on ECG profile of patients with more focus on QTc interval, which is one of the important factors in predicting arrhythmia in patients. Our results demonstrated no change in HR in the risperidone and ECT groups, but a significant change was observed in the HR in the ECT + risperidone group. A similar study published by Choure et al. has shown that risperidone was capable of increasing HR, but in their study, increased HR was still within the normal range of 60 to 100.¹² It is noteworthy that in our study, also the mean HR increased in the normal range of 60 to 100. Whereas, HR above 110 was only observed in three cases, all of whom were in the ECT + risperidone group and it occurred immediately after the first ECT. Risperidone has been reported to affect through dopamine blockers, serotonin, muscarinic, alpha-adrenergic, and histamine receptors.¹³ Increased HR in treatment with risperidone is associated with its sympathomimetic activity. Risperidone tendency to block muscarinic receptors is much higher than other drugs such as olanzapine.¹³

Rasmussen et al. demonstrated that high QTc dispersion measured on a baseline ECG was positively associated with the number of arrhythmias occurring during ECG sessions.¹⁴ A

study of Erdil et al. reported an initial QTc interval of less than 440 milliseconds in depressed young patients.¹⁵ The results of this study according to the average age of patients who were from the youth group of the community and average QTc interval of patients in the normal range of 385.15 were similar to Erdil et al.'s findings, whereby the initial values of QTc were within the normal range.

Margari et al. did not report significant changes in cardiovascular parameters in patients treated with risperidone,¹⁶ which is similar to the findings of the present study. But in a study by Choure et al., a significant increase in QTc interval was reported with risperidone treatment.¹² It may be justified because they did not use any anesthesia drug.

Propofol has been known to be an appropriate drug for patients with prolonged QTc interval, but its effect on QTc interval is yet controversial.^{17,18} Some studies have reported that it is able to increase the QTc interval,¹⁹ while other studies have shown its little effect.^{20,21} In the present study, propofol was used to induce anesthesia and the QTc interval increased slightly after ECT, but it was not statistically significant. Thus, it can be hypothesized that propofol may be partly effective in preventing QTc interval prolongation by attenuation of sympathetic stimulation during ECT.

In the present study, there was no significant increase in QTc interval in patients receiving both risperidone and ECT, and this interval remained normal in all patients. A clinical trial has examined the effect of combination of ECT with antipsychotic medications (olanzapine or risperidone) in sixteen refractory cases of schizophrenia, where no serious adverse events have been reported; however, asymptomatic ST elevation was observed in a patient after second ECT session in V3 and V4 leads.²² An Indian meta-analysis has also examined the effect of the combination of ECT and antipsychotic medications in the acute phase of schizophrenia, indicating that it was safe with minimal adverse effects.²³ A retrospective study involving 5482 ECT sessions in 455 patients reported that the side effects of ECT

did not increase significantly with concomitant use of antipsychotic medications.²⁴ In a 20-year-old man with catatonic stupor, no adverse events were reported after combination of 17 ECT sessions with olanzapine.²⁵ In the study of Dodd et al., no association of QTc interval dispersion with atypical antidepressant or antipsychotic medication and ECT was reported in 105 patients.²⁶ According to the absence of a significant increase in QTc interval in patients receiving both risperidone and ECT in the current study, special attention should be paid to the possibility of ECT inhibitor activity with propofol as stated for ECT treatment alone, because another study has reported that the combination of ECT with propofol may be associated with decrease in QTc.¹⁵ Of course, patients receiving only risperidone had a mild decrease in QTc in our study. But a slight increase in QTc interval occurred in the ECT group and the combination of the two treatments, which was not statistically significant. However, the QTc interval reduced in 24 hours after the last ECT relative to the start of treatment in the combination group. Thus, the combination of the two treatments seems to have no adverse effect on QTc interval.

In the present study, only one case of arrhythmia was observed in the combination of risperidone and ECT. Cardiac arrhythmias such as sinus and ventricular tachycardia (VT) and premature atrial and ventricular contractions are more common during seizures or postictal period.²⁷ Erdil et al. have observed sinus tachycardia or premature ventricular contractions as cardiac arrhythmias during ECT-induced seizures.¹⁵ The findings of the present study should be interpreted cautiously in the light of some limitations such as the low number of patients. Furthermore, the influence of other factors on our findings cannot be completely ignored. Despite these limitations, the results of our study suggest that concomitant treatment with risperidone and ECT under ECG monitoring and cardiopulmonary resuscitation may be a safe treatment option for psychiatric patients.

Conclusion

Our study showed that risperidone, ECT, and their concomitant combination did not affect the QTc interval. Therefore, risperidone and ECT are safe and their combination can also be a good option for refractory patients undergoing ECG monitoring and cardiopulmonary devices. Accordingly, it is well known that the chronic course of mental illnesses imposes many economic

and social problems on patients, their families, and the community; any suitable therapeutic approaches should be considered to control the symptoms of patients with lower complications and higher safety.

Acknowledgments

The authors gratefully thank all those who contributed to the research (22 Bahman Hospital of Qazvin). This study has been derived from a residency dissertation (IR.QUMS.REC.1396.152) approved by Qazvin University of Medical Sciences.

Conflict of Interests

Authors have no conflict of interests.

Authors' Contribution

BR did the study and contributed in preparing manuscript. HJ designed the study and contributed in editing the manuscript. MSN analyzed the data. SD contributed in preparing and editing the manuscript.

References

1. Correll CU, Solmi M, Veronese N, Bortolato B, Rosson S, Santonastaso P, et al. Prevalence, incidence and mortality from cardiovascular disease in patients with pooled and specific severe mental illness: a large-scale meta-analysis of 3,211,768 patients and 113,383,368 controls. *World Psychiatry* 2017; 16(2): 163-80.
2. Stoner SC. Management of serious cardiac adverse effects of antipsychotic medications. *Ment Health Clin* 2017; 7(6): 246-54.
3. Mulder ME, Verwey B, van Waarde JA. Electroconvulsive therapy in a terminally ill patient: when every day of improvement counts. *J ECT* 2012; 28(1): 52-3.
4. Cristancho MA, Alici Y, Augoustides JG, O'Reardon JP. Uncommon but serious complications associated with electroconvulsive therapy: recognition and management for the clinician. *Curr Psychiatry Rep* 2008; 10(6): 474-80.
5. Beach SR, Celano CM, Noseworthy PA, Januzzi JL, Huffman JC. QTc prolongation, torsades de pointes, and psychotropic medications. *Psychosomatics* 2013; 54(1): 1-13.
6. Gupta A, Lawrence AT, Krishnan K, Kavinsky CJ, Trohman RG. Current concepts in the mechanisms and management of drug-induced QT prolongation and torsade de pointes. *Am Heart J* 2007; 153(6): 891-9.
7. Sadock BJ, Sadock V. Kaplan and Sadock's synopsis of psychiatry: Behavioral. Trans. Rafiei H, Rezaei F. Tehran, Iran: Arjmand Publications;

2004. [In Persian].
8. Weiner RD, Coffey C, Fochtmann L. The practice of electroconvulsive therapy: Recommendations for treatment, training, and privileging: A task force report of the American Psychiatric Association, 2nd ed. Arlington, VA: American Psychiatric Association; 2001.
 9. Najafi M, Tavakoli S, Ganji F, Rostami A. Effect of video education on reduction of post ETC complications. *Iran J Med Educ* 2011; 10(5): 1216-27. [In Persian].
 10. Nahshoni E, Aizenberg D, Strasberg B, Dorfman P, Sigler M, Imbar S, et al. QT dispersion in the surface electrocardiogram in elderly patients with major depression. *J Affect Disord* 2000; 60(3): 197-200.
 11. Suzuki Y, Miyajima M, Ohta K, Yoshida N, Omoya R, Fujiwara M, et al. Is prolongation of corrected QT interval associated with seizures induced by electroconvulsive therapy reduced by atropine sulfate? *Pacing Clin Electrophysiol* 2017; 40(11): 1246-53.
 12. Choure BK, Gosavi D, Nanotkar S. Comparative cardiovascular safety of risperidone and olanzapine, based on electrocardiographic parameters and blood pressure: A prospective open label observational study. *Indian J Pharmacol* 2014; 46(5): 493-7.
 13. Richelson E, Souder T. Binding of antipsychotic drugs to human brain receptors focus on newer generation compounds. *Life Sci* 2000; 68(1): 29-39.
 14. Rasmussen KG, Hooten WM, Dodd ML, Ryan DA. QTc dispersion on the baseline ECG predicts arrhythmias during electroconvulsive therapy. *Acta Cardiol* 2007; 62(4): 345-7.
 15. Erdil F, Demirbilek S, Begec Z, Ozturk E, Ersoy MO. Effects of propofol or etomidate on QT interval during electroconvulsive therapy. *J ECT* 2009; 25(3): 174-7.
 16. Margari L, Matera E, Craig F, Petruzzelli MG, Palmieri VO, Pastore A, et al. Tolerability and safety profile of risperidone in a sample of children and adolescents. *Int Clin Psychopharmacol* 2013; 28(4): 177-83.
 17. Booker PD, Whyte SD, Ladusans EJ. Long QT syndrome and anaesthesia. *Br J Anaesth* 2003; 90(3): 349-66.
 18. Koca E, Erdil FA, Toprak HI, Ersoy NGO, Durmus M. The effects of propofol-ketamine combination on QTc interval in patients with coronary artery disease. *Med Science* 2021; 10(2): 278-82.
 19. Abrich VA, Ramakrishna H, Mehta A, Mookadam F, Srivathsan K. The possible role of propofol in drug-induced torsades de pointes: A real-world single-center analysis. *Int J Cardiol* 2017; 232: 243-6.
 20. Kleinsasser A, Kuenszberg E, Loeckinger A, Keller C, Hoermann C, Lindner KH, et al. Sevoflurane, but not propofol, significantly prolongs the Q-T interval. *Anesth Analg* 2000; 90(1): 25-7.
 21. Kuenszberg E, Loeckinger A, Kleinsasser A, Lindner KH, Puehringer F, Hoermann C. Sevoflurane progressively prolongs the QT interval in unpremedicated female adults. *Eur J Anaesthesiol* 2000; 17(11): 662-4.
 22. Tang WK, Ungvari GS. Efficacy of electroconvulsive therapy combined with antipsychotic medication in treatment-resistant schizophrenia: a prospective, open trial. *J ECT* 2002; 18(2): 90-4.
 23. Painuly N, Chakrabarti S. Combined use of electroconvulsive therapy and antipsychotics in schizophrenia: The Indian evidence. A review and a meta-analysis. *J ECT* 2006; 22(1): 59-66.
 24. Nothdurfter C, Eser D, Schule C, Zwanzger P, Marcuse A, Noack I, et al. The influence of concomitant neuroleptic medication on safety, tolerability and clinical effectiveness of electroconvulsive therapy. *World J Biol Psychiatry* 2006; 7(3): 162-70.
 25. Tan QR, Wang W, Wang HH, Zhang RG, Guo L, Zhang YH. Treatment of catatonic stupor with combination of modified electroconvulsive treatment and olanzapine: a case report. *Clin Neuropharmacol* 2006; 29(3): 154-6.
 26. Dodd ML, Dolenc TJ, Karpayak VM, Rasmussen KG. QTc dispersion in patients referred for electroconvulsive therapy. *J ECT* 2008; 24(2): 131-3.
 27. Wajima Z. Complication of Electroconvulsive Therapy. In: Saito S, editor. *Anesthesia management for electroconvulsive therapy*. New York, NY: Springer; 2016. p. 125-54.