

## Echocardiographic characteristics of isolated left ventricular noncompaction

Afsoon Fazlinezhad<sup>(1)</sup>, Mohammad Vojdanparast<sup>(2)</sup>, Shadi Sarafan<sup>(3)</sup>, Pouya Nezafati<sup>(4)</sup>

### Case Series

#### Abstract

**BACKGROUND:** Although isolated left ventricular noncompaction (ILVNC) has been described almost two decades ago, our knowledge about its diagnosis, presentation, echocardiographic features and clinical outcome is sparse. We aimed to assess the echocardiographic and clinical characteristics of ILVNC in a group of patients referred to our center.

**METHODS:** Patients who were referred to a tertiary referral center, affiliated with Mashhad University of Medical Sciences, with primary diagnosis of dilated cardiomyopathy underwent comprehensive echocardiographic evaluation. The diagnosis of ILVNC was made based on the presence of two-structural layer in myocardium; ratio of noncompacted to compacted layers more than 2, and excessive trabeculation in the left ventricle.

**RESULTS:** Final diagnoses of ILVNC were made in 42 patients. Mean age of patients was  $32.9 \pm 15.6$  years (ranging from 9 to 70 years). Females comprised a higher proportion of patients (61.9%) and shortness of breath was the most reported symptom among patients (47.6%). Non-compacted layers were detected in inferior and lateral segments of apex in 97.6% of patients. A total of 26 (61.9%) patients had left ventricle (LV) dysfunction (defined as ejection fraction less than 50%). The only factor that showed significant association with LV dysfunction was the number of affected segments with noncompaction ( $P = 0.008$ ). Reduced ejection fraction was not associated with either age or sex ( $P = 0.437$  and  $P = 0.206$ , respectively).

**CONCLUSION:** Based on the result of the current study, it can be suggested that apex of the heart is the most common site of noncompaction and increasing numbers of affected segments might be associated with LV dysfunction.

**Keywords:** Isolated Left Ventricular Noncompaction, Characteristic, Echocardiography

*Date of submission:* 10 Nov 2015, *Date of acceptance:* 25 Apr 2016

#### Introduction

Left ventricular noncompaction (LVNC) is described as the presence of pronounce trabeculation and deep intertrabecular recesses communicating with the ventricular cavity.<sup>1,2</sup> Histopathologic findings of isolated LVNC (ILVNC), obtained intra vitam by endocardial biopsy or postmortem are nonspecific. Either they are reported as normal or as subendocardial fibrosis/fibroelastosis, myocardial fibrosis, myocardial disorganization, myocardial hypertrophy and degeneration, scarring of the myocardium, or signs of inflammation.<sup>3</sup> This phenomenon was initially considered as a concomitant pathology occurring along with other congenital heart abnormalities such as pulmonary and aortic atresia, and ventricular septal defects.<sup>3-5</sup> Therefore, ILVNC, in

the absence of other cardiac anomalies, was thought to be very rare and the prevalence of the isolated form has been reported to be as low as 0.3% in the adult population.<sup>6</sup> It appears that ILVNC is a morphologic abnormality with genetic heterogeneity, which involves the mutation of G4.5 gene encoding a protein. In recent decades, owing to the availability of modern imaging modalities, ILVNC has been visualized by computed tomography and magnetic resonance imaging in addition to echocardiography.<sup>4</sup> However, echocardiography is the most commonly used imaging modality for the diagnosis of LVNC. It has been postulated that the malformation is caused by intrauterine arrest of physiologic processes involved in the morphogenesis of myocardium that leads to an alteration of myocardial wall.<sup>7,8</sup>

1- Professor, Cardiovascular Research Center, Mashhad University of Medical Sciences, Mashhad, Iran

2- Cardiologist, Cardiovascular Research Center, Mashhad University of Medical Sciences, Mashhad, Iran

3- General Practitioner, Department of Medical Sciences, Mashhad Branch, Islamic Azad University, Mashhad, Iran

4- General Practitioner, Cardiac Rehabilitation Research Center, Cardiovascular Research Institute, Isfahan University of Medical Sciences, Isfahan AND Student Research Committee, Mashhad University of Medical Sciences, Mashhad, Iran

Correspondence to: Pouya Nezafati, Email: pouya.nezafati@gmail.com

Although the ILVNC was first described in eight cases by Chin et al.,<sup>7</sup> still there is no consensus among researchers and cardiologists about its classification, diagnosis, and definition. In this regard, the World Health Organization and the European Society of Cardiology categorized LVNC as an unclassified cardiomyopathy in 1995 and 2008, respectively.<sup>9,10</sup> American Heart Association, on the other hand, has considered it as a distinct primary cardiomyopathy in its statement published in 2006.<sup>8</sup> Currently, there are three different echocardiographic diagnostic criteria available that might not lead to single diagnosis in one patient suspected for having the disease.<sup>7,11-13</sup>

Based on the available data, our knowledge about this disease and its clinical features is sparse. Therefore, this study was conducted to assess the clinical and echocardiographic characteristics of patients with ILVNC.

### Materials and Methods

A cross-sectional descriptive study was conducted to assess all patients with ILVNC between 2010 and 2013 in Mashhad, Iran. Study recruitment was performed among patients with suspected diagnosis of dilated cardiomyopathy who were referred to a tertiary referral center affiliated with Mashhad University of Medical Sciences. All participants were asked to fill a questionnaire regarding the demographic information, their symptoms, and family history of heart disease. In addition, all patients underwent electrocardiogram (ECG). Patients who had no exclusion criteria were enrolled and underwent echocardiography to diagnose cases with ILVNC. Exclusion criteria were as follows: history of coronary heart disease, hypertension, systemic illnesses, and primary organ failure. Study protocol was in accordance with the latest declaration of Helsinki for investigating on human subjects and it was approved by local ethics committee. Written informed consent was obtained from all patients prior to enrollment.

All patients underwent comprehensive transthoracic two-dimensional and Doppler echocardiography using a System Five or Vivid 7 echocardiograph (GE Medical Systems) by a single expert cardiologist. Biplane area length method was employed to calculate left ventricular ejection fraction (LVEF). Measurements of left ventricular end-diastolic (LVED) and left ventricular end-systolic (LVES) dimension were obtained in accordance with the recommendations of the American Society of Echocardiography.<sup>4</sup> Also, right

ventricle (RV) function was obtained from Tricuspid Annular Plane Systolic Excursion (TAPSE). RV dysfunction was considered as TAPSE less than 16 mm.

### Diagnostic criteria for ILVNC

Patients were considered to have ILVNC if all the following conditions were fulfilled: two-layer myocardial structures were detected with the thin compacted layer and a thick non-compacted layer, absence of co-existing cardiac structural abnormalities, more than three excessively prominent trabeculations and deep intratrabecular recesses, and the ratio of end systolic diameter of noncompacted to compacted layer at parasternal short axis views > 2 in adults and > 1.4 in children.<sup>11</sup>

SPSS software (version 20.0, SPSS Inc., Chicago, IL, USA) was employed to perform all statistical analyses. Descriptive data were demonstrated as mean and standard deviation, while categorical variables were presented as percentage. Chi-square test was employed to compare categorical variables. Normality of data was checked by Kolmogorov-Smirnov test (K-S test). The number of affected segments' differences between the two groups of normal LV function and low LV function was evaluated using Mann-Whitney test. Significance level was considered as P value lower than 0.05 in all the tests.

### Results

Among 4540 subjects who underwent echocardiography, final diagnoses of ILVNC were made in 42 patients. Mean age of patients was  $32.9 \pm 15.6$  ranging from 9 to 70 years. Study group comprised of 26 (61.9%) men and 16 (38.1%) women. The most common symptom was shortness of breath that was reported by 20 (47.6%) of patients, while 11 (26.2%) were asymptomatic. Based on New York Heart Association (NYHA) classification, 25 (59.5%) participants were considered as NYHA class I/II. Only four patients had documented history of left ventricular noncompaction disease in their first-degree family members. Baseline characteristics and ECG of the study sample are demonstrated in table 1.

Thirty-six (85.7%) had an abnormal ECG. Abnormalities included left bundle branch block (LBBB) (n = 18, 43%), poor R wave progression (n = 7, 17%), ST-segment change (n = 6, 14%) and T-wave inversion (n = 5, 12%). Also, four patients were in atrial fibrillation at the time of diagnosis.

**Table 1.** Demographic and clinical characteristics of study group

Variables	N = 42
Mean age (mean $\pm$ SD)	32.9 $\pm$ 15.6
Gender [n(%)]	
Male	26 (61.9)
Female	16 (38.1)
NYHA class [n(%)]	
I/II	25 (59.5)
III/IV	17 (40.5)
Symptoms [n(%)]	
Asymptomatic	11 (26.2)
Shortness of breath	20 (47.6)
Chest pain	11 (26.2)
Abnormal ECG [n(%)]	36 (85.7)
Family history of heart disease [n(%)]	
Positive	4 (9.5)
Negative	38 (90.5)

NYHA: New York Heart Association; ECG: Electrocardiogram; SD: Standard deviation

Ten (23.8%) patients had ventricular tachyarrhythmia, which were candidates to receive implantable cardioverter defibrillators (ICDs). Moreover, no embolic events were detected.

**Table 2.** Echocardiographic features of study participants

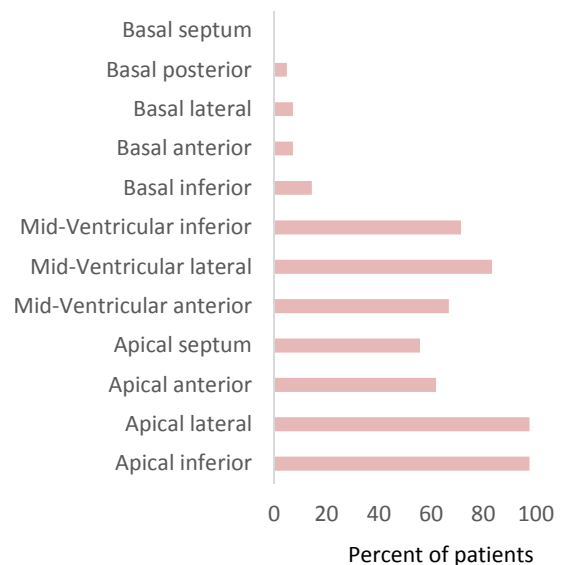
Variables	Mean $\pm$ SD
Ejection Fraction (%)	38.4 $\pm$ 14.70
Left ventricle	
End-systolic volume (cc/m <sup>2</sup> )	32.0 $\pm$ 18.60
End-systolic diameter (mm/m <sup>2</sup> )	21.2 $\pm$ 5.75
End-diastolic volume (cc/m <sup>2</sup> )	53.0 $\pm$ 18.10
End-diastolic diameter (mm/m <sup>2</sup> )	27.4 $\pm$ 5.29
Pulmonary artery pressure (mmHg)	38.7 $\pm$ 16.20
Left atrium size (mm)	43.8 $\pm$ 15.90
Right ventricle diameter (mm)	30.0 $\pm$ 2.32
TAPSE (mm)	18.5 $\pm$ 3.61
S' (cm/sec)	11.8 $\pm$ 2.24

SD: Standard deviation; TAPSE: Tricuspid annular plane systolic excursion; S': Peak systolic annular velocity

Echocardiographic features including end-systolic diameter (ESD), end-systolic volume (ESV),

end-diastolic diameter (EDD) and end-diastolic volume (EDV) of left ventricle, pulmonary artery pressure (PAP), and left atrium and right ventricle sizes are shown in table 2. Details regarding valvular regurgitations and insufficiencies and their severity are presented in table 3. The most common site of noncompacted layers were the lateral and inferior segments of apex (97.6%) (Figure 1).

A total of 16 (38.1%) patients had normal or near normal LV function (LVEF > 50%) and 26 (61.9%) had LVEF lower than 50%. No significant differences were observed between patients with and without LV dysfunction regarding age (30.3 vs. 34.4,  $P = 0.4$ ) and sex distribution (male to female ratio 3:1.16,  $P = 0.2$ ). Mean value of LVEF was  $38.4 \pm 14.7$  ranging from 15 to 60 percent. The factor that showed significant association with LV dysfunction was the number of affected segments of the heart by noncompacted layers. Patients with normal LV function (EF > 50) had a mean of  $3.37 \pm 1.62$  affected segments, while the corresponding figure in the other group (EF < 50) was  $6.76 \pm 2.01$  ( $P = 0.008$ ). Also, RV dysfunction was revealed in eight (19%) patients.

**Figure 1.** Distribution of the noncompacted segments**Table 3.** Frequencies and severities of valvular regurgitation and insufficiency among study population

Severity of valvular regurgitation	Mitral regurgitation	Tricuspid regurgitation	Aortic insufficiency	Pulmonary insufficiency
Severe	9 (21.40)	1 (2.4)	0 (0.0)	1 (2.4)
Moderate	4 (9.52)	14 (33.3)	3 (7.1)	4 (9.5)
Mild	20 (47.60)	26 (61.9)	2 (4.8)	33 (78.6)
Trace	8 (19.00)	1 (2.4)	7 (16.7)	0 (0.0)
Absence	1 (2.39)	0 (0.0)	30 (71.4)	4 (9.5)

Data are shown as number (percent)

## Discussion

In the current study, clinical and echocardiographic characteristics of a group of patients with ILVNC was reported. Subjects were patients with suspected dilated cardiomyopathy who were referred to our center for diagnosis, management and follow-up. The study group was mostly comprised of female patients and the most common symptom was shortness of breath. Mild valvular insufficiencies or regurgitations were observed in most of the patients. Shortness of breath was the most common symptom and 59.5% of patients were categorized as NYHA I/II. Similar findings were demonstrated by Oechslin et al. that reported 65% of patients with ILVNC had dyspnea classified as NYHA I/II.<sup>14</sup>

It is worth noting that prominent trabeculation can be seen in 68% of healthy hearts, but the ratio between noncompacted and compacted parts never reaches 2.<sup>15</sup> As suggested in previous studies, we used the cut-off value of 2 and 1.4 for adults and children, respectively to correctly identify patients with ILVNC.<sup>11</sup>

The most frequent site of trabeculation was the apex of LV (97.6%), which is in accordance with the results of previous articles published on this subject.<sup>14,16,17</sup> Additionally, this emphasizes the accuracy of considering the presence of trabeculation in apex of the heart as the diagnostic criteria. In contrast, diffuse trabeculation of myocardial wall indicates secondary pathologies such as arterial hypertension or valvular disease, compared to segmented trabeculation and noncompaction that can be seen in ILVNC.

Controversial results have been reported regarding the association between the number of affected segments with noncompaction and the prevalence of LV dysfunction. In a study conducted by Habib et al., a total of 105 patients with ILVNC were reviewed and no correlation was found between the numbers of affected segments and lower LVEF.<sup>16</sup> The same finding was reported by Fazio et al.<sup>17</sup> In contrast to previous reports, Aras et al. showed that the number of segments affected with noncompaction can be an independent predictor of LV dysfunction.<sup>18</sup> The same results were observed in the current study. It can be postulated that with the increasing number of segments incapable of performing normal contraction, the risk of LV dysfunction can increase.

## Conclusion

In conclusion, this report of a series of cases with ILVNC showed that the disease has distinct

echocardiographic patterns and comprehensive evaluation of patients with shortness of breath and cardiomyopathy can lead to a definite diagnosis. Echocardiographic evaluation showed that the apex of the heart is the most common site of noncompacted layers. Additionally, highly affected segments may compromise the heart function and reduce LVEF.

## Acknowledgments

The authors would like to thank all the patients for their cooperation and permission to publish this paper.

## Conflict of Interests

Authors have no conflict of interests.

## References

1. Ichida F. Left ventricular noncompaction. *Circ J* 2009; 73(1): 19-26.
2. Malla R, Sharma R, Rauniyar B, Kc MB, Maskey A, Joshi D, et al. Left ventricular noncompaction. *JNMA J Nepal Med Assoc* 2009; 48(174): 180-4.
3. Stollberger C, Finsterer J. Left ventricular hypertrabeculation/noncompaction. *J Am Soc Echocardiogr* 2004; 17(1): 91-100.
4. Nugent AW, Daubeney PE, Chondros P, Carlin JB, Cheung M, Wilkinson LC, et al. The epidemiology of childhood cardiomyopathy in Australia. *N Engl J Med* 2003; 348(17): 1639-46.
5. Stollberger C, Finsterer J. Trabeculation and left ventricular hypertrabeculation/noncompaction. *J Am Soc Echocardiogr* 2004; 17(10): 1120-1.
6. Ritter M, Oechslin E, Sutsch G, Attenhofer C, Schneider J, Jenni R. Isolated noncompaction of the myocardium in adults. *Mayo Clin Proc* 1997; 72(1): 26-31.
7. Chin TK, Perloff JK, Williams RG, Jue K, Mohrmann R. Isolated noncompaction of left ventricular myocardium. A study of eight cases. *Circulation* 1990; 82(2): 507-13.
8. Maron BJ, Towbin JA, Thiene G, Antzelevitch C, Corrado D, Arnett D, et al. Contemporary definitions and classification of the cardiomyopathies: an American Heart Association Scientific Statement from the Council on Clinical Cardiology, Heart Failure and Transplantation Committee; Quality of Care and Outcomes Research and Functional Genomics and Translational Biology Interdisciplinary Working Groups; and Council on Epidemiology and Prevention. *Circulation* 2006; 113(14): 1807-16.
9. Richardson P, McKenna W, Bristow M, Maisch B, Mautner B, O'Connell J, et al. Report of the 1995 World Health Organization/International Society and Federation of Cardiology Task Force on the

Definition and Classification of cardiomyopathies. *Circulation* 1996; 93(5): 841-2.

10. Elliott P, Andersson B, Arbustini E, Bilinska Z, Cecchi F, Charron P, et al. Classification of the cardiomyopathies: a position statement from the European Society Of Cardiology Working Group on Myocardial and Pericardial Diseases. *Eur Heart J* 2008; 29(2): 270-6.
11. Jenni R, Oechslin E, Schneider J, Attenhofer Jost C, Kaufmann PA. Echocardiographic and pathoanatomical characteristics of isolated left ventricular non-compaction: a step towards classification as a distinct cardiomyopathy. *Heart* 2001; 86(6): 666-71.
12. Stollberger C, Finsterer J, Blazek G. Left ventricular hypertrabeculation/noncompaction and association with additional cardiac abnormalities and neuromuscular disorders. *Am J Cardiol* 2002; 90(8): 899-902.
13. Kohli SK, Pantazis AA, Shah JS, Adeyemi B, Jackson G, McKenna WJ, et al. Diagnosis of left-ventricular non-compaction in patients with left-ventricular systolic dysfunction: time for a reappraisal of diagnostic criteria? *Eur Heart J* 2008; 29(1): 89-95.
14. Oechslin EN, Attenhofer Jost CH, Rojas JR, Kaufmann PA, Jenni R. Long-term follow-up of 34 adults with isolated left ventricular noncompaction: a distinct cardiomyopathy with poor prognosis. *J Am Coll Cardiol* 2000; 36(2): 493-500.
15. Boyd MT, Seward JB, Tajik AJ, Edwards WD. Frequency and location of prominent left ventricular trabeculations at autopsy in 474 normal human hearts: implications for evaluation of mural thrombi by two-dimensional echocardiography. *J Am Coll Cardiol* 1987; 9(2): 323-6.
16. Habib G, Charron P, Eicher JC, Giorgi R, Donal E, Laperche T, et al. Isolated left ventricular non-compaction in adults: clinical and echocardiographic features in 105 patients. Results from a French registry. *Eur J Heart Fail* 2011; 13(2): 177-85.
17. Fazio G, Novo G, Casalicchio C, Di Gesaro G, Sutera L, Grassedonio E, et al. Left ventricular non-compaction cardiomyopathy in children: Is segmental fibrosis the cause of tissue Doppler alterations and of EF reduction? *Int J Cardiol* 2009; 132(2): 278-80.
18. Aras D, Tufekcioglu O, Ergun K, Ozeke O, Yildiz A, Topaloglu S, et al. Clinical features of isolated ventricular noncompaction in adults long-term clinical course, echocardiographic properties, and predictors of left ventricular failure. *J Card Fail* 2006; 12(9): 726-33.

**How to cite this article:** Fazlinezhad A, Vojdanparast M, Sarafan S, Nezafati P. **Echocardiographic characteristics of isolated left ventricular noncompaction.** *ARYA Atheroscler* 2016; 12(5): 243-7.