



## Our first experience in stenting of coarctation of aorta in infants and small children; A case series study

**Mehdi Ghaderian**<sup>(1)</sup> , **Mohammad Reza Sabri**<sup>(2)</sup>, **Alireza Ahmadi**<sup>(1)</sup>, **Sargol Bayat**<sup>(3)</sup>

### Case Series

#### Abstract

**BACKGROUND:** One of the congenital heart defects which can cause severe cardiac symptoms and cardiac failure in early childhood and neonatal duration is coarctation of aorta. Balloon angioplasty or surgical approach could be done for management of these defects. This study aimed to evaluate the efficacy and safety of coarctation stenting to improve the condition of these patients.

**METHODS:** Five patients with severe coarctation of aorta participated in this study. Balloon angioplasty performed for these patients initially. Each of five patients had a gradient decline after the initial balloon angioplasty, and againing gradients increased during the follow-up; then, they were treated by implanting a stent. We used Cook Formula stents for these patients.

**RESULTS:** The pressure gradient decreased in all 5 patients with maximum and minimum reduction of 55 and 35 mmHg; and we had not severe complication during or after the procedure and during the follow-up period.

**CONCLUSION:** Performing a stent in selected small children and infants that have sever and symptomatic coarctation of aorta can be effective and safe in improving patients' clinical state, and preventing surgery.

**Keywords:** Coarctation of Aorta, Stents, Infants

*Date of submission:* 28 Oct. 2018, *Date of acceptance:* 18 Jan. 2019

#### Introduction

One of the congenital heart defects defined as a narrowing or partially closure of the aortic arch or descending aorta, mostly located near the insertion of patent ductus arteriosus (PDA) at the beginning of descending aorta, is coarctation of aorta (CoA).<sup>1</sup> The prevalence is 4 per 10000 live births, represents about 8% of all congenital cardiac anomalies, and is the fourth most common lesion requiring treatment during infancy.<sup>1</sup> CoA may be seen as in combination with other diseases, most commonly left-sided heart diseases such as bicuspid aortic valve and ventricular septal defect, or in isolation form. CoA can be presented at any age, but mostly presents in infancy or early childhood because of opportunities of its symptoms such as heart failure. In severe and critical patients, during the early life period, the severity of the narrowing may be seen such as in the physiology of the interrupted aortic

arch; in such case, the baby's life is mostly related to the functioning and opening of the PDA. In these patients, continuous prostaglandin infusion could be helpful in opening the ductus arteriosus prior to doing appropriate treatment as soon as possible. After childhood or during the life, the patient may face with hypertension, and CoA diagnosis may be missed until that time. Untreated patients have shorter long-life than normal population, and may die during third-fourth decades of their life. The most prevalent reasons of death are bacterial endocarditis, intracranial hemorrhage, and heart failure.<sup>1</sup>

**How to cite this article:** Ghaderian M, Sabri MR, Ahmadi A, Bayat S. **Our first experience in stenting of coarctation of aorta in infants and small children; A case series study.** ARYA Atheroscler 2019; 15(2): 93-8.

1- Associate Professor, Pediatric Cardiovascular Research Center, Cardiovascular Research Institute, Isfahan University of Medical Sciences, Isfahan, Iran

2- Professor, Pediatric Cardiovascular Research Center, Cardiovascular Research Institute, Isfahan University of Medical Sciences, Isfahan, Iran

3- Student of Medicine, Pediatric Cardiovascular Research Center, Cardiovascular Research Institute, Isfahan University of Medical Sciences, Isfahan, Iran

Correspondence to: Mehdi Ghaderian, Email: [ghader\\_45@yahoo.co.uk](mailto:ghader_45@yahoo.co.uk)

Different treatments were suggested for the CoA during the past years. Crafoord described surgical approach of the CoA repair.<sup>2</sup> Surgical approach of CoA in young children has good results and low risk of reoperation, even in pediatrics with low body weights.<sup>3</sup> There are many surgical procedures suggested for repair of CoA, such as end-to-end anastomosis and subclavian artery patch technique, and each of these methods has advantages and disadvantages. To manage discrete CoA, an alternative approach named balloon angioplasty (BA) was suggested; it is less invasive, has much less complication, and has been used since 1982 to treat CoA. For recoarctation after surgical method compared to native CoA, because of lower mortality and morbidity and higher success rate, BA is more accepted among interventionists.<sup>4-7</sup> BA approach includes inflation and expansion of the inserted balloon in constricted segment zone, and results in tearing and mild rupture of the media and intima layers of the aorta. In long segment form of CoA or hypoplasia of aortic arch, compared to simple form of CoA, less arbitrary results have been reported. Complications such as arterial injury or other vessel sites, restenosis of the aortic wall, and aneurysm formation after CoA zone were reported after BA.<sup>8,9</sup>

Use of balloon-expandable or self-expandable stents is an acceptable alternative management for CoA in older patients. Stents can decrease aneurysm formation in descending aorta and restenosis related to arterial structure, and diminish the gradient pressure of CoA zone to less than 5-10 mmHg.<sup>8,9</sup> The indications of using stents for CoA are generally as long-segment CoA, an aneurysm formation after previous therapies, tortuosity of aortic arch or descending aorta, recurrent of CoA, and associated severe narrowing or hypoplasia of aortic arch.<sup>10</sup> The use of stent is recommended for patients that have at an older age and weighing more than 20 kg. Using stents in small children or infant have been reported in few studies.<sup>11</sup>

This study aimed to evaluate the efficacy and safety of coarctation stenting for long segment or recurrent CoA in infants and small children referred to Shahid Chamran hospital affiliated to Isfahan University of Medical Sciences, Isfahan, Iran.

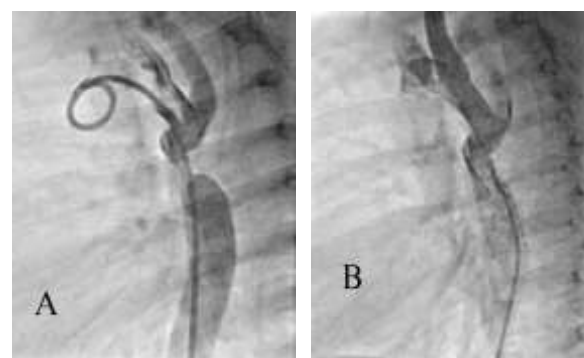
### Materials and Methods

Five patients with long segment form of CoA or discrete CoA (recoarctation after previous balloon angioplasty) underwent stenting of CoA between May 2017 and May 2018 at Shahid Chamran

cardiovascular heart center. Detailed explanations were provided for the patients' parents, and the procedures were done with their complete consent. This study was approved by the Ethics Committee of Isfahan University of Medical Sciences with the code of IR.MUI.MED.REC.1397.159.

4 patients were boys and 1 was girl. At the first procedure, the age and body weight ranged from 1 to 2 months and 3 to 5 kg, respectively. One of them had 2 times balloon angioplasty before stent implantation, and others had one time. Initially, all patients were completely examined by the pediatric cardiologist. For complete evaluation, echocardiography, chest radiography, and 12-lead electrocardiogram (ECG) were done before procedure.

The procedures were performed under general anesthesia or deep sedation with 3-5 mg/kg ketamine and 0.1-0.2 mg/kg midazolam, which repeated every 5-10 minutes depending on the patient's condition. Anticoagulation with heparin (50-100 U/kg) was maintained throughout the procedure. Appropriate antibiotic (mostly cefazoline) was prescribed to the patient during the procedure, and was continued for 24 hours after it. Vascular balloon-expandable stents (Cook Formula Blomington, IN, USA) were used in all patients. We used a radial sheath No. 5 French to prevent arterial injury. We marked the CoA zone on the cath lab's monitor using the pen, and after that, the stent moved to relevant place over the wire without using long sheath. When the stent was positioned in appropriate place, the balloon was inflated and dilated the stent up to 6-8 mm (Figure 1). The gradient before and after procedures were measured.



**Figure.1** Lateral injection in descending aorta before (A) and after (B) coarctation stenting

After procedure, radio-contrast agent was injected for evaluation and imaging of the anatomy. No damage and side effect was seen at site of procedure. Echocardiography and Doppler echocardiography were performed one day before

**Table 1.** Clinical data of studied patients

Patients	Sex	Age 1	Long segment CoA	Age 2	BW1 (kg)	BW2 (kg)	Balloon size (mm)	Stent size (mm)
1	Boy	25 days	-	4 months	3	6	7 × 20	17 × 8
2	Boy	2 months	*	9 months	5	7	7 × 20	24 × 7
3	Boy	30 days	*	7 months	4.5	8	7 × 30	24 × 7
4	Girl	35 days	-	24 months	3.5	10	7 × 20	24 × 7
5	Boy	20 days	-	6 months	3	7	6 × 20	17 × 7

CoA: Coarctation of aorta; Age 1: Age at balloon angioplasty; Age 2: Age at CoA stenting; BW 1: Body weight at balloon angioplasty; BW 2: Body weight at CoA stenting

procedure, and one day, one week, one month, three months, and six months after stenting. Pressure gradient less than 5-10 mmHg across the CoA zone, and increasing of 50% in the diameter of the stenosis segment after stent implantation was a successful outcome.

SPSS software (version 22.0, IBM Corporation, Armonk, NY, USA) used for data analysis. Mean  $\pm$  standard deviation (SD) was expressed for the interval data. For paired data, the paired t-test was used to evaluate utilizing statistical significance. P value of less than 0.05 was considered statistically significant.

## Results

5 patients with recoarctation or long segment form of CoA underwent stent implantation (Table 1).

Stenting decreased pressure gradient significantly across the coarctation zone in all 5 patients with a maximum of 55 and a minimum of 35 mmHg (mean of 45 mmHg). A small residual gradient of 5-10 mmHg was remained after stent implantation. Moreover, ejection fraction increased in all patients with a maximum of 28 and a minimum of 5% percent (Table 2). One patient had complete heart block during the first ten minutes after the procedure that changed to 2:1 block for two hours, and finally returned to normal rhythm after procedure.

During stent implantation, immediate dangerous complications such as massive bleeding and blood transfusion, vascular injuries, contrast sensitivity or

need for emergency surgical intervention did not occur. Moreover, delayed complications such as retroperitoneal hematoma due to vascular injury, arterial dissection, aneurysm formation, stents fracture, stents migration, arteriovenous fistulas, and infection were not seen. Deaths related to the procedure was not seen during or after the procedure.

## Discussion

During the early life period, severe CoA could be presented by heart failure, shock, and subsequent other organs failure. Different approaches are recommended for management of CoA and in some patients, the first step is surgical approach. The results are influenced by arch anatomy, additional defects, and comorbidities.<sup>3</sup> An alternative to surgery is balloon angioplasty, and many interventionists and articles confirmed this method for management of this defect.<sup>4,12</sup> Recoarctation is reported in infants treated with balloon dilatation before 6 months of age.<sup>13,14</sup> CoA stenting is a good alternative method in older patients with CoA. Surgical repair is recommended if percutaneous interventional approach is unsuccessful, or in existence of contraindications. In pediatric, because of smaller size of arterial diameter, using stents is limited in older patients. Kang et al. described using the stent in children with body weight of less than 30 kg with a mean weight of 20.8 kg.<sup>15</sup>

**Table 2.** Outcomes after procedure.

Patients	PPG1 (mmHg)	PPG2 (mmHg)	PPG3 (mmHg)	PPG4 (mmHg)	Mean difference of pressure	P	EF1 (%)	EF2 (%)	Mean difference of ejection fraction	P
1	40	10	50	10	-0.45 $\pm$ 0.093	< 0.001	45	60	0.014 $\pm$ 0.09	0.025
2	100	15	50	10	(-0.57,-0.33)		62	70	(-0.028,-0.25)	
3	40	10	60	5			40	68		
4	50	20	40	5			60	65		
5	30	5	60	5			50	63		

PPG1: Peak to peak pressure gradient before balloon angioplasty; PPG2: Peak to peak pressure gradient after balloon angioplasty; PPG3: Peak to peak pressure gradient before coarctation stenting; PPG4: Peak to peak pressure gradient after coarctation stenting; EF1: Ejection fraction before coarctation stenting; EF2: Ejection fraction after coarctation stenting

Neonates with severe CoA in critical hemodynamic state have a high risk of surgical treatment. In these babies, the lifesaving emergency interventional treatment using coronary stents is advocated. According to several case reports and published small series, stabilization of clinical condition can be achieved for a few weeks allowing later elective surgical treatment.<sup>16-18</sup>

Use of low-profile stents were described by Grohmann et al. in 4 patients with low weight that had the average weight of 3.8 kg, and long-term follow-up did not reported side effects.<sup>11</sup> The results and follow-up of using stents in sick and low-weight infants with contraindication for surgical approach also was reported by Al-Ata et al.<sup>16</sup> and Arfi et al.<sup>19</sup>

Stegeman et al. based on a study of 4 very low birth weight (VLBW) infants reported that coronary stent implantation in VLBW neonates with severe CoA was a safe management, and could be a bridging approach to surgical management when prostaglandin therapy failed, and the patients had not good condition. Recoarctation and mortality had lower rates in this two-steps management compared to surgical method or BA.<sup>20</sup>

Gendera et al. published retrospective analysis of implantation of balloon-expandable stents for recoarctation in small children, based on experience of two centers. Immediate, early, and midterm results were reported in 34 patients, treated for recoarctation. All the stenting procedures were successful, and resulted in significantly diminished systolic gradient from a median of 31 to 0 mmHg before and after stenting, respectively, with a concomitant increase of the stenotic segment diameter of the aorta from a median of 3 to 7 mm.<sup>21</sup>

Mohan et al. described effectiveness and facility of stent using for CoA in young children. When stents were used in small children because of short diameter of aorta and not reaching to adult size, we must concerns other options, such as not using stents in discrete CoA. This study on 60 patients confirmed safety and effectiveness of using stents for treatment of CoA in small children, as in larger patients, in the short term.<sup>22</sup>

Re-dilation of the stents can be used as a good option to treat residual CoA from past procedure or to increase narrowing during the life. It seems largely effective and feasible, although such conclusions and recommendations are mostly based on limited experience. On the other hand, based on Cheng et al. study, stenting is usually recommended for a patient older than 10 years or weighing more than 35 kg.<sup>23</sup>

In this study, our patients were selected from patients who had already had a balloon angioplasty procedure, and did not respond to the treatment, or had long segment CoA. In patients with long segment form of CoA, balloon angioplasty is not effective, and these patients are candidates for surgery or stent therapy. Except for one patient that had two time, each of the patients had angioplasty one time in the infancy, and re-admitted with recoarctation. The first procedure was performed for less risky procedures, and in the second stage, CoA stenting was performed because the patients were candidates for surgical approach. The major problem in these patients is the small size of the vessels, which can cause severe complications during or after the procedure. Moreover, with the growth of the children, the vessels grow and need frequent procedures. We used stent to prevent vascular damage without using a long sheath. We used a vascular balloon-expandable stent which had the ability to dilate up to double primary size during the time. The used stents were up to 16 mm in diameter to be opened and this property, along with other collaterals, could be benefit for the patients and could help us to prevent surgery during the life. Mean duration of follow-up period in our patients was 12 months. The pressure gradient in our patients decreased after the stent, and did not increase in follow-up until the time of this report. The weight gain of our patients was normal, symptoms of heart failure decreased, and ejection fraction increased. Unlike previous studies, in this study we did not use stent at the first stage, and after balloon angioplasty, CoA stenting was performed at the next levels. We did not see particular complications in the follow-up period. In the future, due to the growth of patients, there is need to increase the diameter of the stents, and manage other complications if occurred.

**Limitations:** Each center has a few number of these patients, and does not allow for detailed conclusions, so it is recommended to design a multicenter study or a study with larger sample for better results. Longer follow-up is required to better determine the outcome. With regard to infant's vascular size, this procedure can be complicated in VLBW children. Due to the elegance of stents, we may see stent fractures in the future, and may need for more procedures such as using other stents. The design of better stents for these complications is necessary in the future.

## Conclusion

During neonatal and infancy period, surgical

approach and BA in patients with CoA may have some complications. Due to these complications, the use of stents that have the ability of re-dilation in carefully selected patients such as recoarctation of aorta or long segment CoA could be in mind after primary treatment, and may be an alternative way in these patients with safety and efficacy.

### Acknowledgments

We have special thanks to the staff of Shahid Chamran hospital and also to Isfahan University of Medical Sciences for support of this study.

### Conflict of Interests

Authors have no conflict of interests.

### References

- Mortazaeian H, Moghadam MY, Ghaderian M, Davary PN, Meraji M, Mohammadi AS. Evaluation of exercise-induced hypertension post endovascular stenting of coarctation of aorta. *J Tehran Heart Cent* 2010; 5(3): 137-40.
- Kvitting JP, Olin CL. Clarence Crafoord: A giant in cardiothoracic surgery, the first to repair aortic coarctation. *Ann Thorac Surg* 2009; 87(1): 342-6.
- McElhinney DB, Yang SG, Hogarty AN, Rychik J, Gleason MM, Zachary CH, et al. Recurrent arch obstruction after repair of isolated coarctation of the aorta in neonates and young infants: Is low weight a risk factor? *J Thorac Cardiovasc Surg* 2001; 122(5): 883-90.
- Ghaderian M, Gheysari M. Medium term follow up treatment of severe native coarctation of aorta using of balloon angioplasty in young infants less than one year's age. *J Cardiol & Cardiovasc Ther* 2016; 2(1): 555580.
- Fawzy ME, Fathala A, Osman A, Badr A, Mostafa MA, Mohamed G, et al. Twenty-two years of follow-up results of balloon angioplasty for discrete native coarctation of the aorta in adolescents and adults. *Am Heart J* 2008; 156(5): 910-7.
- Reich O, Tax P, Bartakova H, Tomek V, Gilik J, Lisy J, et al. Long-term (up to 20 years) results of percutaneous balloon angioplasty of recurrent aortic coarctation without use of stents. *Eur Heart J* 2008; 29(16): 2042-8.
- Hellenbrand WE, Allen HD, Golinko RJ, Hagler DJ, Lutin W, Kan J. Balloon angioplasty for aortic recoarctation: Results of Valvuloplasty and Angioplasty of Congenital Anomalies Registry. *Am J Cardiol* 1990; 65(11): 793-7.
- Wheatley GH 3<sup>rd</sup>, Koullias GJ, Rodriguez-Lopez JA, Ramaiah VG, Diethrich EB. Is endovascular repair the new gold standard for primary adult coarctation? *Eur J Cardiothorac Surg* 2010; 38(3): 305-10.
- Haji Zeinali AM, Sadeghian M, Qureshi SA, Ghazi P. Midterm to long-term safety and efficacy of self-expandable nitinol stent implantation for coarctation of aorta in adults. *Catheter Cardiovasc Interv* 2017; 90(3): 425-31.
- Rao PS. Stents in the management of congenital heart disease in pediatric and adult patients. *Indian Heart J* 2001; 53(6): 714-30.
- Grohmann J, Sigler M, Siepe M, Stiller B. A new breakable stent for recoarctation in early infancy: Preliminary Clinical Experience. *Catheter Cardiovasc Interv* 2016; 87(4): E143-E150.
- Hassan W, Awad M, Fawzy ME, Omrani AA, Malik S, Akhras N, et al. Long-term effects of balloon angioplasty on left ventricular hypertrophy in adolescent and adult patients with native coarctation of the aorta. Up to 18 years follow-up results. *Catheter Cardiovasc Interv* 2007; 70(6): 881-6.
- He L, Liu F, Wu L, Qi CH, Zhang LF, Huang GY. Percutaneous balloon angioplasty for severe native aortic coarctation in young infants less than 6 months: Medium- to long-term follow-up. *Chin Med J (Engl)* 2015; 128(8): 1021-5.
- Liang CD, Su WJ, Chung HT, Hwang MS, Huang CF, Lin YJ, et al. Balloon angioplasty for native coarctation of the aorta in neonates and infants with congestive heart failure. *Pediatr Neonatol* 2009; 50(4): 152-7.
- Kang SL, Tometzki A, Taliotis D, Martin R. Stent Therapy for Aortic Coarctation in Children <30 kg: Use of the Low Profile Valeo Stent. *Pediatr Cardiol* 2017; 38(7): 1441-9.
- Al-Ata J, Arfi AM, Hussain A, Kouatly A, Galal MO. Stent angioplasty: An effective alternative in selected infants with critical native aortic coarctation. *Pediatr Cardiol* 2007; 28(3): 183-92.
- Francis E, Gayathri S, Vaidyanathan B, Kannan BR, Kumar RK. Emergency balloon dilation or stenting of critical coarctation of aorta in newborns and infants: An effective interim palliation. *Ann Pediatr Cardiol* 2009; 2(2): 111-5.
- Sreeram I, Sreeram N, Bennink G. Palliative stent implantation for coarctation in neonates and young infants. *Ann Pediatr Cardiol* 2012; 5(2): 145-50.
- Arfi AM, Galal MO, Kouatly A, Baho H, Abozeid H, Al AJ. Stent angioplasty for critical native aortic coarctation in three infants: Up to 15-year follow-up without surgical intervention and review of the literature. *Pediatr Cardiol* 2018; 39(8): 1501-13.
- Stegeman R, Breur JMPJ, Heuser J, Jansen NJG, de Vries WB, Vijlbrief DC, et al. Primary coronary stent implantation is a feasible bridging therapy to surgery in very low birth weight infants with

- critical aortic coarctation. *Int J Cardiol* 2018; 261: 62-5.
- 21.** Gendera K, Ewert P, Tanase D, Georgiev S, Genz T, Bambul HP, et al. Balloon-expandable stents for recoarctation of the aorta in small children. Two centre experience. *Int J Cardiol* 2018; 263: 34-9.
- 22.** Mohan UR, Danon S, Levi D, Connolly D, Moore JW. Stent implantation for coarctation of the aorta in children <30 kg. *JACC Cardiovasc Interv* 2009; 2(9): 877-83.
- 23.** Cheng HT, Lin MC, Jan SL, Fu YC. Endovascular stent for coarctation of the aorta in a child and review of the literature. *Pediatr Neonatol* 2011; 52(4): 237-9.