

## A rare case of stenting of spontaneous dissection of Shepherd's Crook right coronary artery

**Laxman Dubey<sup>(1)</sup>**

### Case Report

#### Abstract

**BACKGROUND:** Spontaneous coronary artery dissection (SCAD) is a rare cause of acute coronary syndrome (ACS) and sudden death. It usually occurs in young women during the peripartum period; however, it had also been reported in older aged males having risk factors for atherosclerotic coronary artery disease.

**CASE REPORT:** This case describes a 69-year-old male patient who presented with manifestations of ACS due to a spontaneous dissection of the Shepherd's Crook right coronary artery (RCA), which was successfully managed with percutaneous coronary intervention (PCI) and stenting. At the 6<sup>th</sup> month follow-up, the patient remained chest pain free.

**CONCLUSION:** Patients with SCAD in the presence of ongoing ischemia can be treated with PCI and stenting.

**Keywords:** Acute Coronary Syndrome, Percutaneous Coronary Intervention, Shepherd's Crook Right Coronary Artery, Spontaneous Coronary Artery Dissection

*Date of submission:* 16 Apr 2013, *Date of acceptance:* 2 Oct 2013

#### Introduction

Spontaneous coronary artery dissection (SCAD) is a rare but important cause of acute coronary syndrome (ACS). The spectrum of clinical presentation can range from unstable angina, acute myocardial infarction, and sudden death.<sup>1-3</sup> The population-based incidence of SCAD is unknown; however, the overall incidence of SCAD in angiographic series has been reported to 0.1–1.1%.<sup>4</sup> The exact etiological mechanism of SCAD remains unclear. There is a female preponderance and tendency to occur in pregnancy, making a hormonal influence likely. SCAD had also been reported in older aged males having risk factors for atherosclerotic coronary artery disease. This case highlights a 69-year-old male patient who presented with manifestations of ACS due to a spontaneous dissection of the Shepherd's Crook right coronary artery (RCA), which had been rarely reported in the literature. Patient was managed successfully with percutaneous coronary intervention (PCI) and stenting of the RCA.

#### Case Report

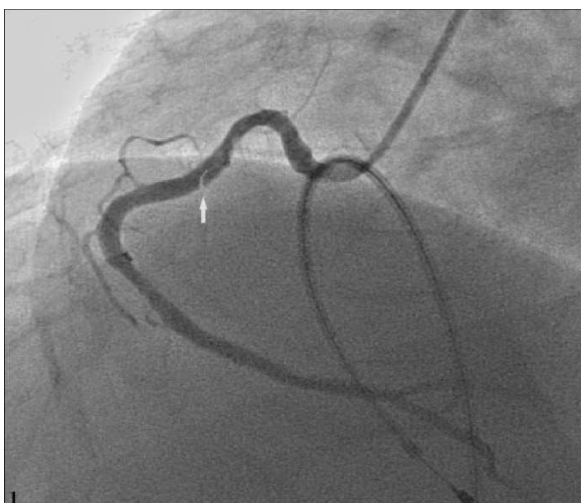
The case we present here is about a 69-year-old male patient who presented to our hospital with

substernal chest pain associated with shortness of breath of 10 days duration and one episode of loss of consciousness one day back. The patient denied chest trauma, fever, or chills. He was a past smoker and taking medicines for systemic hypertension, type-2 diabetes mellitus, and long-standing atrial fibrillation. He was on aspirin, atorvastatin, atenolol, amlodipine, and metformin. In the emergency room, his systolic blood pressure was found to be of 170/90 mmHg with heart rate of 45 beats/min. Family history was unremarkable for any cardiovascular illness. Patient was conscious with no focal neurological deficit. Physical examination was within normal limits except for a soft systolic murmur at the apex. Complete blood count and serum biochemistry were within normal limits. Electrocardiography showed atrial fibrillation with slow ventricular response and ST segment depression of 3 mm in leads V2 and V6 with T-wave inversion. Laboratory studies did not show any elevation in cardiac enzymes. A computed tomography scan of the head showed normal findings. He was taken to the cardiac catheterization laboratory for the placement of a temporary pacemaker and coronary angiography (CAG).

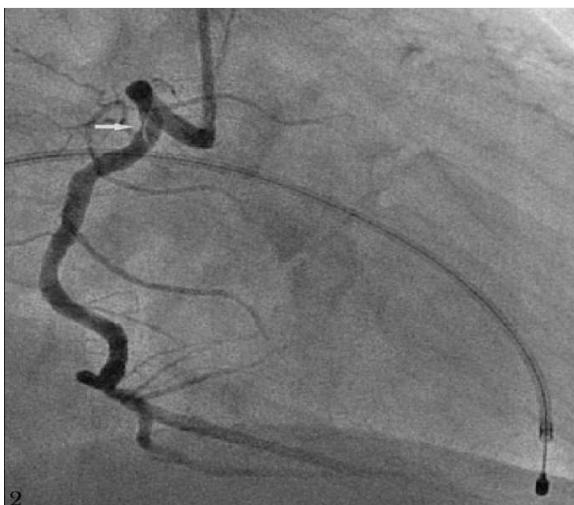Temporary pacemaker was inserted via right

1- Department of Cardiology, College of Medical Sciences and Teaching Hospital, Bharatpur, Chitwan, Nepal  
Correspondence to: Laxman Dubey, Email: dubeylax@yahoo.com

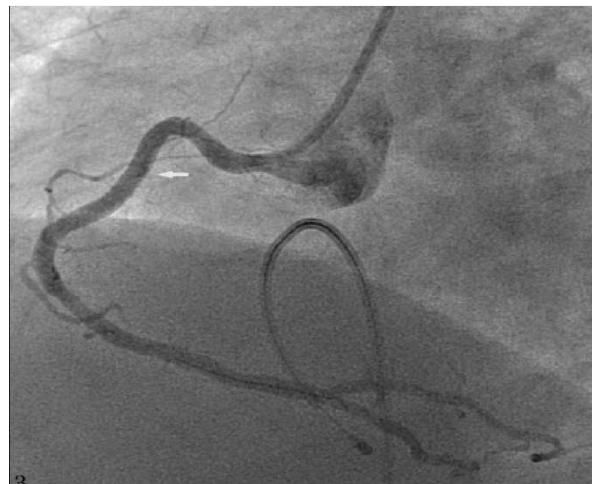
femoral vein and kept in the right ventricle. CAG was performed via right femoral artery approach. Selective cannulation of the left coronary artery revealed a normal left main coronary artery bifurcating into the left anterior descending (LAD) and the left circumflex artery (LCX). There were non-obstructive lesions in the mid-LAD as well as at the first diagonal branch. LCX had minor atherosclerotic plaques. RCA was hooked with Judkins right catheter 3.5 × 6 French (Cordis). Selective cannulation of the RCA revealed a dissection within the proximal segment of an uplifted tortuous (Shepherd's Crook morphology) RCA with the normal flow down the distal vessel (Figures 1 and 2).



**Figure 1.** Coronary angiography in left anterior oblique projection showing Shepherd's Crook right coronary artery with a clear angiographic flap (arrow) indicating dissection



**Figure 2.** Right anterior oblique projection showing clear angiographic flap (arrow) in the right coronary artery



**Figure 3.** Final result after stenting shows disappearance of the dissection (arrow)

The dissection was treated by direct stenting (3.5 mm × 24 mm, Partner Sirolimus Eluting Stent, Lepu Medical), after which the dissection disappeared (Figure 3). Three days later, his heart rate was in a range of 60–70 beats/min and temporary pacemaker was removed. His subsequent stay in the hospital was uneventful and discharged free of symptoms on the 5th day. At 6 month follow-up, patient remained chest pain free.

### Discussion

The earliest report of SCAD was published in 1931 during autopsy findings in a 42-year-old woman who died after presenting with chest pain.<sup>5</sup> SCAD is a relatively uncommon condition that usually presents as an ACS or sudden cardiac death, with a reported mortality of 80%.<sup>6</sup> The reported incidence of SCAD varies from 0.1% to 1.1% by angiography.<sup>4</sup> Until now, approximately 500 cases have been documented in the medical literature due to a significant number of SCAD presenting with sudden death.<sup>7</sup> The Western Denmark Heart registry reported 22 cases of SCAD out of a total of 11,175 ACS patients, and 77% of them were women.<sup>8</sup>

SCAD has been reported most commonly in young women of whom approximately 30% of cases occur in the peripartum period.<sup>9</sup> The increased incidence of SCAD in pregnancy and the postpartum period is thought to be due to decreased collagen production or enhanced degradation in the intima and media of the vessel wall in the postpartum period, increased shear stress on the arterial wall due to augmented cardiac output, inherent hypercoagulability in peripartum

state, and hemorrhagic disruption of vasa vasorum.<sup>10</sup> It may also be associated with autoimmune and collagen vascular diseases, Marfan's syndrome, Ehlers-Danlos syndrome type IV, systemic lupus erythematosus, or intense physical exercise.<sup>11</sup> The presence of an eosinophilic infiltrate in adventitia had also been described, particularly in non-atherosclerotic SCAD.<sup>12</sup> SCAD had also been reported in the older aged males having risk factors for atherosclerotic coronary artery disease,<sup>13</sup> as in our case. Atherosclerosis, coronary vasospasm, and coronary artery ectasia were also thought as the main reasons for dissection. In atherosclerotic arteries, increased density of vasa vasorum due to atherosclerotic plaque may cause bleeding and rupture of nidus that can lead to dissection of adventitia from media and subsequent rupture of intima or primary event is an intimal tear progressing into media by the force of arterial pressure.<sup>13</sup>

The most common localization of involvement is the LAD artery (80%) followed by the RCA; in a few cases the LCX may be affected.<sup>14</sup> CAG is the gold standard in the diagnosis of SCAD; however, other imaging techniques such as computed tomography, magnetic resonance imaging, intravascular ultrasound, and transesophageal echocardiography may be helpful in both the diagnosis and follow-up.<sup>13-15</sup>

Management of SCAD remains controversial and mostly depends on the clinical presentation, location of the dissection, the number of vessels involved, and the coronary flow status; however, there are no guidelines regarding optimal treatment of this condition. PCI and stenting is reasonable in acute cases with proximal dissection with arterial occlusion as well as in cases with an ongoing ischemia in order to restore the coronary perfusion and hemodynamic stability.<sup>14</sup> However, conservative medical therapy is reasonable in cases with no evidence of ongoing ischemia or hemodynamic instability. Surgical revascularization is usually restricted to hemodynamically unstable cases where PCI is failed or not possible.<sup>16</sup>

### Conclusion

SCAD is a rare but a fatal condition, although, commonly reported in young women that do not carry any known risk factors, can be seen in the middle and older aged males having risk factors for atherosclerotic coronary artery disease. PCI may be the treatment of choice in patients with ongoing ischemia. We presented PCI and stenting of

spontaneous dissection of the Shepherd's Crook RCA that had been rarely reported in the literature.

### Conflict of Interests

Authors have no conflict of interests.

### References

1. Vanzetto G, Berger-Coz E, Barone-Rochette G, Chavanon O, Bouvaist H, Hacini R, et al. Prevalence, therapeutic management and medium-term prognosis of spontaneous coronary artery dissection: results from a database of 11,605 patients. *Eur J Cardiothorac Surg* 2009; 35(2): 250-4.
2. Kamineni R, Sadhu A, Alpert JS. Spontaneous coronary artery dissection: report of two cases and a 50-year review of the literature. *Cardiol Rev* 2002; 10(5): 279-84.
3. Mulvany NJ, Ranson DL, Pilbeam MC. Isolated dissection of the coronary artery: a postmortem study of seven cases. *Pathology* 2001; 33(3): 307-11.
4. Oliveira SM, Goncalves A, Dias P, Maciel MJ. Spontaneous coronary artery dissection: a diagnosis to consider in acute coronary syndromes. *Rev Port Cardiol* 2009; 28(6): 707-13.
5. Pretty HC. Dissecting aneurysm of coronary artery in a woman aged 42: Rupture. *Br Med J* 1931; 1: 667.
6. Jorgensen MB, Aharonian V, Mansukhani P, Mahrer PR. Spontaneous coronary dissection: a cluster of cases with this rare finding. *Am Heart J* 1994; 127(5): 1382-7.
7. Kamran M, Guptan A, Bogal M. Spontaneous coronary artery dissection: case series and review. *J Invasive Cardiol* 2008; 20(10): 553-9.
8. Mortensen KH, Thuesen L, Kristensen IB, Christiansen EH. Spontaneous coronary artery dissection: a Western Denmark Heart Registry study. *Catheter Cardiovasc Interv* 2009; 74(5): 710-7.
9. DeMaio SJ, Kinsella SH, Silverman ME. Clinical course and long-term prognosis of spontaneous coronary artery dissection. *Am J Cardiol* 1989; 64(8): 471-4.
10. Appleby CE, Barolet A, Ing D, Ross J, Schwartz L, Seidelin P, et al. Contemporary management of pregnancy-related coronary artery dissection: A single-centre experience and literature review. *Exp Clin Cardiol* 2009; 14(1): e8-e16.
11. Rajendra N, Lim F, Shaukat N. Spontaneous coronary artery dissection presenting as an ischaemic stroke in a middle-aged man with anti-cardiolipin antibodies: a case report. *J Med Case Rep* 2010; 4: 94.
12. Hoyer A. Spontaneous coronary artery dissection: time for a concerted effort to better understand this rare condition. *J Invasive Cardiol* 2010; 22(5): 229-30.
13. Celik SK, Sagcan A, Altintig A, Yuksel M, Akin

M, Kultursay H. Primary spontaneous coronary artery dissections in atherosclerotic patients. Report of nine cases with review of the pertinent literature. *Eur J Cardiothorac Surg* 2001; 20(3): 573-6.

14. Gonzalez JJ, Hill JA, Conti CR. Spontaneous coronary artery dissection treated with percutaneous transluminal angioplasty. *Am J Cardiol* 1989; 63(12): 885-6.
15. Baker CS, Knight C, Deaner A. Images in cardiology: Spontaneous right coronary artery dissection. *Heart* 2002; 88(2): 130.
16. Motreff P, Souteyrand G, Dauphin C, Eschalier R,

Cassagnes J, Lusson JR. Management of spontaneous coronary artery dissection: review of the literature and discussion based on a series of 12 young women with acute coronary syndrome. *Cardiology* 2010; 115(1): 10-8.

**How to cite this article:** Dubey L. A rare case of stenting of spontaneous dissection of Shepherd's Crook right coronary artery. *ARYA Atheroscler* 2014; 10(2): 129-32.