





## Recurrent cardiac and skin myxomas along with acromegaly: A case report of carney complex

Zivar Shirinpour<sup>(1)</sup> , Zahra Farhangyan<sup>(1)</sup> , Nehzat Akiash<sup>(2)</sup>, Homeira Rashidi<sup>(3)</sup>

### Case Report

#### Abstract

**BACKGROUND:** Carney complex (CNC) is an uncommon multisystem endocrine disorder with significant variability of clinical manifestations including mucocutaneous involvement (pigmented lesions, myxomas, blue nevi, etc.), endocrine tumors (adrenal, pituitary, thyroid glands, or testicles), and non-endocrine tumors [cardiac myxomas, psammomatous melanotic schwannomas (PMS), breast myxomas as well as ductal adenomas, and osteochondromyxomas]. To our knowledge, this is the second report of CNC in Iran, presenting with typical manifestations.

**Case Report:** A 29-year-old man was referred to our clinic to evaluate the likelihood of CNC because of recurrent cardiac myxomas. He sometimes suffered from self-limited episodes of non-exertional palpitation, dyspnea, weakness, and pallor. He had some features of acromegaly (such as increase in acral size and frontal bossing). The laboratory tests revealed a high insulin-like growth factor 1 (IGF1) level, with no growth hormone (GH) suppression after oral glucose tolerance test (OGTT). Pituitary magnetic resonance imaging (MRI) showed a microadenoma (5.79 × 2.80 mm) of the pituitary gland; then, he was diagnosed with CNC, having the following major criteria: recurrent cardiac myxomas, skin myxomas, and acromegaly due to GH pituitary microadenoma, as well as minor criteria: multiple café-au-lait (CAL) spots, several skin tags and moles, and thyroid nodules. In this patient, laboratory tests for Cushing's syndrome were equivocal, whereas pheochromocytoma was proven biochemically but unexpectedly pathology did not confirm it. Rather, the pathology of the right adrenocortical specimen revealed nodular hyperplasia.

**CONCLUSION:** For patients with recurrent cardiac myxoma, especially with skin myxoma, the diagnosis of CNC should be considered and the search for other associations should be done even in an asymptomatic patient.

**Keywords:** Carney Complex; Acromegaly; Myxoma

*Date of submission:* 05 Nov. 2019, *Date of acceptance:* 11 Mar. 2020

#### Introduction

Carney complex (CNC) is an uncommon multisystem endocrine disorder first described in 1985 by Dr. J. Aidan Carney,<sup>1</sup> inherited in an autosomal-dominant manner or occurring sporadically due to a de novo genetic defect,<sup>2</sup> and characterized by spotty skin pigmentation in typical distribution, cutaneous/mucosal or cardiac myxoma, breast myxomatosis, primary pigmented nodular adrenocortical disease (PPNAD) or paradoxically positive Liddle's test, acromegaly secondary to growth hormone (GH) adenoma, large-cell calcifying Sertoli cell tumors (LCCSCT), thyroid carcinoma, psammomatous melanotic schwannomas (PMS), multiple epithelioid blue nevi, breast ductal adenoma,

and osteochondromyxoma as major criteria and affected first-degree relative, activating mutations of protein kinase cyclic adenosine monophosphate (cAMP)-activated catalytic subunit alpha and beta (PRKACA and PRKACB), and inactivating mutation of regulatory subunit type I-alpha of protein kinase A (PRKAR1A) gene as supplemental criteria, affecting more than 750 patients distributed in many ethnicities.<sup>3</sup> Inactivating mutations in PRKAR1A gene

**How to cite this article:** Shirinpour Z, Farhangyan Z, Akiash N, Rashidi H. **Recurrent cardiac and skin myxomas along with acromegaly: A case report of carney complex.** ARYA Atheroscler 2020; 16(3): 146-50.

1- Assistant Professor, Diabetes Research Center, Health Research Institute, Ahvaz Jundishapur University of Medical Sciences, Ahvaz, Iran  
2- Assistant Professor, Atherosclerosis Research Center, Ahvaz Jundishapur University of Medical Sciences, Ahvaz, Iran  
3- Associate Professor, Diabetes Research Center, Health Research Institute, Ahvaz Jundishapur University of Medical Sciences, Ahvaz, Iran  
Address for correspondence: Zahra Farhangyan; Assistant Professor, Diabetes Research Center, Health Research Institute, Ahvaz Jundishapur University of Medical Sciences, Ahvaz, Iran; Email: [dr.farhangyan.z@gmail.com](mailto:dr.farhangyan.z@gmail.com)

on chromosome 17q22-24 is present in 70% of the patients.<sup>4</sup> The diagnosis is established in the following situations:<sup>5</sup>

- Exhibiting two or more major criteria
- A pathogenic variant is identified in the PRKAR1A
- Existence of one major and one supplemental criterion

We report a case of CNC presenting with recurrent cardiac and skin myxomas, acromegaly secondary to GH adenoma, and adrenal nodular hyperplasia.

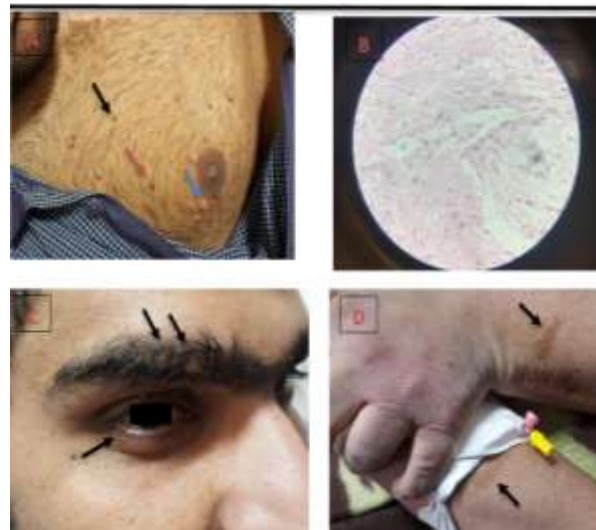### Case Report

A 29-year-old man was referred to our clinic by the cardiologist to evaluate the likelihood of CNC because of recurrent cardiac myxomas. The patient became a candidate for kidney stone surgery by a urologist 2 years ago. In preoperative evaluation according to the previous history of cardiac myxomas, consultation with the cardiologist was requested. Echocardiography revealed a well-defined mobile mass (21 × 19 mm) in left ventricle (LV) and a tag-like mass in opposite part of tumor in anterior LV wall probably beginning of tumor formation; then, the patient was referred to us. He came to our clinic 8 months later (in last year). In history, he sometimes suffered from self-limited episodes of non-exertional palpitation, dyspnea, weakness, and pallor. He denied any headache, fever, weight loss, or sweating.

He had a history of recurrent atrial myxomas in the past 16 years for which he underwent repeated surgeries. At the age of 11, because of dyspnea, anemia, and fever, he was admitted and echocardiography documented a 32 × 32 mm myxoma in left atrium that for which he was operated in the same year, followed by a repeated surgery after 7 years (at 18 years old) for a recurrence (32 × 20 mm left atrial myxoma). He had history of multiple renal calculi. The patient was not on regular follow-up after second surgery till 2 years ago (at 27 years old).

On examination, the patient was obese [body mass index (BMI): 44 kg/m<sup>2</sup>]; his cardiac exam showed normal sinus rhythm at 98 beats per minute (bpm), blood pressure of 160/100 mmHg, and no murmur. The lungs were clear. He had multiple spotty pigmentations (lentigines) (Figure 1A) on his face and trunk. Multiple cutaneous myxomas (confirmed histologically) (Figure 1B) and skin tags were seen on his neck, trunk, and abdomen, and there were also several myxomas on the eyebrows, eyelids (Figure 1C), and nipples. He had frontal skull bossing, a big fleshy nose, and large number of

moles on his skin. Acanthosis nigricans (AN) was present on his neck. Café-au-lait (CAL) spots (Figure 1D) were seen on both forearms and abdomen. Increased acral size was seen. Family history of such illness was negative.



**Figure 1.** A) Multiple spotty pigmentation, mole, and myxoma (black, red, and blue arrow, respectively); B) Pathology of cutaneous myxoma, a sparsely cellular lesion composed of stellate and spindled fibroblast accompanied by abundant small vessels in myxoid matrix; C) Eye and eyebrow myxomas (arrow marks); D) Café-au-lait (CAL) spots

Because of skin lesions and recurrent cardiac myxomas, CNC was suggested, so further evaluation for other associations was performed. Given the hypertension (HTN) and episodic symptoms suspicious of pheochromocytoma, evaluation for pheochromocytoma was performed. Our investigation revealed 24-hour urinary concentration of vanillylmandelic acid (VMA) of 41 mg/day (reference range: up to 4 mg/day), a metanephrine level of 568 µg/day (reference range: up to 350 µg/day), and normetanephrine level of 895 µg/day (reference range: up to 600 µg/day) (these results were repeated in 2 tests on separate days). Evaluation for acromegaly (performed due to the increased acral size, multiple skin tags, and AN) revealed an elevated insulin-like growth factor 1 (IGF1) of 388 ng/ml (reference range: 109-290 ng/ml). The GH level after oral administration of 75 g glucose (0, 30, 60, 90, 120 minutes) was not suppressed below 1 mg/ml. Thus, pheochromocytoma and acromegaly were confirmed biochemically, and dynamic magnetic resonance imaging (MRI) of sella and abdomen (adrenal glands) (Figures 2A, 2B) showed a microadenoma

(5.79 × 2.80 mm) in the superior part of left posterior of the pituitary gland and a 26 × 13 mm mass with minimal enhancement in peripheral rim in medial to right adrenal gland. The left adrenal gland was normal in size and signal intensity.

Laboratory tests for Cushing's syndrome were borderline: baseline (8 am) morning plasma cortisol level of 9.5 µg/dl (reference range: 5-23 µg/dl), 24-hour urinary free cortisol (UFC) level elevated in one test (274 µg/day, reference range: 50-190 µg/day) and normal in another test (121 µg/day), overnight dexamethasone suppression test (DST) result of 2.6 µg/dl (above 1.8 µg/dl), a low-dose DST result of 6.5 µg/dl, a high-dose DST result of 2.7 µg/dl in plasma and 102 µg/day in UFC, and an adrenocorticotrophic hormone (ACTH) level of 15.4 pg/ml (reference range: 7.2-63.0 pg/ml). Prolactin level was slightly high (16.5 ng/ml, reference range: up to 15 ng/ml). Levels of other pituitary hormones were normal. Calcium, phosphorus, and parathyroid hormone were all normal.

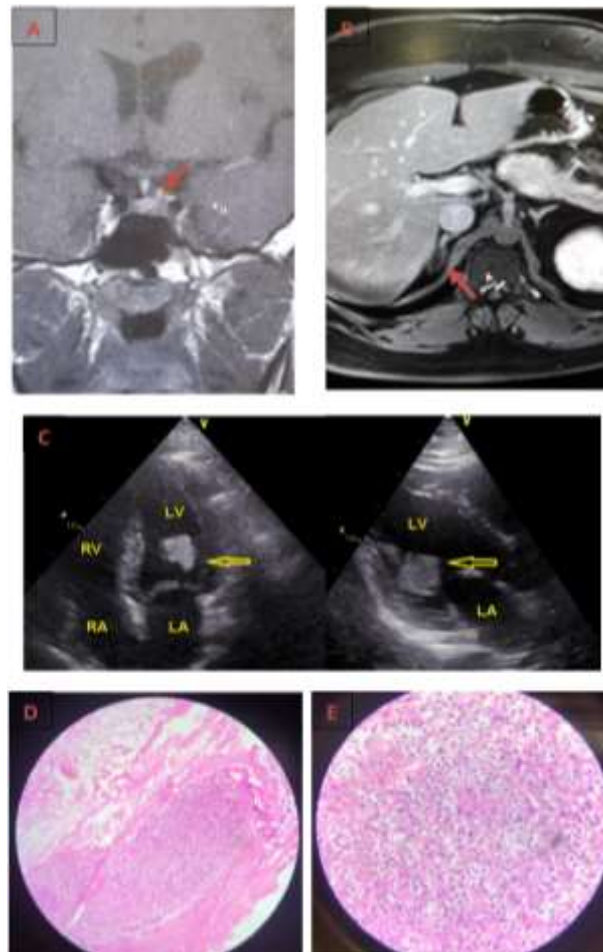
The echocardiography showed a well-defined and homogenous mass in LV attaching to papillary muscles and a small mass opposite the papillary muscles suspicious of benign cardiac tumor (20 × 18 mm) (Figure 2C), and he became a candidate for a heart surgery again.

Thyroid gland ultrasound showed multiple cystic nodules with the largest diameter of 3 mm in right lobe. The patient was euthyroid, and breast ultrasound was normal. However, scrotal ultrasound revealed testicular microlithiasis (TM). Brain MRI was performed according to the radiologist recommendation based on the incidental findings noted in pituitary MRI (some T2 hyperintense lesions in frontoparietal subcortical white matter) that revealed multiple ischemic lesions (lacunar infarct, presumably due to emboli from cardiac myxoma) which were seen in right frontoparietal subcortical white matter and bilateral corona radiata, so anticoagulant therapy was started.

Based on clinical and biochemical findings that were in favor of the pheochromocytoma and MRI report on a medial adrenal nodule, finally laparoscopic right adrenalectomy was performed (after preoperative pharmacologic preparation). The adrenal gland was greater than normal macroscopically. Pathology (reported by two pathologists) revealed nodular hyperplasia with one dominant nodule but unexpectedly, the adrenal medulla did not have any lesion (Figures 2D, 2E).

Two weeks after surgery, the patient's symptoms and signs (HTN and tachycardia) were resolved,

and 24-hour urinary concentration of VMA (3.9 mg/day, reference range: up to 4 mg/day), metanephrine (47.8 µg/day, reference range: up to 350 µg/day), and normetanephrine (551 µg/day, reference range: up to 600 µg/day) were normalized. This discrepancy between biochemistry and pathology remains questionable.



**Figure 2.** A) Pituitary magnetic resonance imaging (MRI), microadenoma; B) Adrenal MRI, showing nodular thickening of medial limb of right adrenal with subtle rim enhancement; C) Transthoracic echocardiography (TTE), showing a wall-defined and homogenous mass in left ventricle (LV) attaching to papillary muscles; D and E) Right adrenal histopathologic specimens [hematoxylin and eosin (H&E)-stained], adrenocortical hyperplasia with well-circumscribed micronodules

The patient refused transsphenoidal surgery (TSS) for pituitary microadenoma and preferred medical treatment [somatostatin analogues (SSA)] to decide on surgery later. He was referred to the cardiac surgery clinic in order for the cardiac surgeon to decide on cardiac myxoma surgery.

Echocardiography was performed on his first-degree family, of whom none had cardiac myxoma.

Unfortunately, despite frequent emphasis by the medical team, the patient did not have regular follow-ups. He came to our clinic one year after the unilateral adrenalectomy, while he was generally good and did not mention any problem. Blood pressure was 110/70 mmHg and pulse rate was 78 bpm. 24-hour urinary fractionated metanephrines, 24-hour UFC, and overnight DST were normal. IGF1 level was 280 ng/ml (reference range: 109-290 ng/ml) and GH level was suppressed below 1 mg/ml after oral administration of 75 g glucose. He did not accept the risk of cardiac re-surgery.

For all lab tests and adrenalectomy, informed consent was taken from the patient.

### Discussion

CNC is a familial autosomal dominant syndrome, involving mesenchymal tumors, spotty skin pigmentation, peripheral nerve, breast and testicular tumors, and GH-secreting pituitary adenoma.<sup>6</sup> We are reporting this case of CNC based on the latest diagnostic criteria mentioned by Correa et al.,<sup>3</sup> with major criteria (cardiac and cutaneous myxomas, GH-producing pituitary adenoma) and minor criteria (several CAL spots, skin tags and moles, and multiple thyroid nodules). To the best of our knowledge, this is the second report of CNC in Iran. In the first case report (published in 2007), Talaei et al. introduced a 27-year-old woman with Cushing's syndrome due to PPNAD and a unilateral adrenocortical adenoma with a pituitary incidentaloma.<sup>7</sup>

Skin lesions in CNC can vary from lentigines and blue nevi to cutaneous myxomas. CAL spots have also been reported. Cutaneous myxomas usually present in the eyelid, external ear canal, nipples, and the genitalia.<sup>3</sup> One of the most common ophthalmologic manifestations is eyelid myxomas.<sup>8</sup> 20%-40% of the patients have cardiac myxomas,<sup>3</sup> around 7% of all cardiac myxomas are associated with CNC.<sup>9</sup> The recurrence rate of myxoma is 20%, and 50% of these cases have more than one myxoma.<sup>10</sup> Most patients have two or more open-heart surgeries because of recurrent myxomas.<sup>11</sup>

The interesting point of our patient is laboratory-proven pheochromocytoma which we did not find any case report indicating the association of CNC with pheochromocytoma in literature. Although the biochemistry was in favor

of pheochromocytoma, the pathology did not confirm it. The reason for the positive results of the pheochromocytoma tests was uncertain.

The incidence of acromegaly due to pituitary adenoma is around 10%-12% in these patients.<sup>3,12</sup> Birla et al. reported a 30-year-old man with CNC syndrome characterized by recurrent atrial myxoma and acromegaly due to a novel 22 bp insertion mutation in PRKAR1A.<sup>13</sup> The PRKAR1A gene evaluation is not recommended for all patients, and our patient was not willing to do it due to financial constraints. The most common endocrine tumor in CNC is PPNAD,<sup>3</sup> that affected 25%-60% of the patients with CNC.<sup>11</sup> Cortisol secretion in PPNAD is usually insidious at onset<sup>9</sup> and may be cyclic or periodic.<sup>3</sup> In our patient, although Cushing's syndrome was not confirmed, given the boundary results of tests and pathological appearance of the right adrenal gland, there is a potential for it to occur and precise follow-up is required.

Up to 60% of all patients may have thyroid nodules<sup>11</sup> and 75% of the cases have cystic disease.<sup>3</sup> Hamza et al. reported a case of CNC, a 35-year-old patient diagnosed with Cushing's syndrome (due to primary pigmented nodular adrenal disease) and thyroid carcinoma.<sup>14</sup> In our patient, due to small size of thyroid nodules, fine needle biopsy was not performed, but serial thyroid examination and ultrasound are required.

More than 75% of men with CNC may have LCCSCT.<sup>3</sup> TM was reported in our patient's ultrasound. The relationship between TM and testicular malignancy is controversial.<sup>15</sup> Liu et al. reported a 16-year-old boy with CNC who had multiple microcalcifications of the bilateral testes.<sup>16</sup> According to one study, the incidence of testicular germ cell tumor (GCT) or germ cell neoplasia in situ (GCNIS) was significantly increased in 1347 men with TM compared with those in whom TM was absent.<sup>17</sup>

Close follow-up is suggested for clinical manifestations of the disease (at least yearly), including echocardiography, regular skin evaluation, measurement of UFC and other tests for screening Cushing's syndrome, blood test for GH, IGF1, and prolactin, and imaging such as testicular, thyroid, and breast ultrasound as well as pituitary and brain MRI, if appropriate.

### Acknowledgments

We would like to thank Dr. Mouod Sabbagh for help in histopathological reports.

**Conflict of Interests**

Authors have no conflict of interests.

**References**

1. Carney JA, Gordon H, Carpenter PC, Shenoy BV, Go VL. The complex of myxomas, spotty pigmentation, and endocrine overactivity. *Medicine (Baltimore)* 1985; 64(4): 270-83.
2. Stratakis CA, Kirschner LS, Carney JA. Clinical and molecular features of the Carney complex: diagnostic criteria and recommendations for patient evaluation. *J Clin Endocrinol Metab* 2001; 86(9): 4041-6.
3. Correa R, Salpea P, Stratakis CA. Carney complex: An update. *Eur J Endocrinol* 2015; 173(4): M85-M97.
4. Kirschner LS, Carney JA, Pack SD, Taymans SE, Giatzakis C, Cho YS, et al. Mutations of the gene encoding the protein kinase a type I-alpha regulatory subunit in patients with the Carney complex. *Nat Genet* 2000; 26(1): 89-92.
5. Almeida MQ, Stratakis CA. Carney complex and other conditions associated with micronodular adrenal hyperplasias. *Best Pract Res Clin Endocrinol Metab* 2010; 24(6): 907-14.
6. Nieman LK, Biller BM, Findling JW, Newell-Price J, Savage MO, Stewart PM, et al. The diagnosis of Cushing's syndrome: An endocrine society clinical practice guideline. *J Clin Endocrinol Metab* 2008; 93(5): 1526-40.
7. Talaei A, Aminorroaya A, Taheri D, Mahdavi KN. Carney complex presenting with a unilateral adrenocortical nodule: A case report. *J Med Case Rep* 2014; 8: 38.
8. Chinchurreta-Capote A, Trueba A, Hernandez FJ, Pinas P, Lopez S, Tena ME, et al. Ocular findings in Carney complex. *Arch Soc Esp Oftalmol* 2006; 81(12): 709-11.
9. Obeid AI, Marvasti M, Parker F, Rosenberg J. Comparison of transthoracic and transesophageal echocardiography in diagnosis of left atrial myxoma. *Am J Cardiol* 1989; 63(13): 1006-8.
10. Edwards A, Bermudez C, Piwonka G, Berr ML, Zamorano J, Larrain E, et al. Carney's syndrome: complex myxomas. Report of four cases and review of the literature. *Cardiovasc Surg* 2002; 10(3): 264-75.
11. Courcoutsakis NA, Tatsi C, Patronas NJ, Lee CC, Prassopoulos PK, Stratakis CA. The complex of myxomas, spotty skin pigmentation and endocrine overactivity (Carney complex): imaging findings with clinical and pathological correlation. *Insights Imaging* 2013; 4(1): 119-33.
12. Iwata T, Tamanaha T, Koezuka R, Tochiya M, Makino H, Kishimoto I, et al. Germline deletion and a somatic mutation of the PRKAR1A gene in a Carney complex-related pituitary adenoma. *Eur J Endocrinol* 2015; 172(1): K5-10.
13. Birla S, Aggarwal S, Sharma A, Tandon N. Rare association of acromegaly with left atrial myxoma in Carney's complex due to novel PRKAR1A mutation. *Endocrinol Diabetes Metab Case Rep* 2014; 2014: 140023.
14. Hamza E, Hadjkacem F, Ghorbel D, Mnif F, Rekik N, Mnif M, et al. Cushing's syndrome revealing carney complex: A case report. *Endocrinol Metab Int J* 2017; 5(4): 275-9.
15. Holm M, Hoei-Hansen CE, Rajpert-De ME, Skakkebaek NE. Increased risk of carcinoma in situ in patients with testicular germ cell cancer with ultrasonic microlithiasis in the contralateral testicle. *J Urol* 2003; 170(4 Pt 1): 1163-7.
16. Liu Q, Tong D, Liu G, Yi Y, Zhang D, Zhang J, et al. Carney complex with PRKAR1A gene mutation: A case report and literature review. *Medicine (Baltimore)* 2017; 96(50): e8999.
17. Tan IB, Ang KK, Ching BC, Mohan C, Toh CK, Tan MH. Testicular microlithiasis predicts concurrent testicular germ cell tumors and intratubular germ cell neoplasia of unclassified type in adults: A meta-analysis and systematic review. *Cancer* 2010; 116(19): 4520-32.