



Rare report of concurrent metastasis on bilateral atrial myxoma masses

Sahar Ayati⁽¹⁾ , Ahmad Amouzesi⁽²⁾ , Amir Dehghani-Samani⁽³⁾ 

Case Report

Abstract

BACKGROUND: This study simultaneously reports bilateral atrial tumor masses including the concurrent occurrence of metastatic carcinoma, consistent with metastatic breast carcinoma, on the main cardiac myxoma mass in the left atrium (LA) and metastatic carcinoma consistent with metastatic breast carcinoma for the right atrial (RA) mass.

CASE REPORT: These masses were observed in a 79-year-old female patient who had received her pacemaker 6 months ago due to electrical conduction disease. However, no tumor/mass was found in her echocardiogram at the time of the pacemaker reception and mild chest pain and dyspnea were the only signs of her huge masses. Bilateral interseptal atrial cardiac masses protruded to the LA and RA were observed in both atrial chambers in echocardiography, and she underwent the surgical resection of masses.

CONCLUSION: The findings of the current study represented a novel condition for a patient. More precisely, the patient had two different huge cardiac masses, and at the same time, the metastasis of breast cancer was reported on the other cardiac tumor/myxoma as well. In addition, metastatic carcinoma should be suspected in patients with cardiac myxoma mass consistent with heart block. The simultaneous presence of multiple masses inside the heart is not always evidence of myxoma, rather can be a metastatic lesion.

Keywords: Cardiac Tumor; Breast Carcinoma; Myxoma

Date of submission: 09 Sep. 2020, *Date of acceptance:* 29 Dec. 2020

Introduction

Cardiac tumors are mostly rare in comparison to other heart diseases and different tumors in other organs.¹ The results of some autopsy studies demonstrated that the overall prevalence of myxoma ranged from 0.002% to 0.33%.^{1,2} Unlike other types of neoplastic diseases, approximately 75% of heart-originated tumors are benign and asymptomatic^{1,3} although they are still related to several major complications including thrombus, valve obstruction, or even sudden cardiac death due to its unique location.⁴ In addition, nearly 75%, 23%, and 2% of these tumors are located in the left atrium (LA), right atrium (RA), and ventricle, respectively.^{1,5}

Cardiac myxoma is the most common inter-cardiac tumor comprising about 30%-50% of cases⁶ and has an incidence rate of 0.0017% in the general population. Further, it is commonly located in the LA and mainly originates from an area in the atrial septum

near the fossa ovalis.^{4,7} The RA myxomas are less common and could be found in the aorta, pulmonary artery, ventricles, vena cava, or even other organs.⁸

Metastasis, which is known as the spread of malignant cells from a primary tumor to distant sites, poses the most serious problem to cancer treatment and is the main cause of cancer patients' death. It occurs in a series of discrete steps including epithelial-mesenchymal transition, invasion, anoikis, angiogenesis, transport through vessels, and the outgrowth of secondary tumors, which have been modeled into a "metastatic cascade".⁹ To the best of our knowledge and current time, there is no report of concurrent

How to cite this article: Ayati S, Amouzesi A, Dehghani-Samani A. **Rare report of concurrent metastasis on bilateral atrial myxoma masses.** *ARYA Atheroscler* 2021; 17: 2235.

1- Department of Pathology, School of Medicine, Birjand University of Medical Sciences, Birjand, Iran

2- Associate Professor, Department of Cardiology, School of Medicine AND Cardiovascular Diseases Research Center, Birjand University of Medical Sciences, Birjand, Iran

3- School of Medicine, Birjand University of Medical Sciences, Birjand AND Department of Clinical Sciences, School of Veterinary Medicine, Shahrekord University, Shahrekord, Iran

Address for correspondence: Ahmad Amouzesi; Associate Professor, Department of Cardiology, School of Medicine, Cardiovascular Diseases Research Center, Birjand University of Medical Sciences, Birjand, Iran; Email: amouzesiahmad@gmail.com

metastatic carcinoma on myxoma worldwide. In this rare case, the concurrent occurrence of breast cancer metastasis on the other benign tumor is to our knowledge first reported by the researchers.

Case Report

A 79-year-old female patient, with full consciousness and a history of pacemaker implantation about 6 months ago, was referred to the hospital chiefly complaining of mild chest pain, mild dyspnea which began recently and became increasingly worse, severe sweating during the chest pain episodes, and lethargy. Chest pain frequency had a length of approximately one hour for each episode. Furthermore, the patient had a history of hypertension (HTN) and chronic obstructive pulmonary disease (COPD) from about 15 years ago. Drug usage history included atorvastatin 20 mg, amlodipine 5 mg, and aspirin 80 mg once per day each. Smoking and alcohol usage status, history of any kind of tumors/malignancy, and family history for any kind of hereditary, coronary diseases, and tumors were negative in the patient.

She had received her pacemaker 6 months ago due to severe conduction disease/complete heart block although macroscopically, she showed no signs of tumor/mass in her heart echocardiography. Body temperature, blood pressure, and respiratory rate were 37.5 °C, 140/80 mmHg, and 15 times/minute, respectively. Moreover, general examinations for all organs were normal. The first recorded electrocardiogram (ECG) illustrated a ventricular paced rhythm about 65 bpm with P wave marching through it (Figure 1), and other cardiac examinations including cardiac sounds, murmurs, and the like were normal as well.

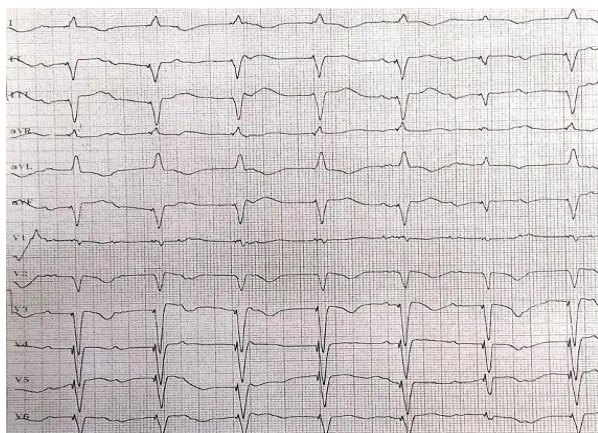


Figure 1. Primary recorded electrocardiogram (ECG) of the patient

It shows the ventricular paced rhythm about 65 bpm with P wave marching through it.

Echocardiography was performed for the patient, and the recorded data included mild pericardial effusion, moderate tricuspid valve regurgitation, and a bilateral homogenous large mobile mass attached to interatrial septum without any stalk protruded to the LA and protruded gently to the RA (Figure 2).

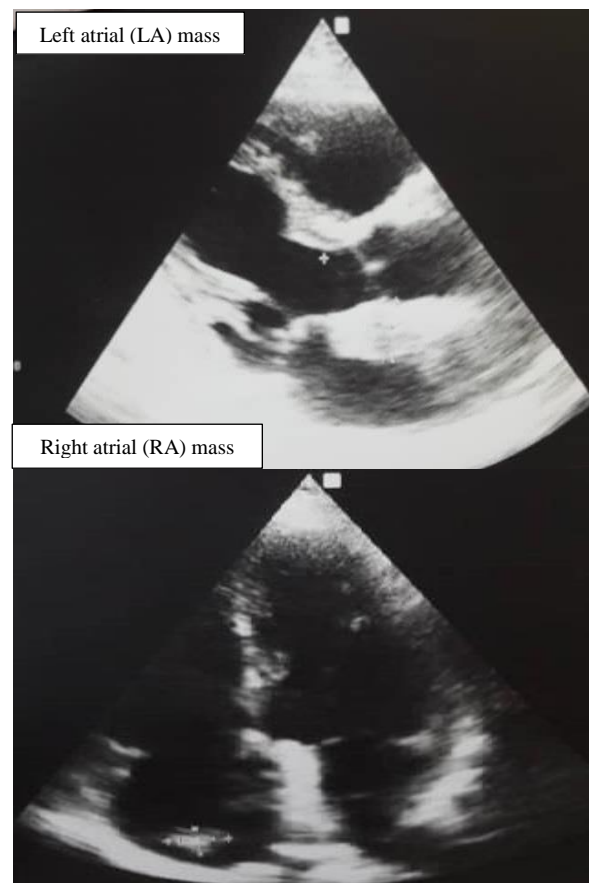

Figure 2. Echocardiography

Bilateral homogenous large mobile mass is attached to the interatrial septum without any stalk protruded to the left atrium (LA) and protruded gently to the right atrium (RA).

Then, the patient underwent a coronary angiography. Any kind of obstruction and/or constriction was recorded in coronary angiography. Several times of ventricular fibrillation (VF)/block attacks occurred for the patient 18 hours after echocardiography, and her consciousness became less and increasingly worse. The recorded ECG represented paced rhythms with intermittent junctional escape rhythms and P wave marching through it and complete heart block (Figure 3).

The pathology specimen underwent fixation, sliding, and staining procedures and immunohistochemistry (IHC) studies. The prepared slides of resected masses were observed carefully.

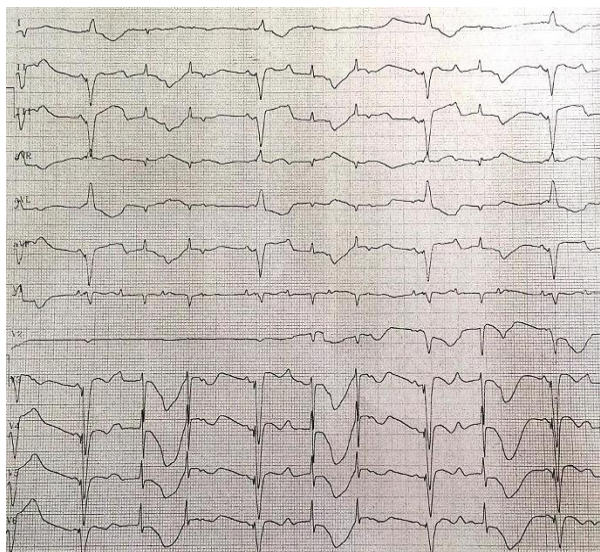


Figure 3. Ventricular fibrillation (VF)/block attack
Electrocardiogram (ECG) displays the paced rhythm with the intermittent junctional escape rhythm and P wave marching through it and complete heart block.

The LA mass sections showed a neoplastic tissue composed of nests and sheets including tumor cells with large hyperchromatic pleomorphic nuclei and scant cytoplasm. The main mass from the LA was primarily diagnosed as the cardiac myxoma although there were several signs of the infiltration of other tumor cells, suspected to concurrent metastatic carcinoma, on the main cardiac myxoma from the LA mass sections (Figure 4), and a similar sign of infiltrated tumor cells was observed for the RA mass sections (Figure 5).

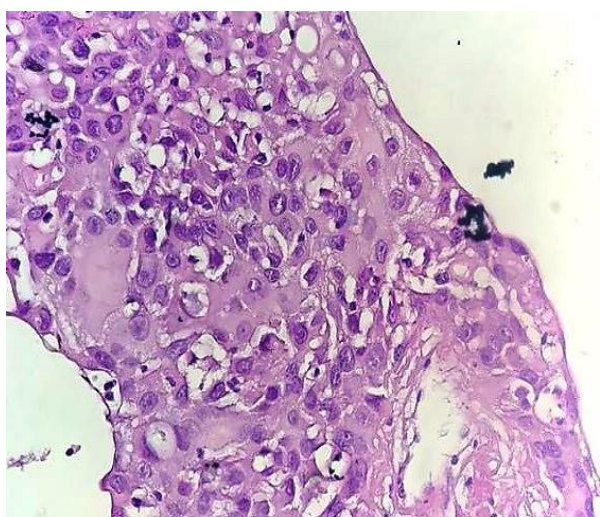


Figure 4. Left atrium (LA) mass section (cardiac myxoma with the infiltration of metastatic carcinoma)

Thus, IHC studies were recommended for a definite diagnosis.

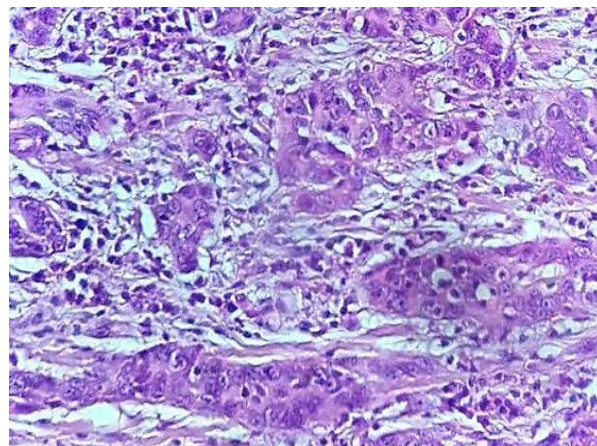


Figure 5. Right atrium (RA) mass section (metastatic carcinoma cell infiltration through cardiac cells)

The analysis of the expression of IHC markers was highly suspected to concurrent metastatic breast carcinoma on the main cardiac myxoma for the LA mass and metastatic carcinoma consistent with metastatic breast carcinoma for the RA mass. The endoplasmic reticulum (ER) (Figure 6) marker had definite positive reactivity/expression, and the Ki67 marker had about 70% positive reactivity.

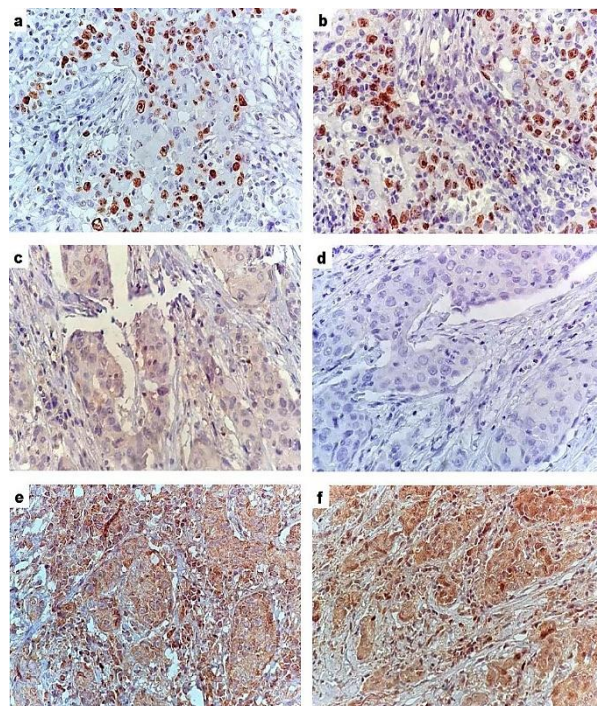


Figure 6. Reactivity/expression of different immunohistochemistry (IHC) markers
Endoplasmic reticulum (ER) (a) marker had definite positive reactivity/expression, and the Ki67 (b) marker had about 70% positive reactivity. However, other markers including GATA3 (c), cytokeratin 7 (CK7) (d), thyroid transcription factor-1 (TTF-1) (e), and PAX8 (f) had negative reactivity/expression.

Contrarily, other markers including GATA3, cytokeratin 7 (CK7), thyroid transcription factor-1 (TTF-1), and PAX8 had negative reactivity/expression. Finally, according to the overall condition, different examinations, and IHC studies, the definite diagnosis of the resected masses was reported as concurrent metastatic carcinoma, consistent with metastatic breast carcinoma, on the main cardiac myxoma for the LA mass and metastatic carcinoma consistent with metastatic breast carcinoma for the RA mass.

Discussion

Bilateral cardiac atrial masses with the concurrent occurrence of metastatic carcinoma, consistent with metastatic breast carcinoma, on the main cardiac myxoma for the LA mass and metastatic carcinoma consistent with metastatic breast carcinoma for the RA mass were simultaneously reported in this rare case for the first time to our knowledge. This report has several aspects of novelties in its area. It is repeatedly reported that myxoma, as the most reported primary cardiac tumor, is commonly located in the LA, and the other forms of myxoma including the RA myxoma, multiple cardiac myxomas, and bilateral myxoma are infrequent.^{8,10,11} To the best of our knowledge and current time, no similar report is available regarding the concurrent occurrence of different tumors on bilateral cardiac atrial masses, which also involved the cardiac interatrial septum in a patient at the same time.

It is reported that 60%, 30%, and 16% of myxomas are presented with obstructive symptoms, constitutional symptoms, and embolism, respectively, whereas 25% of cases are asymptomatic and incidentally discovered at echocardiography.¹⁰ In this report, a 79-year-old female patient, who had been referred to the hospital for her last chest pain and dyspnea, demonstrated no sign of the huge cardiac mass in her heart until a couple of days before her examinations. In addition, she showed no tumor/mass in her past echocardiography when she was referred to the hospital due to electrical conduction disease of her heart and received her pacemaker. Surprisingly, her huge cardiac mass had macroscopically grown only in six months. Further, it was uncertain in the retrograde study of her electrical conduction disease whether her last disease had occurred due to the AV node degenerative disease subsequent to the aging process or maybe due to the microfiltration of

metastatic breast carcinoma in the electrical conduction system of the heart. This was impossible to detect in the last echocardiography.

The central nervous system (CNS) metastases of breast carcinoma were repeatedly reported by different studies.¹²⁻¹⁴ Further, breast carcinoma gastric metastasis with its clinical presentation, endoscopic features, and treatment was reported as well.¹⁵ Another study also confirmed the histopathological, radiological, and prognostic features of the bone metastases of breast carcinoma.¹⁶ Breast carcinomas represented with axillary lymph node metastases were also reported by other clinicians.¹⁷ Ovarian metastases,¹⁸ cutaneous metastasis,¹⁹ and breast carcinoma metastasis to the choroid²⁰ and the ocular system²¹ were approved, and different patterns of breast carcinoma metastasis were studied as well.²²

Moreover, superior vena cava metastatic breast carcinoma²³ and mitral valve metastasis of breast carcinoma²⁴ were reported, but to the best of our knowledge and current time, this is the first report of concurrent metastatic carcinoma, consistent with metastatic breast carcinoma, on the main cardiac myxoma for the LA mass and metastatic carcinoma consistent with metastatic breast carcinoma for the RA mass in a patient.

Conclusion

To our knowledge, the current report is the first one to simultaneously show concurrent metastatic carcinoma, consistent with metastatic breast carcinoma, on the main cardiac myxoma for the LA mass and metastatic carcinoma consistent with metastatic breast carcinoma for the RA mass in a patient. The present study also shows a novel condition for a patient, representing that the patient had two different huge cardiac masses and the metastasis of breast cancer was reported on the other cardiac tumor/myxoma as well.

Acknowledgments

The authors would like to thank all those who helped during this research.

Conflict of Interests

Authors have no conflict of interests.

Authors' Contribution

AA: Study conception and design, SA: Analysis and interpretation of data, ADS: Drafting of manuscript.

References

1. Das S, Mohapatra CR, Badkhal A, Dhande S, Pohekar P, Khatod A. Cardiac myxoma, a rare but most common encountered cardiac tumor: A single center experience. *J Cardiothorac Med*. 2018; 6(3): 344-9.
2. McAllister HAJ, Fenoglio JJJ, Fine G. Tumors of the cardiovascular system. *Am J Surg Pathol* 1980; 4(3): 306.
3. Xiao Z, Meng W, Zhu D, Zhang E. A typical bilateral atrial myxoma: A case report. *Case reports in cardiology* 2012; 2012: 460268.
4. Diaz A, Di SC, Lawrence D, Hayward M. Left atrial and right ventricular myxoma: An uncommon presentation of a rare tumour. *Interact Cardiovasc Thorac Surg* 2011; 12(4): 622-3.
5. Roberts WC. Primary and secondary neoplasms of the heart. *Am J Cardiol* 1997; 80(5): 671-82.
6. McAllister HA, Hall RJ, Cooley DA. Tumors of the heart and pericardium. *Curr Probl Cardiol* 1999; 24(2): 57-116.
7. Vale Mde P, Freire SA, Sales MV, Teixeira MM, Cabral KC. Giant myxoma in the left atrium: case report. *Rev Bras Cir Cardiovasc* 2008; 23(2): 276-8.
8. Croti UA, Braile DM, Souza AS, Cury PM. Right ventricle and tricuspid valve myxoma. *Rev Bras Cir Cardiovasc* 2008; 23(1): 142-4. [In Portuguese].
9. Geiger TR, Peeper DS. Metastasis mechanisms. *Biochim Biophys Acta* 2009; 1796(2): 293-308.
10. Basso C, Rizzo S, Valente M, Thiene G. Prevalence and pathology of primary cardiac tumours. *J Cardiovasc Med* 2012; 15(1): 18-29.
11. Peachell JL, Mullen JC, Bentley MJ, Taylor DA. Biatrial myxoma: A rare cardiac tumor. *Ann Thorac Surg* 1998; 65(6): 1768-9.
12. Arslan UY, Oksuzoglu B, Aksoy S, Harputluoglu H, Turker I, Ozisik Y, et al. Breast cancer subtypes and outcomes of central nervous system metastases. *Breast* 2011; 20(6): 562-7.
13. Bendell JC, Domchek SM, Burstein HJ, Harris L, Younger J, Kuter I, et al. Central nervous system metastases in women who receive trastuzumab-based therapy for metastatic breast carcinoma. *Cancer* 2003; 97(12): 2972-7.
14. Carey LA, Ewend MG, Metzger R, Sawyer L, Dees EC, Sartor CI, et al. Central nervous system metastases in women after multimodality therapy for high risk breast cancer. *Breast Cancer Res Treat* 2004; 88(3): 273-80.
15. Taal BG, Peterse H, Boot H. Clinical presentation, endoscopic features, and treatment of gastric metastases from breast carcinoma. *Cancer* 2000; 89(11): 2214-21.
16. James JJ, Evans AJ, Pinder SE, Gutteridge E, Cheung KL, Chan S, et al. Bone metastases from breast carcinoma: histopathological - radiological correlations and prognostic features. *Br J Cancer* 2003; 89(4): 660-5.
17. Haupt HM, Rosen PP, Kinne DW. Breast carcinoma presenting with axillary lymph node metastases. An analysis of specific histopathologic features. *Am J Surg Pathol* 1985; 9(3): 165-75.
18. Gagnon Y, Tetu B. Ovarian metastases of breast carcinoma. A clinicopathologic study of 59 cases. *Cancer* 1989; 64(4): 892-8.
19. De G, V, Grazzini M, Alfaioli B, Savarese I, Corciova SA, Guerriero G, et al. Cutaneous manifestations of breast carcinoma. *Dermatol Ther* 2010; 23(6): 581-9.
20. Mewis L, Young SE. Breast carcinoma metastatic to the choroid. Analysis of 67 patients. *Ophthalmology* 1982; 89(2): 147-51.
21. Amichetti M, Caffo O, Minatel E, Roncadin M, Valli MC, Lozza L, et al. Ocular metastases from breast carcinoma: A multicentric retrospective study. *Oncol Rep* 2000; 7(4): 761-5.
22. Molnar IA, Molnar BA, Vizkeleti L, Fekete K, Tamas J, Deak P, et al. Breast carcinoma subtypes show different patterns of metastatic behavior. *Virchows Arch* 2017; 470(3): 275-83.
23. Sandhu HS, Mahendrakar SKM, Ladhani SS, Khan AH, Loya YS. Superior vena cava as gateway to heart: metastatic breast carcinoma causing ball in a loop metastasis to right atrium. *J Clin Diagn Res* 2017; 11(7): XD03-XD05.
24. Heidari A, Sabzi F. A case of mitral valve metastasis from breast carcinoma mimicking as a mitral valve regurgitation. *Acta Med Iran*. 2019; 57(1): 68-71.