

Septal hematoma due to stent implementation in the septal course of the left anterior descending artery

Ramin Khameneh-Bagheri⁽¹⁾, Reza Jafarzadeh-Esfehani⁽²⁾, Mostafa Ahmadi⁽¹⁾

Case Report

Abstract

BACKGROUND: The interventricular septal hematoma (IVSH) is a rare and potentially lethal finding. There are variously reported etiologies including instrumental damages during cardiac interventions. Although there are not enough studies available, conservative management is considered as a preferable approach in stable patients.

CASE REPORT: A 45-year man smoker with the previous history of percutaneous coronary intervention (PCI), admitted with unstable angina in present visit. Coronary angiography showed significant in-stent restenosis (ISR) of the left anterior descending (LAD) artery stent. During our intervention for treatment of the ISR, the wire movement caused a diffuse dissection without any runoff, in the distal portion of the LAD. Therefore two stents were deployed in the dissected segment with a short overlapping segment. Unfortunately, the overlapping segment of these stents was located in the myocardial bridge segment. Therefore the contraction of the interventricular septum (IVS) caused a scissor-like movement of the stents, and they ruptured the LAD into the septum. Therefore, the contrast agent was accumulated in the IVS. Immediately, a graft stent was deployed in the overlapping segment of stents and perforation became sealed. In echocardiography, the IVS diameter increased to 30 mm. Since the patient was hemodynamically and electrically stable, he underwent conservative approach and after two months the septum returned to the normal size.

CONCLUSION: During PCI on the LAD artery, the implantation of stents in the septal course with a short overlapping segment can result in coronary perforation, and therefore IVS hematoma by the scissor effect. Septal hematoma may cause life-threatening arrhythmias or ventricular septal rupture, but if it is asymptomatic or uncomplicated. Conservative management is the best strategy.

Keywords: Percutaneous Coronary Intervention, Myocardial Bridge, Hematoma

Date of submission: 09 Aug. 2016, *Date of acceptance:* 23 July 2017

Introduction

The interventricular septal hematoma (IVSH) is a rare finding in cardiology practice. Chest trauma, myocardial infarction,^{1,2} and instrumental manipulation during cardiac surgery or percutaneous coronary intervention (PCI) may lead to myocardial and IVSH. While some patients are symptom-free, lethal arrhythmias or ventricular septal rupture (VSR) may occur as the adverse cardiac events.³ In this report, we will discuss a case of IVSH due to stenting of the left anterior descending artery in its myocardial bridge segment.

Case Report

The patient was a 45-year man smoker with a

history of coronary artery disease. He had undergone coronary angiography in another center due to acute coronary syndrome, six months prior to the present admission. The angiography revealed significant diffuse stenosis in the proximal segment of the left anterior descending artery (LAD), at the bifurcation of a well-developed diagonal branch. Furthermore, a muscle bridge was also detected in the mid-portion of LAD. Besides, the proximal portion of the right coronary artery (RCA) had significant diffuse stenosis. The echocardiography at that time revealed hypokinesia of anterior wall and the ejection fraction was about 45%. Percutaneous coronary intervention (PCI) had performed on the proximal portion of the LAD with a 2.75×19

1- Assistant Professor, Department of Cardiology, School of Medicine, Mashhad University of Medical Sciences, Mashhad, Iran

2- PhD Candidate, Department of Medical Genetics, School of Medicine, Mashhad University of Medical Sciences, Mashhad AND Researcher, Student Research Center, Sabzevar University of Medical Science, Sabzevar, Iran

Correspondence to: Mostafa Ahmadi, Email: mostafaahmadi1975@gmail.com

drug-eluting stent (DES). He had been discharged in stable clinical condition.

After 6 months, the patient was admitted with unstable angina in our cardiology ward. Again, the coronary angiography was performed and showed significant in-stent restenosis of the LAD stent, and significant stenosis of the ostium of the well-developed diagonal branch which was behind the stent. The RCA was as before.

We decided to do PCI on RCA and kissing balloon inflation of the LAD-diagonal lesion, using a non-compliant drug-eluting balloon (DEB) in the LAD stent. A 3-33 mm DES was implanted in a proximal portion of the RCA.

For treatment of in-stent restenosis of the LAD artery and the diagonal branch stenosis, we advanced a hydrophilic wire into the LAD and another tapered-tip wire through the struts of the LAD stent into the diagonal branch. Final kissing balloon inflation was performed by using two non-compliant (NC) balloons (3 × 15 mm DEB and 2.5 × 12 mm NC-balloons in the LAD and diagonal arteries). Unexpectedly, a diffused dissection without a distal runoff (type F) appeared in the mid to distal portions of the LAD due to the wire to-and-fro movement. Primarily and according to the available stents, the distal portion of the dissected segment was covered by using a 2.75 × 26 DES (Figure 1).

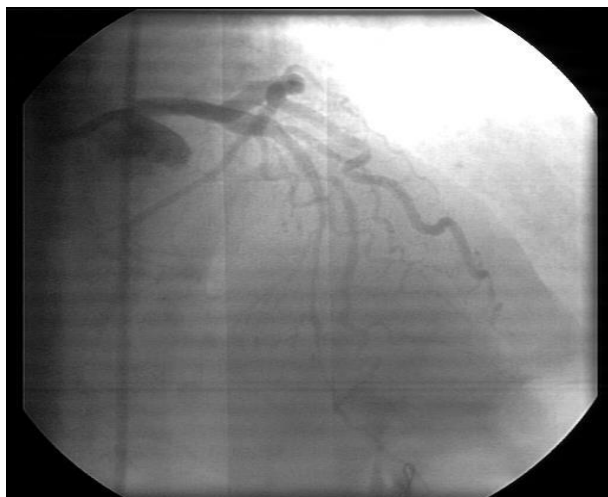

Figure 1. Wire dissection at the distal segment of left anterior descending

Then another stent (2.75 × 16 mm) was implanted in the proximal segment of the dissection with a short overlapping segment of the first stent (about 1-2 mm). These two stents covered the septal course of the LAD (called as the myocardial

bridge). The thrombolysis in myocardial infarction (TIMI) flow 3 of LAD was restored. The post-dilatation was performed by using a 3-15 NC balloon. But after some minutes, the diagonal ostium recoiled and the patient suffered from chest pain due to impaired diagonal artery flow. Obligatorily a 2.5 × 8 stent was deployed in the diagonal branch with the T-stenting technique. Before terminating the procedure, we observed contrast opacification around the LAD (Figure 2).

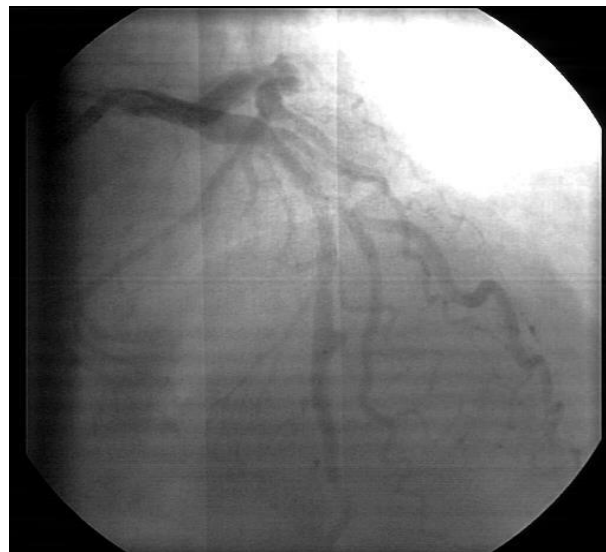


Figure 2. Enlarging opacification around the left anterior descending, impending to rupture

It resembled an enlarging sac which suddenly ruptured (Figure 3).

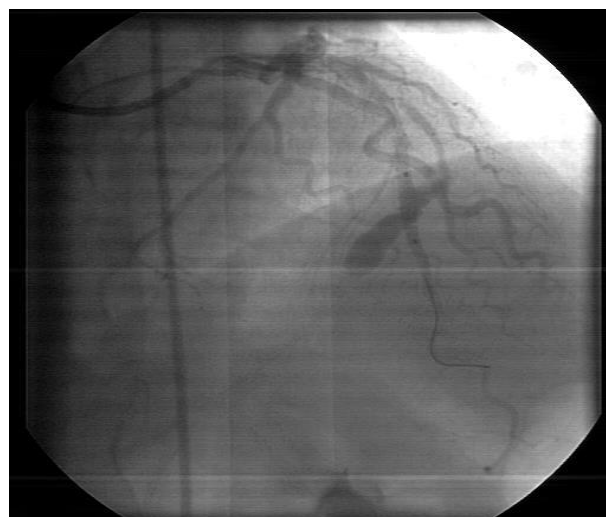

Figure 3. Rupture of left anterior descending to ventricular septum

Therefore, a graft stent was deployed

immediately at the overlapping segment of the stents and it sealed the perforation (Figure 4).

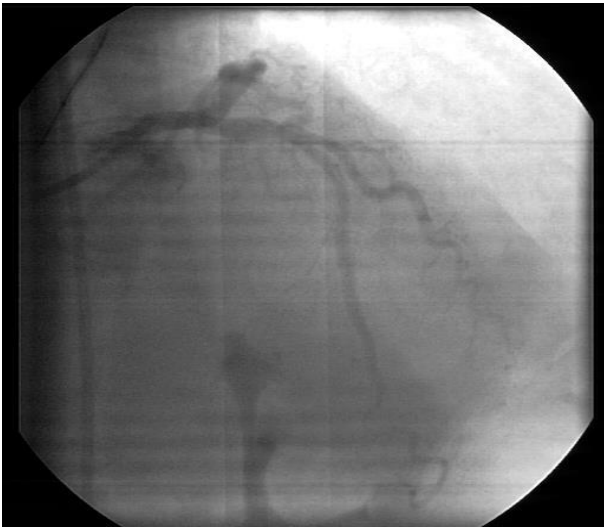

Figure 4. After graft stent deployment

In this stage, the heparin effect was reversed by prothamin sulfate. The echocardiography at the same time showed a voluminous (about 30 mm) ventricular IVSH (Figure 5).

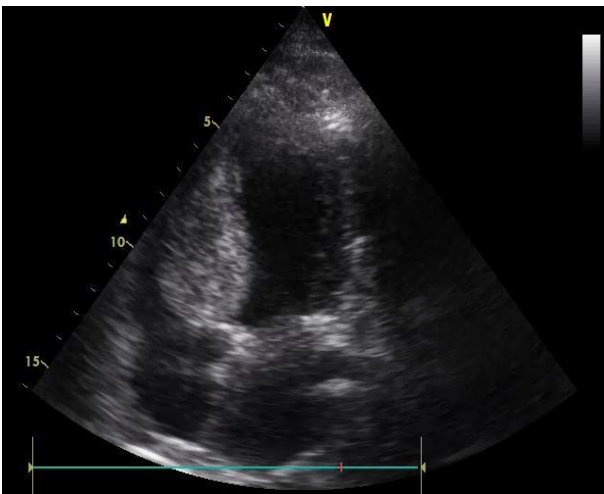

Figure 5. Ventricular septal hematoma

After 10 days and before discharge, another angiography revealed the stent of the diagonal branch was under-expanded. Therefore final kissing balloon inflation of the LAD and diagonal artery stent was done and it made full expansion of both stents.

The patient was closely observed postoperatively and underwent echocardiography every 15 days. During the next two months follow up, the size of the hematoma reduced and septum size returned to normal range. Moreover, the wall motion abnormalities were resolved (Figure 6).

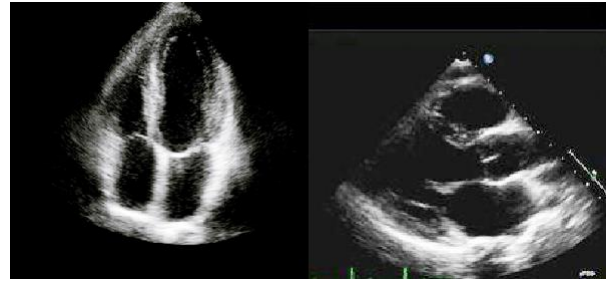


Figure 6. Returning of septal diameter to the normal range

Discussion

It has been reported that different clinical settings such as acute myocardial infarction, coronary artery bypass surgery, ventricular septal defect repair, chest wall trauma and aortic valve disease could cause a myocardial hematoma. Although this complication is rare, it can cause serious conduction or hemodynamic abnormalities including outflow obstruction, high-grade atrioventricular block, ventricular septal rupture, abscess transformation and tamponade. The septal perforating artery injury may lead to ventricular IVSH that can occur during wire or microcatheter negotiation through the branch,² or suturing the septal patch at the time of ventricular septal defect (VSD) repair,⁴ or even during cardiac resynchronization therapy defibrillator (CRT-D) implantation.⁵

In almost all reports, patients had responded to conservative treatment instead of surgical evacuations, especially when they were hemodynamically and electrically stable. In a case report, the ventricular septal rupture associated with an IVSH resolved after 5 weeks.² In another report IVSH with 4 cm diameter resolved in 6 weeks.⁵ A case series reported 2 cases of IVSH and coronary ventricular fistula after chronic total occlusion percutaneous coronary intervention (CTO-PCI).⁶ One of their patients developed a large IVSH 6 hours after PCI. While the patient general condition was stable and without any arrhythmia, they decided to follow their patient by serial echocardiography and the hematoma was resolved after 3 months of follow up. The other patient who developed sinus tachycardia and intermittent chest pain was managed in a different way. They could successfully resolve perforation from the LAD by deploying covered stent across the collateral vessel.⁶ Murthy *et al.* reported a case of dual coronary perforations into the left ventricle (LV) resulted from balloon dilatation of under-expanded distal stent.⁷ The coronary perforation showed extravasation of contrast to LV. They managed their asymptomatic patient's both perforations by

covered stents.⁷ Higuchi et al. reported a case of complicated PCI in a 56-year man.⁸ During the PCI of chronic total occlusion (CTO) lesion, while they were trying to pass a stiff guide wire to the diagonal branch, extravasation of blood into subepicardial space led to cardiogenic shock. As they could not evacuate all the blood surrounding the LV by percutaneous pericardiocentesis, a median sternotomy was performed to remove the hematoma. Their patient received percutaneous cardiopulmonary support after the surgery and continuous drainage of blood from pericardial space was proceeding. The echocardiography showed hematoma of lateral LV. Because of their patient's hemodynamic condition and multi-organ dysfunction, they could not perform a thoracotomy, resulted in patient's death 3 weeks after surgery.⁸ Galiuto et al. reported intramural atrial hematoma because of dissection of coronary artery side branch during PCI in a 79-year woman.⁹ They used myocardial contrast echocardiography in order to get a characterization of blood supply status of hematoma. While their patient developed persistent postprandial chest pain and dysphagia, they decided to perform surgical exploration and successfully drained the entire amount of clots and blood.⁶

The septal injury in our case was due to the scissor effect of two stents with the short overlapping segment, in the septal course of LAD artery (myocardial bridge segment). Because there was no symptom or arrhythmia, we observed the patient closely. Furthermore, heparin was discontinued but dual antiplatelet therapy continued. The hematoma spontaneously resolved after 8 weeks.

Finally, it seemed that serial echocardiography should be performed in stable patients until the hematoma is resolved. In case of enlarging hematoma, or any other complications, surgical evacuation of the hematomas should be considered.

Acknowledgments

None.

Conflict of Interests

Authors have no conflict of interests.

References

1. El-Battrawy I, Akin I, Munz B, Leistner DM, Behnes M, Henzler T, et al. Solid right ventricular compression by interventricular septum-hematoma induced after percutaneous coronary intervention. *Case Rep Cardiol* 2016; 2016: 6218723.
2. Fairley SL, Donnelly PM, Hanratty CG, Walsh SJ. Images in cardiovascular medicine. Interventricular septal hematoma and ventricular septal defect after retrograde intervention for a chronic total occlusion of a left anterior descending coronary artery. *Circulation* 2010; 122(20): e518-e521.
3. Araki M, Murai T, Kanaji Y, Matsuda J, Usui E, Niida T, et al. Interventricular septal hematoma after retrograde intervention for a chronic total occlusion of a right coronary artery: Echocardiographic and magnetic resonance imaging-diagnosis and follow-up. *Case Rep Med* 2016; 2016: 8514068.
4. Lazarus A, Alonso C, Jauvert G. Interventricular septum haematoma following CRT-D implant. *Europace* 2010; 12(3): 436.
5. Padalino MA, Spegginorin S, Pittarello D, Milanese O, Stellin G. Unexpected interventricular septal hematoma after ventricular septal defect closure: Intraoperative echocardiographic early detection. *Eur J Echocardiogr* 2007; 8(5): 395-7.
6. Abdel-Karim AR, Vo M, Main ML, Grantham JA. Interventricular septal hematoma and coronary-ventricular fistula: A complication of retrograde chronic total occlusion intervention. *Case Rep Cardiol* 2016; 2016: 8750603.
7. Murthy A, Singh A, Driesman M. Acquired coronary cameral fistula due to post stent balloon dilatation: Dual coronary artery perforations into the left ventricle-what is the right treatment? *World J Cardiovasc Dis* 2014; 4(11): 548-55.
8. Higuchi Y, Fukamachi D, Fujii N, Nishida T, Nishida T, Hirayama A. Cardiogenic shock caused by a large sub-epicardial hematoma complicating percutaneous coronary intervention. *Case Reports in Clinical Medicine* 2015; 4(6): 233-6.
9. Galiuto L, Fedele E, Locorotondo G, Pisanello C, Favocchia C, Danza ML, et al. Intramural atrial hematoma: A rare complication of a common procedure. *Echocardiography* 2013; 30(8): E255-E257.

How to cite this article: Khameneh-Bagheri R, Jafarzadeh-Esfehani R, Ahmadi M. **Septal hematoma due to stent implementation in the septal course of the left anterior descending artery.** *ARYA Atheroscler* 2017; 13(5): 253-6.