

Rare post-operative complications of large mediastinal tumor resection

Mohsen Mirmohammadsadeghi⁽¹⁾, Amir Mirmohammadsadeghi⁽²⁾

Case Report

Abstract

BACKGROUND: There are some reports in the literature, which suggest that cardiac tamponade drainage may transiently affect systolic function and also cause acute respiratory distress syndrome (ARDS). We did not find any reports of acute ventricular failure and ARDS secondary to mediastinal tumor resection without tamponade.

CASE REPORT: Here we report a 48-year-old woman presenting with massive pericardial effusion without tamponade in whom tumor was resected through median sternotomy using cardiopulmonary bypass. ARDS and acute heart failure were two rare complications that happened at the end of the operation secondary to a sudden decompression of the heart from tumor pressure.

CONCLUSION: ARDS and acute heart failure are two rare complications, which can happen after large mediastinal tumor resection.

Keywords: Heart Failure, Acute Respiratory Distress Syndrome, Mediastinal Neoplasms, Pericardium

Date of submission: 15 May 2014, *Date of acceptance:* 12 Jan 2015

Introduction

There are some reports in the literature, which suggest that cardiac tamponade drainage may transiently affect systolic function and also may cause acute pulmonary edema. Both cardiogenic and non-cardiogenic pulmonary edemas are reported in different cases as the cause of sudden deterioration in oxygenation after pericardiocentesis. Different etiologies of tamponade are reported, which are mostly malignant and one case of traumatic pericardial effusion.¹⁻⁵ In our case, a large anterior mediastinal tumor obviously compressing anterior elements of the heart caused massive pericardial effusion without tamponade and its resection caused sudden both ventricular failure and pulmonary edema.

Case Report

A 48-year-old female was consulted for recurrence of massive pericardial effusion. Pericardial window through left thoracotomy had been done 3 months ago for cardiac tamponade. The fluid cytology was negative. This time she had orthopnea without pulsus paradoxus. Laboratory data were normal. Chest X-ray (CXR) showed abnormal borders of the heart. Echocardiography revealed recurrence of

massive pericardial effusion without right ventricular (RV) collapse. Ejection fraction was normal, and a suspicious mass on RV was reported. In computed tomography scan a large (10 × 7 cm) superior mediastinal mass containing calcific density foci suggesting mesenchymal origin was mentioned with pericardial effusion (Figure 1).

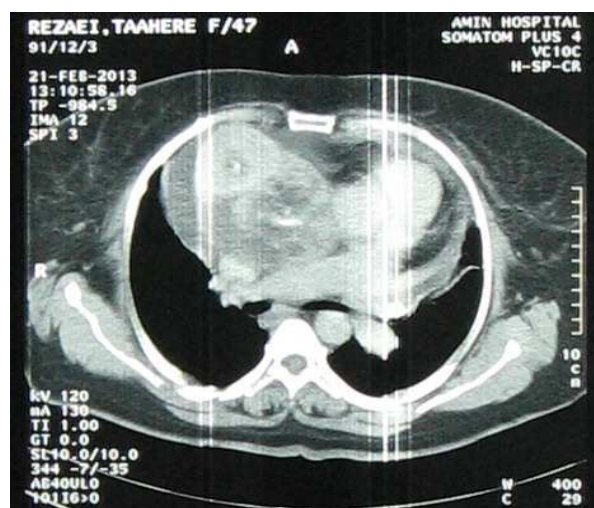


Figure 1. Pre-operative computed tomography showing a large (10 × 7 cm) superior mediastinal mass containing calcific density foci

1- Associate Professor, Department of Cardiovascular Surgery, School of Medicine, Isfahan University of Medical Sciences, Isfahan, Iran

2- Assistant Professor, Department of Cardiovascular Surgery, School of Medicine, Isfahan University of Medical Sciences, Isfahan, Iran

Correspondence to: Amir Mirmohammadsadeghi, Email: am_sadeghi@med.mui.ac.ir

Hence, she was prepared for operation. As midsternotomy was done a large whitish mass obscuring and compressing the heart was seen (Figure 2). After early dissections, although it had severe adhesions to superior vena cava, right atrium (RA), RV and specially aorta it seemed to be resectable. Cardiopulmonary bypass (CPB) was established through the femoral artery and RA cannulation after releasing RA from the tumor. The highly vascularized tumor was resected encapsulated only after careful dissections separating it from adhesive cardiac elements specially aorta. She came off CPB with low dose inotrope. But while hemostasis was being done oxygen saturation began to decrease and cardiac contractions became weak with sudden ventricular fibrillation, which was resistant to internal shocks and medications.

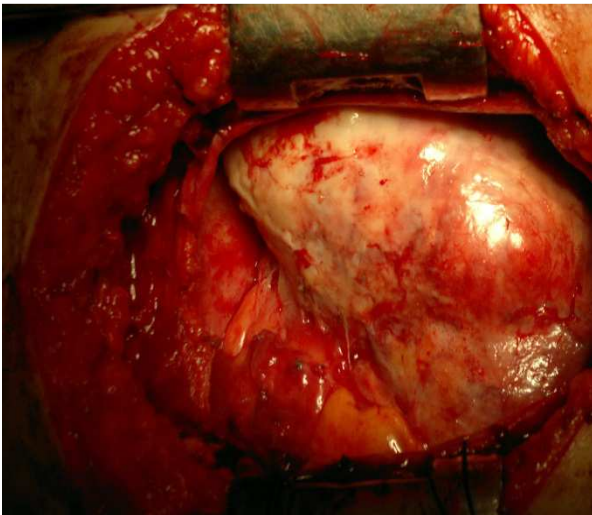


Figure 2. Intraoperative image of a large whitish extra-cardiac tumor obscuring superior vena cava, right atrium, aorta and pulmonary artery

During 15 min of internal cardiac massage about 15-20 internal shocks were given with various drugs. At last, heart began to contract in sinus rhythm again. Bleeding points were packed, and she was brought to intensive care unit after only closing the skin. Although high dose inotropes and 100% FiO₂ were supplied, oxygen saturation was about 60%. CXR showed patchy densities in both lungs similar to acute respiratory distress syndrome (ARDS). Echocardiography showed moderate RV dilatation and dysfunction with left ventricular (LV) ejection fraction of about 50%. Respiratory support for ARDS and inotropic support for RV failure was continued. After the 3rd post-operative day, arterial oxygen saturation began to rise and inotrope requirements were decreased. A multidrug-resistant

Klebsiella pneumonia complicated the weaning course and tracheostomy was done. Pneumonia responded to empirical fluconazole prescription. Furthermore, she was complicated with acute illness myopathy, which she could hardly move her extremities. Pathology report was 14 × 10 × 8 cm solid to cystic tumor, which after checking immunohistochemistry examinations solitary fibrous tumor was diagnosed. She was transferred from intensive care unit (ICU) on 3rd post-operative day and was discharged from hospital on 33rd post-operative day. Myopathy nearly completely resolved after 3 months of physiotherapy, but moderate RV failure did not resolve after 3 months despite no clinical symptoms.

Discussion

Pericardial effusion drainage either percutaneously or surgically may cause sudden ventricular failure either on the right heart or on the left heart in about 4.8% of the patients.¹ Different terms are used for this complication, which we prefer “pericardial decompression syndrome.”¹ Among some mechanisms, which are suggested for this complication is sudden decrease of pericardial pressure, which can lead to disproportionate increase in end-diastolic volume of the right ventricle compared with left ventricle and a temporary mismatch of the ventricular outputs.^{2,3} Also, the presence of high peripheral vasoconstriction and volume overload may cause acute LV wall stress and LV failure after decompression.^{2,3} Other mechanisms such as myocardial stunning because of a mismatch of oxygen distribution across the myocardial wall and altered coronary blood flow because of increased pericardial pressures are also mentioned.^{2,3}

Another complication, which may happen early after sudden cardiac tamponade decompression is pulmonary edema.^{2,4} It is hypothesized that LV dysfunction following pericardiocentesis and preload increase causes the problem.^{2,4}

In this case, patient was presented with recurrence of massive pericardial effusion secondary to large anterior mediastinal tumor. In contrast to all reported cases, this case had no cardiac tamponade and were the first case in which external tumor pressure was the cause of this complication.¹⁻⁵ The cardiac failure was mainly on the right side and although she clinically improved after 3 days RV failure and dilatation remained in moderate severity even after 3 months. In contrast to our case in some

reports ventricular function has been completely resolved; may be chronic tumor pressure on myocardium causes fibrosis and partially reversible myocardial damage. The pulmonary edema was non-cardiogenic ARDS and was presented with decreased PaO₂ and diffuse patchy densities on the CXR. The same as some case reports our patient improved clinically by day 3, but in some other reports the patients did not survive.^{2,5}

We suggest ventricular failure and ARDS be kept in mind as possible early intraoperative complications of decompression of the heart from extra-cardiac tumor pressure.

Acknowledgments

The authors would like to thank all members of the Chamran Heart Center operating room in Isfahan, Iran.

Conflict of Interests

Authors have no conflict of interests.

References

1. Angouras DC, Dosios T. Pericardial decompression

syndrome: a term for a well-defined but rather underreported complication of pericardial drainage. *Ann Thorac Surg* 2010; 89(5): 1702-3.

2. Karamichalis JM, Gursky A, Valaulikar G, Pate JW, Weiman DS. Acute pulmonary edema after pericardial drainage for cardiac tamponade. *Ann Thorac Surg* 2009; 88(2): 675-7.
3. Bernal JM, Pradhan J, Li T, Tchokonte R, Afonso L. Acute pulmonary edema following pericardiocentesis for cardiac tamponade. *Can J Cardiol* 2007; 23(14): 1155-6.
4. Shenoy MM, Dhar S, Gittin R, Sinha AK, Sabado M. Pulmonary edema following pericardiotomy for cardiac tamponade. *Chest* 1984; 86(4): 647-8.
5. Sunday R, Robinson LA, Bosek V. Low cardiac output complicating pericardiectomy for pericardial tamponade. *Ann Thorac Surg* 1999; 67(1): 228-31.

How to cite this article: Mirmohammadsadeghi M, Mirmohammadsadeghi A. **Rare post-operative complications of large mediastinal tumor resection.** *ARYA Atheroscler* 2015; 11(2): 160-2.