

Apixaban, a Novel Oral Anticoagulant, Use to Resolute Arterial Patency in Radial Artery Occlusion Due to Cardiac Catheterization; A Pilot Randomized Clinical Trial

Afshin Amirpour⁽¹⁾, Reihaneh Zavar⁽²⁾, Amir Seifipour⁽³⁾, Masoumeh Sadeghi⁽¹⁾, Ehsan Shirvani⁽³⁾, Mohammad Kermani-Alghoraishi⁽³⁾, Hamid Sanei⁽³⁾, Seyed Mohammad Hashemi Jazi⁽⁴⁾, Ali Pourmoghaddas⁽⁴⁾, Alireza Khosravi Farsani⁽⁵⁾, Ehsan Zarepour⁽²⁾, Ali Safaei⁽²⁾, Razieh Hassannejad⁽²⁾

Original Article

Abstract

INTRODUCTION: In recent years, transradial cardiac catheterization has become the preferred method. However, it can result in a significant complication known as radial artery occlusion (RAO). The medical management of RAO remains controversial, especially with the emergence of novel oral anticoagulants. Nevertheless, there is limited data on the use of these agents for treating RAO, which is the focus of this study using apixaban.

METHOD: This pilot double-blinded randomized clinical trial involved 30 patients who developed RAO following transradial coronary angiography. The patients were randomly assigned to receive either apixaban (2.5 mg twice daily) or a conservative approach for 30 days. Doppler ultrasonography was performed at baseline and at the end of the intervention to assess radial artery diameter and the resolution of arterial patency. Demographic, medical, medication, and clinical characteristics were collected.

RESULTS: The mean age of the studied population was 59.43±12.14 years, and the majority were males (60%). Radial artery resolution was observed in 21 (70%) patients, independent of medication use. There was no significant association between resolution and age (P-value=0.62), gender (P-value=0.74), body mass index (P-value=0.23), smoking (P-value=0.64), diabetes (P-value=0.999), hypertension (P-value=0.74), statins (P-value=0.999), antiplatelet therapy (P-value=0.999), length of angiography (P-value=0.216), or follow-up arterial diameter (P-value=0.304). Recanalization occurred in 13 (86.7%) cases in the apixaban treatment group, compared to 8 (53.3%) individuals in the control group, indicating a significant difference (P-value=0.046).

CONCLUSION: The study findings suggest no demographic, medical, medication, or clinical factors were associated with arterial recanalization. However, a one-month treatment with apixaban at a dose of 2.5 mg twice daily appeared to be effective.

Keywords: Apixaban, Anticoagulants, Coronary angiography, Catheterization, Ultrasonography

Date of submission: 2023-Jul-07, *Date of acceptance:* 2023-Aug-29

Introduction

Campeau first proposed Transradial (TR) coronary angiography in 1989¹. Its significance

grew when Kiemeneij et al. reported their successful experience with coronary artery angioplasty via this approach on August 14, 1992^{2,3}. Since then, TR access has surpassed

1- Cardiac Rehabilitation Research Center, Cardiovascular Research Institute, Isfahan University of Medical Sciences, Isfahan, Iran

2- Isfahan Cardiovascular Research Center, Cardiovascular Research Institute, Isfahan University of Medical Sciences, Isfahan, Iran

3- Interventional Cardiology Research Center, Cardiovascular Research Institute, Isfahan University of Medical Sciences, Isfahan, Iran

4- Department of Cardiology, Faculty of Medicine, Isfahan University of Medical Sciences, Isfahan, Iran

5- Hypertension Research Center, Cardiovascular Research Institute, Isfahan University of Medical Science, Isfahan, Iran

Address for correspondence: Amir Seifipour, Interventional Cardiology Research Center, Cardiovascular Research Institute, Isfahan University of Medical Sciences, Isfahan, Iran. E-mail address: amirmed1402@gmail.com

transfemoral access, offering improved outcomes such as anatomic isolation, safer angiography or percutaneous coronary intervention options, reduced mortality, and decreased access-site vascular complications⁴. Both European and American guidelines endorse a “radial first” strategy (Class of Recommendation I, Level of Evidence A), whenever feasible and regardless of clinical presentation, to be performed by proficient operators.

Radial artery occlusion (RAO), even when asymptomatic, can limit future radial access and restrict the use of the radial artery for dialysis fistula, bypass graft conduits, or invasive arterial pressure monitoring. Hence, the prevention of RAO is crucial.

However, RAO is associated with challenges such as radial artery spasm, hematoma, pseudoaneurysm formation, and RAO itself, a common complication with an estimated incidence of 1-30%^{5,6}. Rapid occurrence of RAO post-intervention can be attributed to thrombus formation resulting from endothelial injury, leading to impaired radial perfusion⁷.⁸ Common symptoms associated with RAO include pain, pallor, paresthesia, paralysis, and pulselessness. Despite its relatively high incidence, it may be underdiagnosed due to insidious presentation, lack of routine post-catheterization assessment, and the need for objective evaluations. A dual blood supply to the hand further contributes to the delayed diagnosis of RAO⁹.

Clinical risk factors for RAO incidence include the caliber of the introducer sheath and its ratio to the arterial diameter, repeated access of the same artery, failure to achieve and maintain hemostasis, and the level of anticoagulation¹⁰. However, the optimal approach to managing RAO remains uncertain, with limited trials generally supporting treatment with low molecular weight heparin^{11,12}. Furthermore, limited data is available on using novel oral anticoagulants (NOACs), which this study aims to assess.

Materials and Methods

Study population

This pilot double-blinded randomized clinical trial was conducted at the Shahid Chamran Cardiology Center, affiliated with Isfahan University of Medical Sciences, from January to December 2022. The study included 30 patients who underwent coronary angiography through the radial artery.

Ethical considerations and informed consent

The study protocol was approved by the Ethics Committee of Isfahan University of Medical Sciences (code number IR.MUI.MED.REC.1401.338) and registered in the Iranian Registry for Clinical Trials (code number IRCT20221013056161N1). Participants were provided with a thorough explanation of the study, assured of the confidentiality of their personal information, and informed about their right to refuse participation without compromising their care. Written consent was obtained from all participants before starting the study.

Inclusion criteria

Eligible participants were over 18 years old who had undergone coronary angiography through the radial artery, and presented symptoms such as pain, paresthesia, hematoma, and ecchymosis in the hand, compatible with RAO confirmed by Doppler ultrasonography.

Exclusion criteria

Being under treatment with other anticoagulant agents with different therapeutic doses, having severe symptoms necessitating rapid arterial recanalization, and contraindications to apixaban use (hypersensitivity, active clinical bleeding, homeostatic disturbances, and advanced chronic kidney disease).

Sample size

In this pilot phase, a total of 30 patients entered the study.

Study protocol

Doppler ultrasonography (Sonosite Fujifilm, 8 MHz, USA) was performed by a target Echocardiography fellowship-trained specialist to assess intraluminal blood flow and confirm RAO based on the absence of forward blood flow detected in triphasic waves. Radial artery diameter was also measured and recorded.

Interventions

Patients received either apixaban (2.5 mg, twice daily) (Abidipharma, Iran) tablets orally or were followed conservatively for 30 days. At each visit, patients in the intervention group received the number of tablets needed to be taken until the next scheduled appointment. If, for any reason, a treatment interruption occurred, the treatment duration was to be extended until the volunteer had taken 30 tablets.

Study outcome

The primary outcome was the recanalization of the radial artery, assessed by performing another Doppler ultrasonography at the end of the intervention. Forward blood flow through triphasic waves was evaluated, and the radial artery diameter was remeasured.

Follow up

The duration of the study was 30 days, and medication adherence was monitored through telephone follow-ups within 14 days of initiation.

Randomization

Considering the study design, all individuals who presented symptoms compatible with RAO, met the study criteria, and were eligible to participate, entered into the investigation through convenience sampling. Then, they were requested to refer to the secretary who was blinded about anything in the study. She gave the patients unseen envelopes each containing a random number; if the numbers were even, the patients were assigned to the intervention group; otherwise, they were managed conservatively.

Mechanism Implementation

The study was conducted in a double-blinded design. Given that the person who performed the post-intervention ultrasonographies and the biostatistician were blinded about the groups. In this term, the checklists were categorized as group 1 and 2.

Data collection

Demographic data, including age, gender, smoking status, height, and weight, were collected from medical records. Body mass index (BMI) was calculated based on weight in kilograms divided by height in meters cubed. Other collected data included chronic medical conditions, hypertension, diabetes mellitus, and medication history, including statins, single antiplatelet therapy (SAPT), or dual antiplatelet therapy (DAPT). The duration of coronary artery angiography (CAG) was recorded.

Statistical analysis

Data were analyzed using the Statistical Package for Social Sciences (SPSS, version 22, IBM Corporation, Armonk, NY, USA). Categorical variables were presented as absolute numbers and percentages, and comparisons were made using the chi-square or Fisher's exact test. Continuous variables were reported as mean and standard deviation. The normal distribution of numerical data was assessed using the Kolmogorov-Smirnov test. An Independent t-test was used for normally distributed continuously.

Results

In this study, the eligibility of 37 patients was assessed, of whom five individuals did not meet the study inclusion criteria. Among these five patients, 2 required therapeutic anticoagulation, 3 had contraindications for apixaban use, and one did not present for further evaluations at our center. Thus, the final analysis included 30 patients with confirmed radial artery occlusion (RAO) following coronary angiography through the radial artery. Detailed information of the studied population is demonstrated in

Figure 1. All participants completed the study protocol as intended. Most patients were male (60%), and the mean age was 59.43 ± 12.14 years.

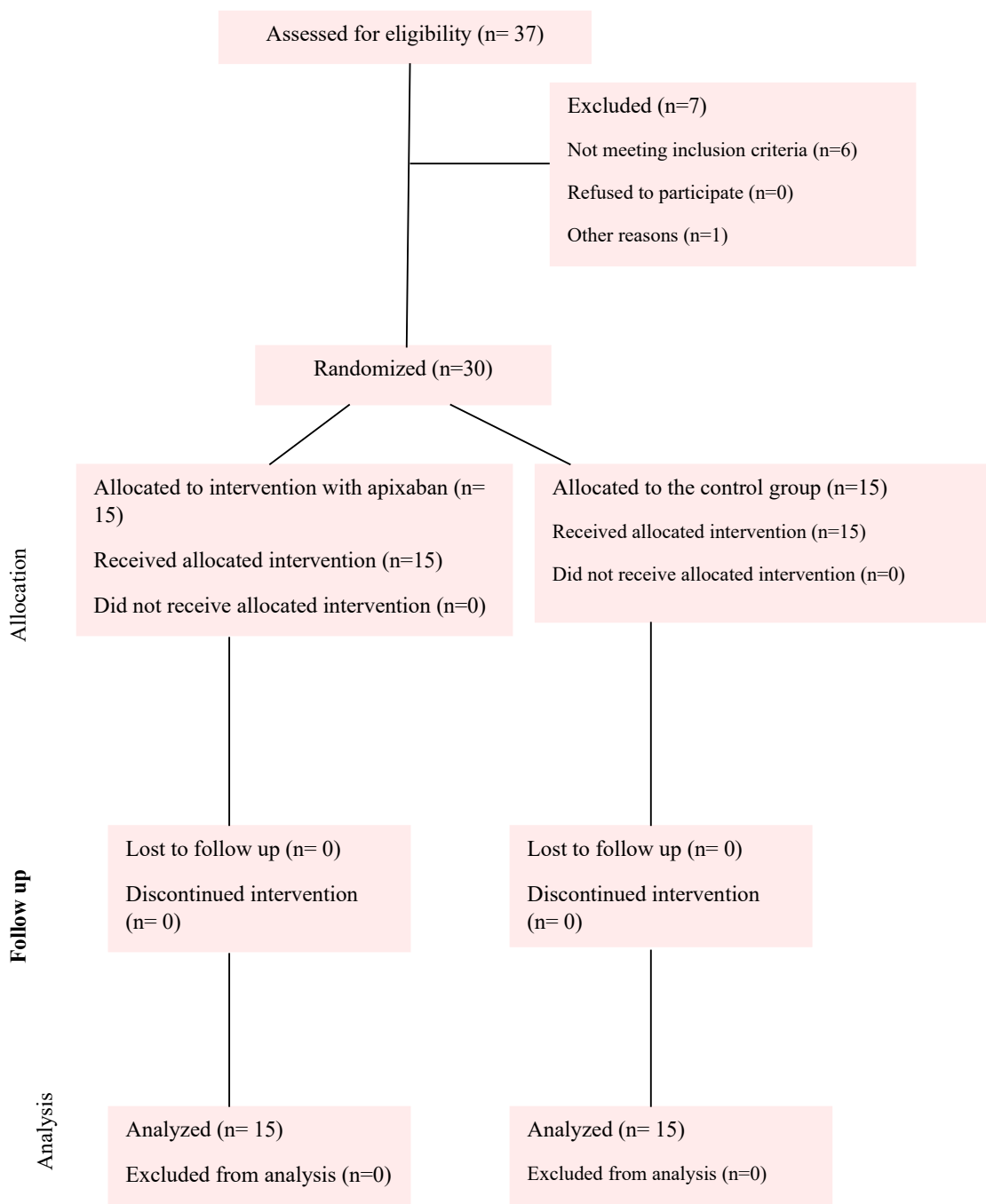


Figure 1. Consort diagram of the studied population

The patients were divided into two groups: those receiving apixaban and the control group, following a conservative approach. The two groups were similar in terms of demographic characteristics (P-value>0.05), except for gender distribution (P-value=0.025). Additionally, there were no significant differences between the groups regarding chronic medical conditions (P-value>0.05), medication history (P-value>0.05), duration of coronary angiography (P-value=0.418), and baseline radial artery diameter (P-value=0.25). Further details are presented in Table 1. The mean radial artery diameter in male patients was measured as 2.85 ± 0.56 (range:

2.20-3.30), while in female patients, it was 2.61 ± 0.60 (range: 2.10-3.30).

The study aimed to assess factors contributing to recanalization regardless of the treatment approach for RAO. The analysis indicated that neither demographic nor medical, nor clinical factors had a significant influence on radial artery patency after occlusion due to coronary angiography (P-value>0.05) (Table 2).

As the main objective of the study, recanalization occurred in 13 cases (86.7%) in the apixaban treatment group compared to 8 individuals (53.3%) in the control group, demonstrating a statistically significant difference (P-value=0.046).

Table 1. The baseline characteristics of the study population

Variable	Control (n=15)	Treatment with Apixaban (n=15)	P-value
Demographic characteristics			
Age (years), mean (standard deviation)	59.73 (11.43)	59.14 (12.85)	0.897 [¥]
Gender, n (%)	Female	3 (20)	0.025*
	Male	12 (80)	
BMI (kg/m ²), mean (standard deviation)	26.93(3.12)	28.31(4.97)	0.372 [¥]
Smoking, n (%)	1 (6.7)	6 (40)	0.080**
Chronic medical disease and medications			
Diabetes, n (%)	4 (26.7)	6 (40)	0.439*
Hypertension, n (%)	4 (26.7)	8 (53.3)	0.136*
Statins, n (%)	11 (73.3)	14 (93.3)	0.330**
Antiplatelet therapy, n (%)	DAPT	2 (13.3)	0.999**
	SAPT	13 (86.7)	
Clinical characteristics			
Procedure time (minutes), mean (standard deviation)	23.38 (11.64)	31.92 (8.54)	0.418 [€]
Artery diameter (mm), mean (standard deviation)	2.70 (0.37)	2.8 (0.34)	0.250 [€]

*Chi-Square

**Fisher's Exact Test

¥ t-test

€Mann-Whitney Test

Table 2. The factors associated with recanalization

Variable	Recanalization (n=21)	Persistent RAO (n=9)	P-value
Demographic characteristics			
Age (years), mean (standard deviation)	60.14 (11.59)	57.63 (13.41)	0.620 [‡]
Gender, n (%)	Female	4 (44.4)	0.745*
	Male	5 (55.6)	
BMI (kg/m ²), mean (standard deviation)	27.02 (3.12)	29.01 (5.88)	0.233 [‡]
Smoking, n (%)	4 (19)	3 (33.3)	0.640**
Chronic medical disease and medications			
Diabetes, n (%)	7 (33.3)	3 (33.3)	0.999*
Hypertension, n (%)	8 (38.1)	4 (44.4)	0.745*
Statins, n (%)	17 (81)	8 (88.9)	0.999**
Antiplatelet therapy, n (%)	DAPT	1 (11.1)	0.999**
	SAPT	8 (88.9)	
Clinical characteristics			
Procedure time (minutes), mean (standard deviation)	34.44 (9.98)	27 (8.48)	0.216 [€]
Artery diameter (mm), mean (standard deviation)	2.73 (0.35)	2.91 (0.36)	0.304 [€]

*Chi-Square

**Fisher's Exact Test

‡t-test

€Mann-Whitney Test

Discussion

The findings of this pilot double-blinded clinical trial suggested that a one-month treatment with apixaban, at a dose of 2.5 mg twice daily, appeared to be effective in achieving radial artery patency resolution in patients with radial artery occlusion (RAO) following coronary angiography through the radial artery route. The study aimed to assess the therapeutic approach to post-coronary angiography RAO and its contributing factors, and it revealed that none of the demographic, medical, medication, and clinical factors were associated with the incidence of RAO.

RAO incidence rates reported in the literature vary widely due to its subtle nature of presentation and potential for spontaneous resolution. RAO can occur within hours to a week after transradial angiography, even when the radial artery pulse is palpable, contributing to the underdiagnosis of RAO. Failure to routinely screen arterial patency in post-procedure settings is another reason for its

underdiagnosis¹³.

Some authors have proposed prophylactic strategies, including intraarterial/subcutaneous vasodilators before or after the procedure, and reported contradictory outcomes^{14, 15}. Since RAO resulting from thrombus formation should be approached similarly to venous thrombotic events, anticoagulants such as injectable enoxaparin or fondaparinux can be used⁹. Low molecular weight heparin has shown promising outcomes, but it requires several subcutaneous injections during treatment^{11, 12, 16, 17}. Numerous studies are currently being conducted to prevent RAO rather than focusing on its treatment, with conflicting results.

Recently, direct-acting oral anticoagulants (DOACs), including dabigatran, rivaroxaban, apixaban, and edoxaban, have gained attention for the treatment of venous thromboembolism due to their safety profile, lack of requirement for monitoring, minimal dietary restrictions, and minimal drug interactions. However, their use is limited by moderate-to-severe renal

function impairment. Data on the use of DOACs for RAO treatment are still limited¹⁸. Studies by Roy *et al.* and Rammos *et al.* have reported similar findings to this study, showing complete patency resolution in RAO patients following transradial angiography using apixaban and other anticoagulants^{18,19}. Another study using prophylactic rivaroxaban therapy immediately after transradial angiography showed improved 1-month RAO outcomes²⁰. However, Schlosser *et al.* reported limited benefits of oral anticoagulant use in RAO patients receiving various DOACs²¹. The optimal duration of therapy for RAO remains a subject of debate, with the expected duration of DOAC use for venous thromboembolism being 90 days, which also seems reasonable for RAO¹⁸.

In this study, no factors were associated with RAO resolution, including age, gender, BMI, smoking, diabetes, hypertension, statin use, single or dual antiplatelet therapy, length of the index intervention, and radial artery diameter. However, most studies have focused on factors associated with RAO incidence rather than resolution. Female gender, active smoking, diabetes, lower BMI, and radial artery diameter ≤ 2.2 mm have been identified as predictors of RAO incidence^{21, 22}. In other studies, hypertension and preprocedural radial artery diameter < 2.5 mm have also been associated with RAO incidence^{23, 24}. To the authors' knowledge, no previous studies have focused explicitly on factors associated with arterial resolution.

The mean radial artery diameter in male patients was measured as 2.85 ± 0.56 (range: 2.20-3.30), while in female patients, it was 2.61 ± 0.60 (range: 2.10-3.30) which is not significantly different from the global average⁷.

Limitations

The limitations of this study include the need for more assessment of potential confounding factors and the relatively short duration of follow-up. More extensive trials with extended follow-up periods involving various DOACs

and comparing different doses of each DOAC are strongly recommended to further explore RAO treatment.

Conclusion

The findings of this study suggest that a one-month treatment with apixaban, at a dose of 2.5 mg twice daily, can effectively lead to radial artery patency resolution in patients with RAO following coronary angiography. Further studies are needed to validate these findings and provide more comprehensive insights into the management of RAO.

Acknowledgment

The authors would like to express their sincere appreciation to the officials and nurses of the Coronary Artery Angiography Department at Shahid Chamran Cardiology Center, affiliated with Isfahan University of Medical Sciences.

Financial support

This study was supported by Isfahan University of Medical Sciences with grant number 3401378.

Authors' contribution

A. A. contributed in the conception of the work, conducting the study, revising the draft, approval of the final version of the manuscript, and agreed for all aspects of the work

R. Z. contributed in the conception of the work, conducting the study, revising the draft, approval of the final version of the manuscript, and agreed for all aspects of the work

A. S. contributed in the conception of the work, conducting the study, revising the draft, approval of the final version of the manuscript, and agreed for all aspects of the work

M. S. contributed in the revising the draft, approval of the final version of the manuscript, and agreed for all aspects of the work

E. Sh. contributed in conducting the study

M. K. Al. in conducting the study

H. S. in conducting the study
 S. M. H. J. in conducting the study
 A. P. in conducting the study
 A. Kh. F. in conducting the study
 E. Z. contributed in conducting the study, revising the draft, approval of the final version of the manuscript, and agreed for all aspects of the work
 A. S. contributed in the conception of the work, conducting the study, revising the draft, and agreed for all aspects of the work
 R. H. contributed in the conception of the work and data analysis

References

1. Campeau L. Percutaneous radial artery approach for coronary angiography. *Catheter Cardiovasc Diagn* 1989; 16(1): 3-7. <https://doi.org/10.1002/ccd.1810160103>
2. Kiemeneij F, Laarman GJ, de Melker E. Transradial artery coronary angioplasty. *Am Heart J* 1995; 129(1): 1-7. [https://doi.org/10.1016/0002-8703\(95\)90034-9](https://doi.org/10.1016/0002-8703(95)90034-9)
3. Kiemeneij F, Laarman GJ, Odekerken D, Slagboom T, van der Wieken R. A randomized comparison of percutaneous transluminal coronary angioplasty by the radial, brachial and femoral approaches: the access study. *J Am Coll Cardiol* 1997; 29(6): 1269-75. [https://doi.org/10.1016/S0735-1097\(97\)00064-8](https://doi.org/10.1016/S0735-1097(97)00064-8)
4. Di Santo P, Simard T, Wells GA, Jung RG, Ramirez FD, Boland P, et al. Transradial versus transfemoral access for percutaneous coronary intervention in ST-segment-elevation myocardial infarction: a systematic review and meta-analysis. *Circ Cardiovasc Interv* 2021; 14(3): e009994. <https://doi.org/10.1161/CIRCINTERVENTIONS.120.009994>
5. Steinmetz M, Radecke T, Boss T, Stumpf MJ, Lortz J, Nickenig G, et al. Radial artery occlusion after cardiac catheterization and impact of medical treatment. *Vasa*. 2020;49(6):463-6. <https://doi.org/10.1024/0301-1526/a000892>
6. Bolorunduro O, Bob-Manuel T, Cheema Y, Raza A, Khouzam R. Gaining a new skill with the risk of losing one: the effect of radial catheterization. *Curr Probl Cardiol* 2016; 41(5): 195-203. <https://doi.org/10.1016/j.cpcardiol.2016.07.001>
7. Nguyen P, Makris A, Hennessy A, Jayanti S, Wang A, Park K, et al. Standard versus ultrasound-guided radial and femoral access in coronary angiography and intervention (SURF): a randomised controlled trial. *EuroIntervention* 2019; 15(6): e522-e30. <https://doi.org/10.4244/EIJ-D-19-00336>
8. Wagener JF, Rao SV. Radial artery occlusion after transradial approach to cardiac catheterization. *Curr Atheroscler Rep* 2015; 17: 1-8. <https://doi.org/10.1007/s11883-015-0489-6>
9. Goswami R, Oliphant CS, Youssef H, Morsy M, Khouzam RN. Radial artery occlusion after cardiac catheterization: significance, risk factors, and management. *Curr Probl Cardiol* 2016; 41(6): 214-27. <https://doi.org/10.1016/j.cpcardiol.2016.09.002>
10. Lavi S, Cheema A, Yadegari A, Israeli Z, Levi Y, Wall S, et al. Randomized trial of compression duration after transradial cardiac catheterization and intervention. *J Am Heart Assoc* 2017; 6(2): e005029. <https://doi.org/10.1161/JAHA.116.005029>
11. Uhlemann M, Gielen S, Woitek FJ, Moebius-Winkler S, Linke A, Schuler GC, editors. Impact of low molecular weight heparin on reperfusion rates in patients with radial artery occlusion after cardiac catheterization. Results and follow-up in 113 patients. *J Am Coll Cardiol* 2011, 58 (20_Supplement) B143.
12. Zankl A, Andrassy M, Volz C, Ivandic B, Krumsdorf U, Katus H, et al. Radial artery thrombosis following transradial coronary angiography: incidence and rationale for treatment of symptomatic patients with low-molecular-weight heparins. *Clin Res Cardiol* 2010; 99: 841-7. <https://doi.org/10.1007/s00392-010-0197-8>
13. Didagelos M, Pagiantza A, Zegkos T, Papanastasiou C, Zarra K, Angelopoulos V, et al. Low-molecular-weight heparin in radial artery occlusion treatment: the LOW-RAO randomized study. *Future Cardiol* 2021; 18(2): 91-100. <https://doi.org/10.2217/fca-2021-0067>
14. Dharma S, Kedev S, Patel T, Kiemeneij F, Gilchrist IC. A novel approach to reduce radial artery occlusion after transradial catheterization: postprocedural/prehemostasis intra-arterial nitroglycerin. *Catheter Cardiovasc Interv* 2015; 85(5): 818-25. <https://doi.org/10.1002/ccd.25661>
15. Chen Y, Ke Z, Xiao J, Lin M, Huang X, Yan C, et al. Subcutaneous injection of nitroglycerin at the radial artery puncture site reduces the risk of early radial artery occlusion after transradial coronary catheterization: a randomized, placebo-controlled clinical trial. *Circ Cardiovasc Interv* 2018; 11(7): e006571. <https://doi.org/10.1161/>

- CIRCINTERVENTIONS.118.006571
16. Beyranvand M, Mohammadi Z, Piranfar MA, Gachkar L. Effects of Verapamil on the Reduction of Radial Artery Thrombosis after Coronary Angiography: A Randomized Clinical Trial. *J Tehran Univ Heart Cent* 2022; 17(4): 180-5. <https://doi.org/10.18502/jthc.v17i4.11604>
 17. Dwivedi SK, Sharma AK, Nayak GR, Chaudhary GK, Chandra S, Pradhan A, et al. Factors influencing radial artery occlusion after transradial coronary intervention in the Indian population. *Anatol J Cardiol* 2022; 26(2): 105.
 18. Rammos C, Burghardt A, Lortz J, Azizy O, Jánosi R, Steinmetz M, et al. Impact of anticoagulation and vasoactive medication on regained radial artery patency after catheterization: a case-control study. *Eur J Med Res* 2018; 23: 1-6. <https://doi.org/10.1186/s40001-018-0324-y>
 19. Roy S, Choxi R, Wasilewski M, Jovin IS. Novel oral anticoagulants in the treatment of radial artery occlusion. *Catheter Cardiovasc Interv* 2021; 98(6): 1133-7. <https://doi.org/10.1002/ccd.29771>
 20. Liang D, Lin Q, Zhu Q, Zhou X, Fang Y, Wang L, et al. Short-term postoperative use of rivaroxaban to prevent radial artery occlusion after transradial coronary procedure: the RESTORE randomized trial. *Circ Cardiovasc Interv* 2022; 15(4): e011555. <https://doi.org/10.1161/CIRCINTERVENTIONS.121.011555>
 21. Schlosser J, Herrmann L, Böhme T, Bürgelin K, Löffelhardt N, Nührenberg T, et al. Incidence and predictors of radial artery occlusion following transradial coronary angiography: the proRadial trial. *Clin Res Cardiol* 2023;112(9):1175-85. <https://doi.org/10.1007/s00392-022-02094-z>
 22. Sinha SK, Jha MJ, Mishra V, Thakur R, Goel A, Kumar A, et al. Radial artery occlusion-incidence, predictors and long-term outcome after transradial catheterization: clinico-Doppler ultrasound-based study (RAIL-TRAC study). *Acta Cardiol* 2017; 72(3): 318-27. <https://doi.org/10.1080/00015385.2017.1305158>
 23. Garg N, Madan B, Khanna R, Sinha A, Kapoor A, Tewari S, et al. Incidence and predictors of radial artery occlusion after transradial coronary angioplasty: Doppler-guided follow-up study. *J Invasive Cardiol* 2015;27(2):106-12.
 24. Buturak A, Gorgulu S, Norgaz T, Voyvoda N, Sahingoz Y, Degirmencioglu A, et al. The long-term incidence and predictors of radial artery occlusion following a transradial coronary procedure. *Cardiol J* 2014; 21(4): 350-6. <https://doi.org/10.5603/CJ.a2013.0128>

How to cite this article: Amirpour A, Zavar R, Seifipour A, Sadeghi M, Shirvani E, Kermani-Alghoraishi M, et al. **Apixaban, a Novel Oral Anticoagulant, Use to Resolute Arterial Patency in Radial Artery Occlusion Due to Cardiac Catheterization; A Pilot Randomized Clinical Trial.** *ARYA Atheroscler* 2023; 19(6): 18-26.