

Reversible left bundle branch block should be mentioned in cardiac resynchronization therapy; A clinical case report

Ali Vasheghani-Farahani⁽¹⁾, Masih Tajdini⁽²⁾, Seyed Abolfazl Mohsenizadeh⁽²⁾, Seyed Mohammad Reza Hosseini⁽³⁾

Case Report

Abstract

BACKGROUND: Cardiac resynchronization therapy (CRT) is a medical device to help cardiac synchronized contractility by electrical impulses. Improvement of symptoms and left ventricular systolic function, reducing hospital admissions and mortality in patients with moderate to severe heart failure are the main benefits of administration of cardiac resynchronization therapy.

CASE REPORT: In this article, we describe a case of heart failure and left bundle branch block (LBBB) who was candidate for cardiac resynchronization therapy; but after managing hyperkalemia, left bundle branch block resolved, ejection fraction increased and cardiac resynchronization therapy implantation was canceled.

CONCLUSION: Exclusion of treatable causes is the first important step before any interventions. Now there is an important question; is cardiac resynchronization therapy effective in patients with heart failure and transient or intermittent left bundle branch block?

Keywords: Reversible Left Bundle Branch Block, Cardiac Resynchronization Therapy, Hyperkalemia

Date of submission: 2 Mar 2015, *Date of acceptance:* 15 Apr 2016

Introduction

Wide QRS, mainly left bundle branch block (LBBB) is an independent predictor of adverse prognosis in patients with heart failure. Cardiac resynchronization therapy (CRT) is a medical device to help cardiac synchronized contractility by electrical impulses.¹

CRT is indicated for patients who have left ventricular ejection fraction of less than 35 percent, LBBB with QRS duration of ≥ 120 ms (especially when is more than 150 ms) and New York Heart Association (NYHA) of class II, III, or ambulatory IV symptoms while receiving guideline-directed medical therapy (GDMT).²

Case Report

A 71-year-old woman referred to our clinic with dyspnea on exertion (DOE). Her dyspnea was progressed from class II to IV during the last month (based on NYHA classification). Past medical history was positive for hypertension

and hypothyroidism. She was under heart failure regimen drugs [angiotensin II receptor blocker (ARB), aldosterone antagonist, digoxin, diuretic and beta blocker], and prednisolone for her thyroid-related ophthalmopathy condition.

On physical examination, holosystolic murmur in left sternal border (LSB) and coarse crackle on both lungs was heard. About + to ++ non-pitting edema was observed in lower limbs. Electrocardiogram (ECG) was in favor of normal sinus rhythm, left axis deviation, LBBB pattern with QRS duration of approximately 160 ms and wide base tall T waves in precordial leads (Figure 1).

Echocardiographic evaluations including tissue doppler imaging (TDI) and tissue synchronization imaging (TSI) were suggested significant intraventricular and interventricular dyssynchrony and ejection fraction of about 30 percent.

Due to these findings and based on 2012 American College of Cardiology Foundation/American Heart Association/Heart

1- Associate Professor, Tehran Heart Center AND Department of Cardiology, Tehran University of Medical Sciences, Tehran, Iran

2- Resident, Tehran Heart Center AND Department of Cardiology, Tehran University of Medical Sciences, Tehran, Iran

3- General Practitioner, Department of Radiology, Massachusetts General Hospital, Boston, MI

Correspondence to: Masih Tajdini, Email: drmasih84@yahoo.com

Rhythm Society (ACCF/AHA/HRS) Guidelines for Device-Based Therapy of Cardiac Rhythm Abnormalities, the patient was candidate for CRT.

Routine laboratory tests such as electrolytes level, creatinine, complete blood count, coagulation tests, thyroid function tests and digoxin level were requested. All of aforementioned lab results were in normal ranges except potassium ($k = 7.49$ mEq/l), hemoglobin [10.3 g/l with mean corpuscular

volume (MCV) of 85 fl] and creatinine (Cr = 1.52 mg/dl).

Therefore, acute treatment strategies were started for hyperkalemia. After treatment, the level of potassium was dropped to 4.3 mEq/l. Surprisingly, ECG converted to normal sinus rhythm with normal QRS duration and no ST-T changes (Figure 2). Echocardiography was done again and revealed an ejection fraction of about 40 percent.

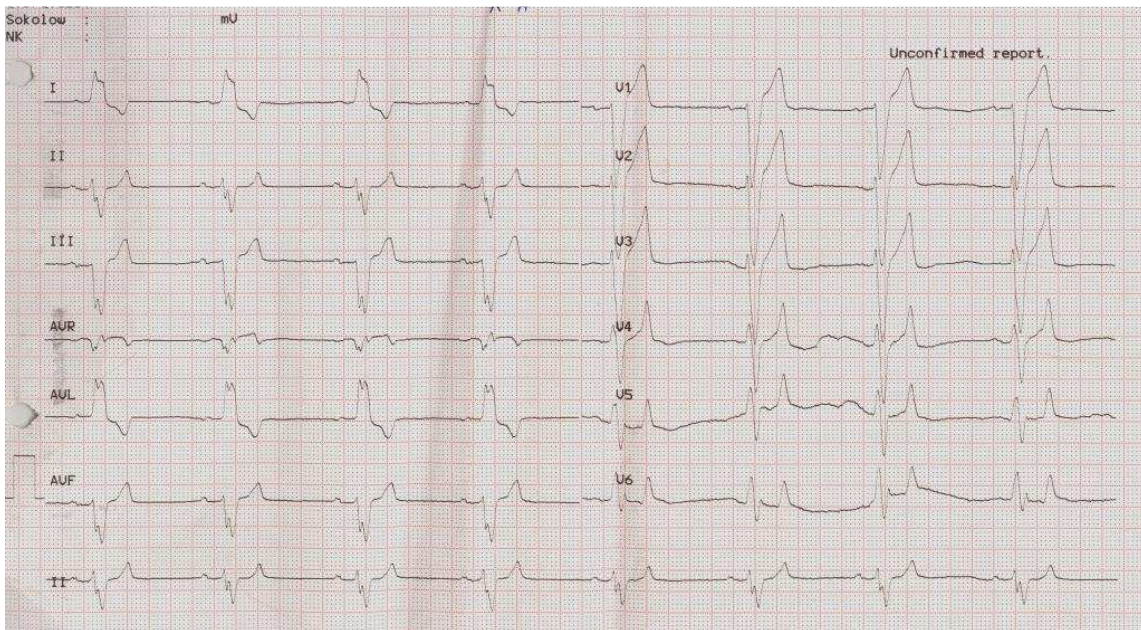


Figure 1. With this the patient was candidate for cardiac resynchronization therapy (CRT)

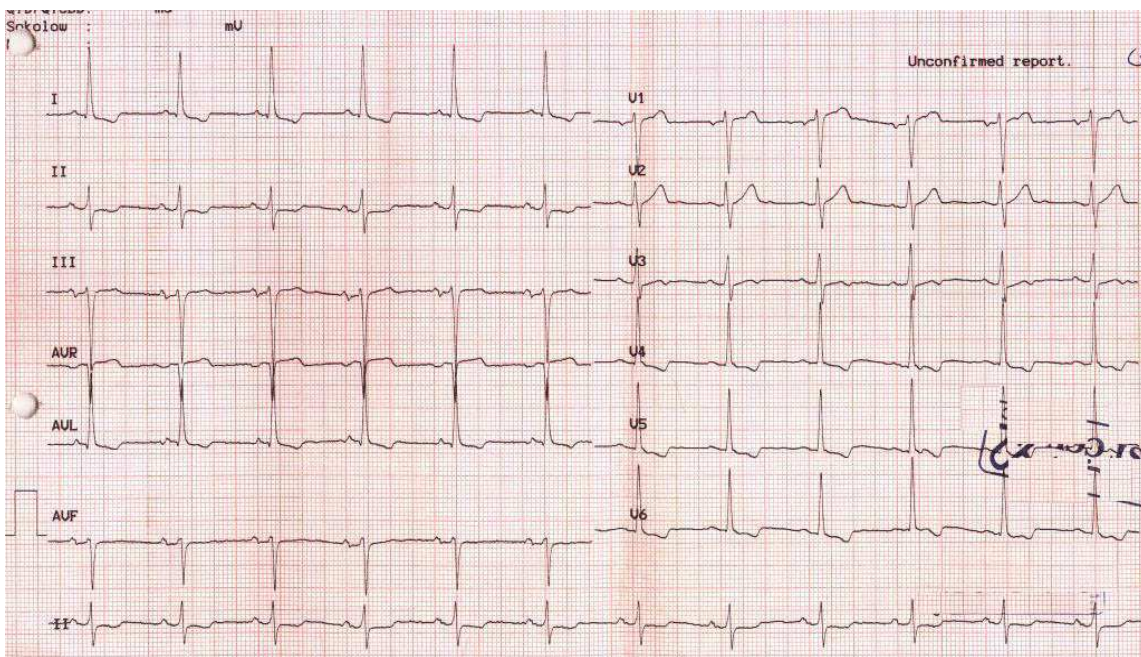


Figure 2. After potassium level correction

Discussion

Improvement of symptoms and left ventricular systolic function, reducing hospital admissions and mortality in patients with moderate to severe heart failure are the main benefits of CRT administration.³

Potassium level of more than 5.5 mEq/l is defined as hyperkalemia. Hyperkalemia has different causes but most often, it is due to renal impairment of potassium excretion, potassium sparing drugs (such as renin-angiotensin inhibitors and aldosterone antagonist diuretics) and cellular release of potassium. Hyperkalemia has different effects on ECG including narrow and tall T wave, shortening of QT interval, QRS widening, prolonged PR interval and loss of P wave.⁴

Based on our literature search, except hyperkalemia there are some causes of transient LBBB; a) Thyrotoxicosis, in a case report, LBBB in a young woman resolved by thyrotoxicosis treatment;⁵ b) Rate-dependent bundle branch block that may happen with tachycardia in the setting of heart failure decompensation;⁶ c) Acute carbon monoxide poisoning;⁷ d) Vasospasm;⁸ and e) Left coronary fistula.⁹

Our patient had transient LBBB due to hyperkalemia. We recognized chronic hyperkalemia as the main etiology of wide QRS in our patient. The ECG turned back to normal after K level was corrected. CRT was not a treatment of choice for this patient as result of acceptable ejection fraction and narrow QRS. So, exclusion of treatable causes is the first important step before any interventions. Now there is an important question; is CRT effective in patients with heart failure and transient or intermittent left bundle branch block?

Acknowledgments

We would like to express our special thanks to the staff of Department of Cardiology, Tehran Heart Center, Tehran, Iran.

Conflict of Interests

Authors have no conflict of interests.

References

1. Willis HJ. Left bundle-branch block-pathophysiology, prognosis, and clinical management. *Clin Cardiol* 2007; 30(10): 535.
2. Tracy CM, Epstein AE, Darbar D, Dimarco JP, Dunbar SB, Estes NA 3rd, et al. 2012 ACCF/AHA/HRS focused update of the 2008 guidelines for device-based therapy of cardiac rhythm abnormalities: a report of the American College of Cardiology Foundation/American Heart Association Task Force on Practice Guidelines. *J Am Coll Cardiol* 2012; 60(14): 1297-313.
3. St John Sutton MG, Plappert T, Abraham WT, Smith AL, DeLurgio DB, Leon AR, et al. Effect of cardiac resynchronization therapy on left ventricular size and function in chronic heart failure. *Circulation* 2003; 107(15): 1985-90.
4. Diercks DB, Shumaik GM, Harrigan RA, Brady WJ, Chan TC. Electrocardiographic manifestations: electrolyte abnormalities. *J Emerg Med* 2004; 27(2): 153-60.
5. Wilmot E, Sagili V, Sturrock N. An rare cause of reversible left bundle branch block. *Endocrine Abstracts* 2007; 13: 23.
6. Fisher JD, Aronson RS. Rate-dependent bundle branch block: occurrence, causes and clinical correlations. *J Am Coll Cardiol* 1990; 16(1): 240-3.
7. Parenti N, Binetti N, Lenzi T. "Reversible" left bundle branch block in acute carbon monoxide poisoning. *Intern Emerg Med* 2006; 1(2): 172-3.
8. Alhaji M. Intermittent left bundle branch block caused by coronary vasospasm. *Avicenna J Med* 2013; 3(2): 50-2.
9. Juraschek SP, Kovell LC, Childers RE, Chow GV, Hirsch GA. Heart failure with transient left bundle branch block in the setting of left coronary fistula. *Cardiol Res Pract* 2011; 2011: 786287.

How to cite this article: Vasheghani-Farahani A, Tajdini M, Mohsenizadeh SA, Hosseini SMR. **Reversible left bundle branch block should be mentioned in cardiac resynchronization therapy; A clinical case report.** *ARYA Atheroscler* 2016; 12(3): 153-5.