

A rare case of intracardiac metastasis of uterine leiomyosarcoma

Khadije Mohammadi MD, Shirin Jafari MD, Fatemeh Jafari

Case Image

Date of submission: 01 Oct. 2019, *Date of acceptance:* 26 June 2020

Case presentation

A 56-year-old woman with past medical history of uterine leiomyosarcoma for 4 years ago, referred us for echocardiography to evaluate cardiac function. She was on chemotherapy regimen, but dropped out her treatment 11 months ago due to fear of COVID infection.

According to her past medical documents, she also had a history of lung metastasis about 3 years ago that resolved completely with chemotherapy (ifosfamide) and after that, she had been undergone regular interval of chemotherapy until she dropped it. She had no clinical evidence of systemic emboli and just complained of exertional dyspnea.

In her trans thoracic echocardiography we found a fixed large (2 *3.2cm) mass in Left Atrium (LA) (Figure-1a and 1b, movie-1) and also an elongated hypermobile (3.87 cm) mass in LA with protrusion to Left Ventricle (Figure 1a and 1c). The patient

underwent trans esophageal echocardiography with suspected metastatic tumor or thrombus that revealed elongated mass was originated from left upper pulmonary vein (LUPV) and demonstrated extension of lung mass lesions through PV (movie-2) when compared with chest Computed Tomography (CT); in chest CT (movie-3), multiple scattered variable size nodules and masses were observed in both lungs that could cause metastatic lesions and one of them was cavitary in left side. Anticoagulation and chemotherapy were started for the patient but the patient refused to continue treatment and follow up.

How to cite this article: Mohammadi Kh., Jafari Sh., Jafari F. **A rare case of intracardiac metastasis of uterine leiomyosarcoma.** ARYA Atheroscler 2022; 18: 1-2.

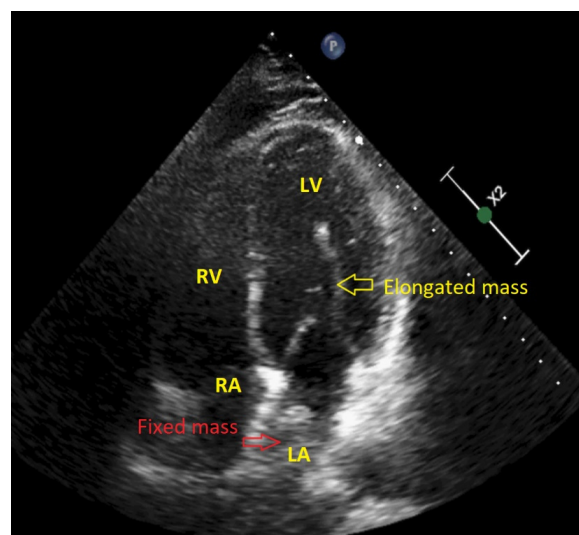


Figure 1a. Apical 4 chamber view of trans thoracic echocardiography that revealed a large fixed mass in left atrium (red arrow) and also an elongated hypermobile mass that protrude from atrium to ventricle (yellow arrow)

1- Cardiovascular Research Center, Kerman University of Medical Sciences, Kerman, Iran

Address for correspondence: Khadije Mohammadi; Cardiovascular Research Center, Shafa Hospital, Shafa Avenue, Kerman, Iran; Email: khma_65@yahoo.com

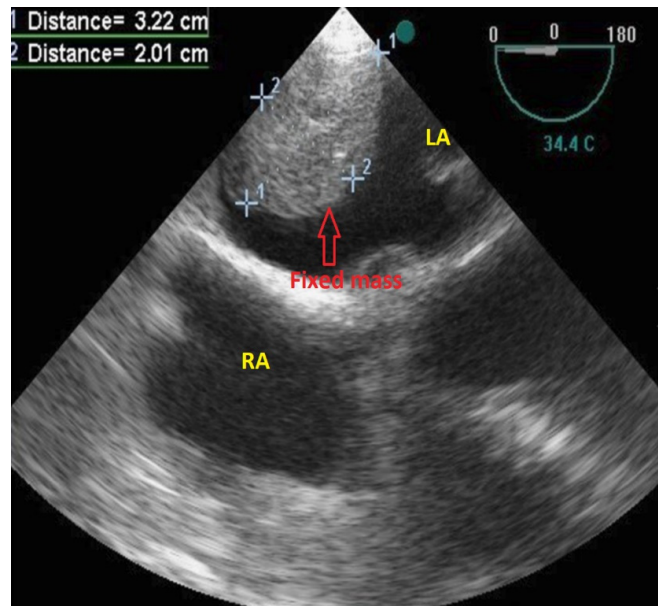


Figure 1b. Trans esophageal echocardiography that showed a large (3.2*2cm) fixed mass in LA

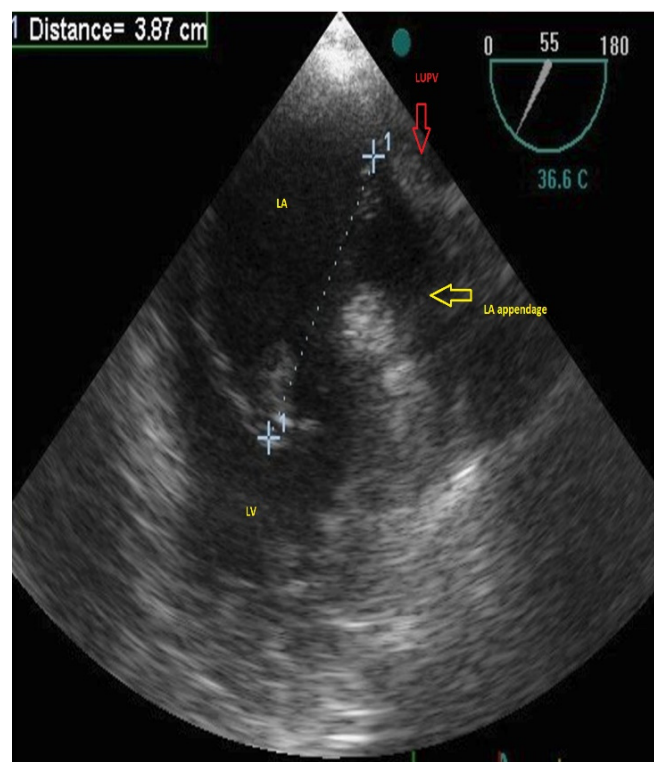


Figure 1c. Trans esophageal echocardiography showed elongated mass originated from LUPV and protruded to LV.

LA: Left Atrium, LUPV: Left Upper Pulmonary Vein, RA: Right Atrium, RV: Right Ventricle, LV: Left ventricle