

## Endovascular repair of an abdominal aortic aneurysm under local anesthesia using bifurcated stent graft in a patient with iliac artery chronic occlusion: A case report

Seyhan Yilmaz MD <sup>(1)</sup>, İsa Çam MD <sup>(2)</sup>, Sabür Zengin MD <sup>(3)</sup>

### Case Report

#### Abstract

**BACKGROUND:** There are some clinical conditions described in literature which limit the application of full endovascular aneurysm repair, and the most important of these limitations are inappropriately short and angled aneurysm neck, narrow terminal aorta, and curved and very small diameter or highly calcified iliac arteries that make access difficult, and unilateral iliac artery occlusion is another one of these limitations, which is less frequently observed.

**CASE REPORT:** In our case report, we present a patient whose abdominal aortic aneurysm was considered to be high risk for classical open surgical repair. Our patient has a unilateral iliac artery occlusion co-existing with abdominal aortic aneurysm and the occluded left common iliac artery and severely stenotic external iliac artery segment was applied percutaneous transluminal balloon dilatation and after which abdominal aortic aneurysm was successfully treated with standard endovascular aneurysm repair.

**CONCLUSION:** A standard successful endovascular aneurysm repair procedure was applied for the patient who did not develop any intraoperative complications. The left iliac artery blood flow was also ensured by the dilatation of occluded iliac artery segment, simultaneously. When there are such limitations related to the iliac artery as iliac artery occlusion, the standard endovascular aneurysm repair procedure combined with invasive techniques for iliac artery revascularization is a practical and safe treatment option which reduces the procedural morbidity and mortality compared to the other treatment options.

**Keywords:** Endovascular Aneurysm Repair; Iliac Artery Occlusive Disease; Balloon Dilatation; Surgical Repair

*Date of submission:* 17-Feb-2021, *Date of acceptance:* 31-Oct-2022

#### Introduction

It is reported that Endovascular Aneurysm Repair (EVAR), which is known to be a safe and effective treatment option in the treatment of abdominal aortic aneurysms (AAA), has lower morbidity and mortality rates compared to conventional open surgery and it has become the first treatment option in the treatment of anatomically appropriate infrarenal AAA patients <sup>1-4</sup>. However, there are some clinical conditions described in literature which limit the application of full EVAR. The most important of these limitations are inappropriately short and angled aneurysm neck, narrow terminal aorta, and

curved and very small diameter or highly calcified iliac arteries that make access difficult. Moreover, unilateral iliac artery occlusion is another one of these limitations which is less frequently seen. <sup>1,3-5</sup> In case of co-existence of unilateral iliac artery occlusive disease with AAA, femorofemoral bypass operation combined with aorto-uni-iliac endograft (AUI) is

**How to cite this article:** Yilmaz S, Çam I, Zengin S. Endovascular repair of an abdominal aortic aneurysm under local anesthesia using bifurcated stent graft in a patient with iliac artery chronic occlusion: A case report. ARYA Atheroscler 2022; 18(5): 2382.

1. Çorlu Province Hospital, Department of Cardiovascular Surgery, Tekirdağ, Turkey

2. Assoc. Prof. Dr., Kocaeli University Faculty of Medicine, Department of Radiology, Kocaeli, Turkey

3. Kırıkkale Yüksek İhtisas Hospital, Department of Cardiovascular Surgery, Kırıkkale, Turkey

Address for correspondence: Sabür Zengin; Amasya Sabuncuoğlu Şerefeddin Education And Research Hospital, Amasya, Turkey;

Email: dr\_sgb@hotmail.com

reported to have success rates similar to classical open surgical repair or treatment with bifurcation stents<sup>3,6</sup> in selected patients as a treatment option with natural risks and it is stated to be more appropriate in high-risk patients<sup>1,3,7,8</sup>. Some disadvantages of AUI and Femorofemoral bypass procedure are also reported in these patients<sup>3,9</sup>, and percutaneous transluminal balloon dilatation is not a routine method in patients with unilateral iliac artery occlusion before EVAR and to our knowledge, there are not much articles about this technique in literature<sup>1,7</sup>.

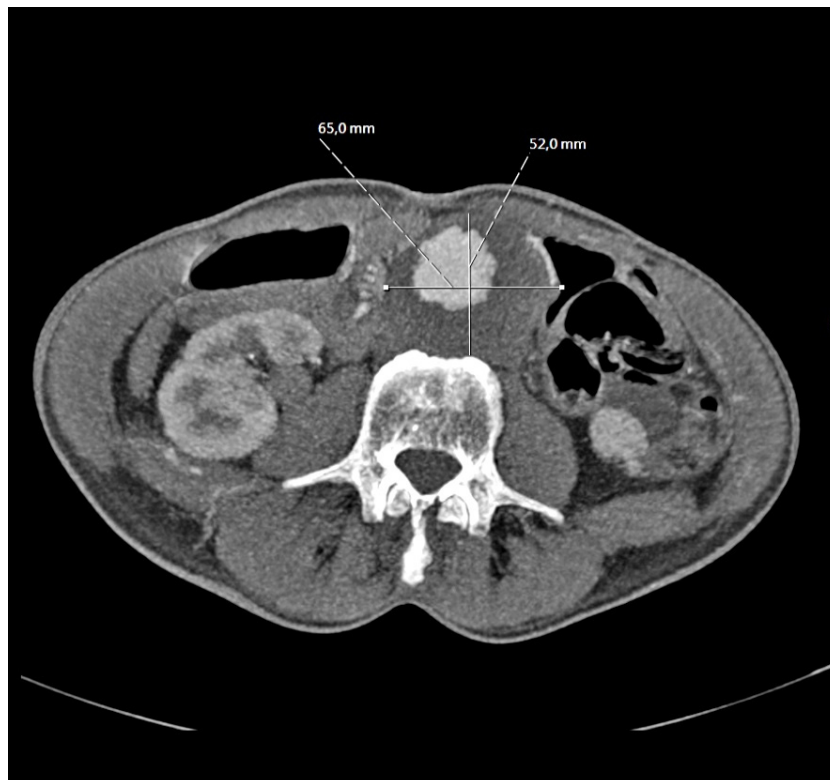In our case report, we present a patient, whose AAA was considered to be high risk for classical open surgical repair, with AAA co-existing with unilateral iliac artery occlusion, that the occluded left common iliac artery (CIA) and severely stenotic external iliac artery (EIA) segment were applied percutaneous transluminal balloon dilatation and after which AAA was successfully treated with standard EVAR.

### Case Report

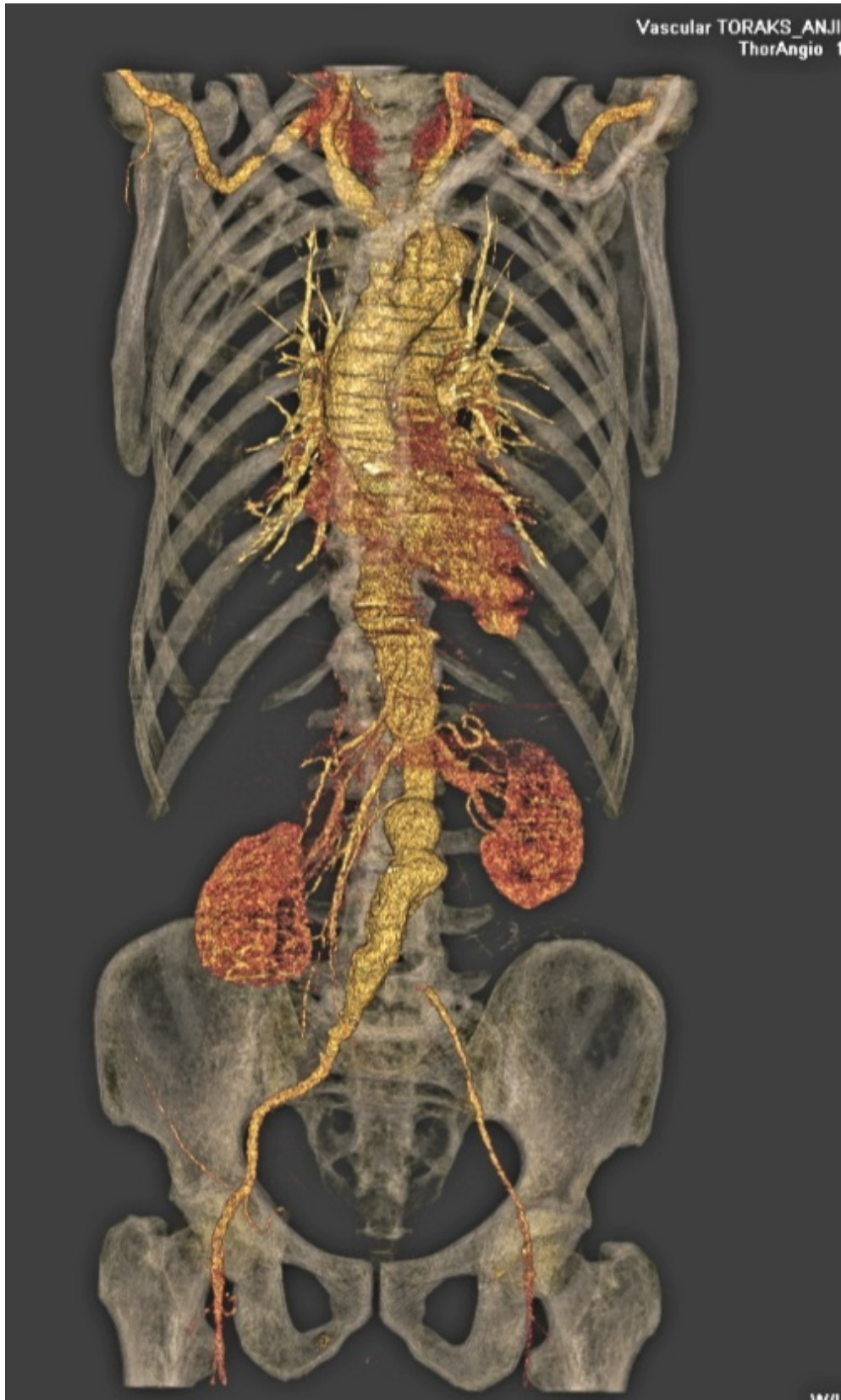A 65-year-old male patient, who is smoker, was referred to our Cardiovascular Surgery outpatient clinic after the detection of infrarenal AAA of 65 mm diameter in computed tomography arteriography (CTA) examination at an external center that he consulted about 1 month ago with complaints of abdominal and leg pain.

In his anamnesis, it was learned that the life-limiting leg pain of the patient with accompanying coronary artery disease, chronic obstructive pulmonary disease, hypertension and hyperlipidemia had been present for a few years and increased further in time (rest pain was also present), and abdominal pain had been present for about 2 months. In the examination, it was found that there was no significant abnormality in laboratory tests including urea / creatinine, and his walking distance was less than 100 meters. In the physical examination of the patient, a pulsatile mass was palpated in abdomen, there was no defense / rebound sign detected, and the left femoral artery pulse was found to be nonpalpable. In our evaluation of the CTA, we found that there was an infrarenal AAA (extending to the right CIA) with an approximate diameter of 6.5 cm and a suitable neck for EVAR (Figure 1) with chronic occlusion in the left CIA and diffuse-severe stenosis in the left EIA, the contrasting of the femoral artery and distal arterial structures were normal (Figure 2). Due to the patient's current comorbidities, open abdominal surgery was considered to be a high risk, and it was found to be appropriate to perform AAA repair with completely endovascular methods.

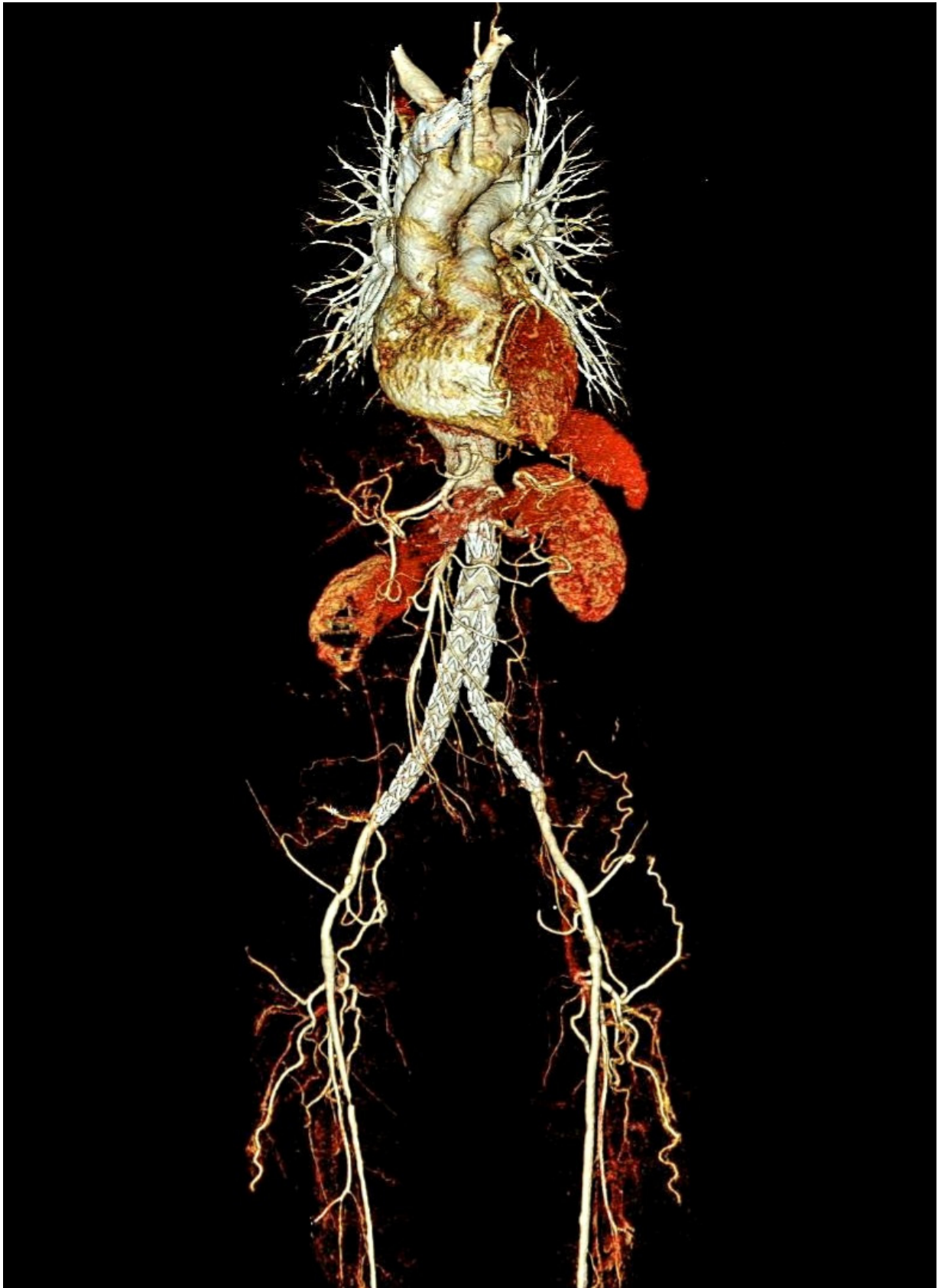
The patient, who EVAR was planned to be performed in combination with left iliac artery revascularization in the same session, was processed in the angiography unit, and after exploring the right



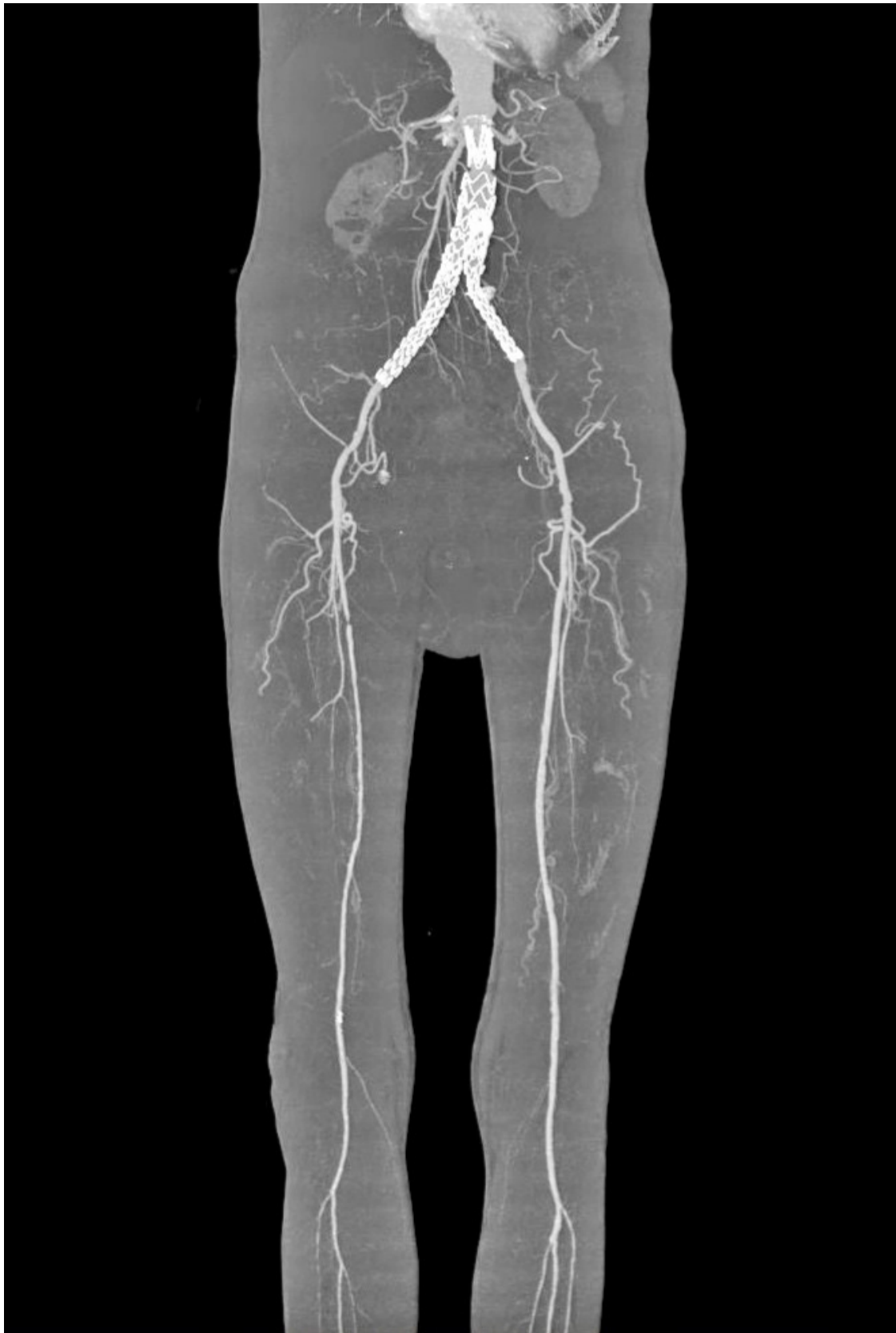**Figure 1.** Preoperative computed tomography arteriography (CTA) scan showing 65mm diametered infrarenal AAA



**Figure 2.** Preoperative reconstructed 3-dimensional computed tomography arteriography (CTA) scan showing an infrarenal abdominal aortic aneurysm (AAA) with concomitant occlusive disease from the left common iliac artery to the left external iliac artery.



**Figure 3-4.** Postoperative reconstructed 3-dimensional computed tomography arteriography (CTA) scans obtained 3 months after repair shows that the left iliac artery is patent.



**Figure 3-4.** Postoperative reconstructed 3-dimensional computed tomography arteriography (CTA) scans obtained 3 months after repair shows that the left iliac artery is patent.

femoral artery for common femoral artery access under local anesthesia, a 7 French (7 Fr) sheath was placed in the right femoral artery for imaging, and an infrarenal AAA with left CIA and EIA occlusion was observed on arteriography that was performed with the aid of a pigtail catheter. Following intravenous heparinization (5000 IU heparine sulphate), a 9 Fr sheath (suitable for both placement of the stent graft system and percutaneous transluminal angioplasty) was placed in the left femoral artery with percutaneous technique under LA and using 0.035 angled hydrophilic guidewire and support catheter (Navicross, Terumo) the left occlusive iliac artery segment was passed with a retrograde recanalization method, and the left occlusive iliac artery segment was successfully dilated with a 9 mm × 150 mm balloon angioplasty catheter (occlusion balloon catheter was available on the table due to the possibility of rupture development). Then, in order to place the stent graft (AFX, Endologix) in accordance with the standard application procedure, 7Fr sheath was replaced with a 17 Fr sheath in the right CFA, and the main system stent graft advanced from here and the contralateral leg system advanced from the sheath in the left CFA were placed at the bifurcation level to cover the lesion in the left iliac artery. Then the main body extension was placed distal to the renal arteries. Post-dilatation was performed on the legs of the stent graft with a balloon angioplasty catheter. After the successful EVAR procedure, control arteriography revealed that the flow was directed into the stent graft, and when no significant stenosis / occlusion nor endo-leak was detected in the stent graft and arterial structures, the procedure was completed and the routine procedures were completed (Figure 3-4).

A standard successful EVAR procedure was applied for the patient, who did not develop any intraoperative complications. The left iliac artery blood flow was also ensured by the dilatation of occluded iliac artery segment dilatation simultaneously. The total treatment time was approximately 35 minutes and the total amount of contrast agent used was approximately 100 ml. During the post-op period, no adverse events were observed in the patient whose femoral artery and pedal pulses were found to be palpable and leg pain decreased. In addition, the patient was discharged with medical treatment on the 2nd postoperative day. The patient's lower extremity pulses were found to be palpable, whose walking distance increased to approximately 1000 meters without claudication at the 3rd month after the procedure. In the control CTA, it was observed that the aneurysm sac was reduced, there was no endo-leak, the stent graft, bilateral iliac arteries and

lower extremity arteries were patent (Figure 3-4). Verbal and written consent were obtained from the patient.

## Discussion

Having lower morbidity and mortality rates compared to the conventional open surgical repair, EVAR has become the first treatment option in the treatment of infrarenal AAA patients with appropriate anatomy<sup>4,10</sup>. However, inappropriately short and angled aneurysm neck, narrow terminal aorta, and very curved and very small diameter or highly calcified iliac arteries are known to be the main technical limitations of standard EVAR procedure<sup>3,5</sup>. Although less seen, unilateral iliac artery occlusion is one of these limitations accompanying AAA<sup>1,4,5,7</sup>. In this patient group, femorofemoral bypass operation combined with AUI, reported to have similar success rates with the open surgical repair of the aneurysm or treatment with bifurcation stents in selected patients, is the most common treatment method<sup>1,3,4,8,11</sup>. In addition to this, bifurcation stent grafts have been reported to have some clear advantages, such as better hemodynamic results and better patency rates compared to AUI stent grafts<sup>1,7,11</sup>. The treatment strategy in AAA can be affected by the presence of iliofemoral occlusive disease and its severity<sup>1,3</sup>. In patients with iliofemoral stenosis, EVAR can be applied after pre-dilatation of the stenotic segment with balloon angioplasty catheter<sup>1,12,13</sup> while in the presence of iliac artery occlusion, AUI and femorofemoral bypass procedure, which is a current treatment option especially in high-risk patients<sup>1,8,14</sup> is reported to have some disadvantages such as prolonging operation time, increasing the risk of graft and skin infection, occlusion and vascular decompensation<sup>3,9</sup>. Percutaneous transluminal balloon dilatation before standard EVAR is not a routine method in patients with unilateral iliac artery occlusion and to our knowledge, there are not many articles in the literature regarding this technique<sup>1,7</sup>. In the case series of 3 patients with iliac artery occlusive disease combined with AAA published in 2017 by Franz RW et al., they reported that the patients were successfully treated with simultaneously percutaneous transluminal angioplasty and EVAR. In the same article, they reported that the risk of open surgery is high due to significant comorbidities in this patient group, therefore, endovascular techniques may be beneficial in this patient group, if possible<sup>11</sup>. In our case, the patient whose AAA is accompanied by unilateral iliac artery occlusion, was treated through

a successful standard EVAR simultaneously applied after percutaneous transluminal balloon dilatation to the occluded iliac artery of the patient.

It has been reported in some articles in the literature that the standard bifurcation stent graft leg may need to be extended up to EIA in the treatment of AAA accompanied by CIA aneurysm, and in cases when the stent graft leg is extended to EIA, the risk of leg occlusion (LO), which is a serious complication of EVAR and which may result in leg loss, increases<sup>15-17</sup>. In other publications in the literature, although it has been reported that the use of an iliac stent with EVAR significantly reduces the risk of LO, there is no consensus regarding the properties and configurations of the effective stent<sup>15,18,19</sup>. In our case with AAA accompanied by unilateral iliac artery occlusive disease, percutaneous transluminal balloon dilatation was applied to the occluded iliac artery. The leg of the graft stent was placed to cover the occluded segment (no additional stent was placed), and a successful standard EVAR procedure was performed simultaneously.

In conclusion, when there are such limitations related to the iliac artery as iliac artery occlusion, the standard EVAR procedure combined with invasive techniques for iliac artery revascularization is a practical and safe treatment option which reduces the procedural morbidity and mortality compared to the other treatment options.

### Funding

None declared.

### Conflict of interest

None declared.

### References

1. Fujimura N, Harada H, Yashiro H, Akiyoshi T, Nakagawa M, Kanai T, et al. Endovascular Repair of Abdominal Aortic Aneurysm using Bifurcated Stent-graft in a Patient with Complete Occlusion from the Common to the External Iliac Artery. *Ann Vasc Surg* 2014; 28(3): 740.e1-740.e5.
2. Prinssen M, Verhoeven ELG, Buth J, Cuypers PWM, van Sambeek MRHM, Balm R, et al. A Randomized Trial Comparing Conventional and Endovascular Repair of Abdominal Aortic Aneurysms. *N Eng J Med* 2004; 351(16): 1607-18.
3. Elkassaby M, Alawy M, Ali MZ, Tawfick WA, Sultan S. Aorto-Uni-Iliac Stent Grafts with and without Crossover Femorofemoral Bypass for Treatment of Abdominal Aortic Aneurysms: A Parallel Observational Comparative Study. *Int J Vasc Med* 2015; 2015: e962078.
4. Varu VN, Lee GK, Chang S, Lee JT. Reentry Device Aided Endovascular Aneurysm Repair in Patients with Abdominal Aortic Aneurysm and Unilateral Iliac Artery Occlusion. *Ann Vasc Surg* 2014; 28(7): 1800.e1-1800.e7.
5. Arko FR, Filis KA, Seidel SA, Gonzalez J, Lingle SJ, Webb R, et al. How Many Patients with Infrarenal Aneurysms are Candidates for Endovascular Repair? The Northern California Experience. *J Endovasc Ther* 2004; 11(1): 33-40.
6. Katsikas VC, Dalainas I, Martinakis VG, Xiromeritis K. The role of aortouniliac devices in the treatment of aneurysmal disease. *Eur Rev Med Pharmacol Sci* 2012; 16(8): 1061-71.
7. Vallabhaneni R, Sorial EE, Jordan WD, Minion DJ, Farber MA. Iliac artery recanalization of chronic occlusions to facilitate endovascular aneurysm repair. *J Vasc Surg* 2012; 56(6): 1549-54.
8. Yilmaz LPK, Abraham CZ, Reilly LM, Gordon RL, Schneider DB, Messina LM, et al. Is cross-femoral bypass grafting a disadvantage of aortomoniliac endovascular aortic aneurysm repair?. *J Vasc Surg* 2003; 38(4): 753-7.
9. Mingoli A, Sapienza P, Feldhaus RJ, Marzo L di, Burchi C, Cavallaro A. Femorofemoral bypass grafts: Factors influencing long-term patency rate and outcome. *Surgery* 2001; 129(4): 451-8.
10. Lederle FA, Freischlag JA, Kyriakides TC, Matsumura JS, Padberg FT, Kohler TR, et al. Long-Term Comparison of Endovascular and Open Repair of Abdominal Aortic Aneurysm. *N Eng J Med* 2012; 367(21): 1988-97.
11. Franz RW, Ibrahim MT, Tanga CF, Epstein DA. Endovascular Treatment of Abdominal Aortic Aneurysm with Complete Iliac Occlusion: Case Series and Literature Review. *Int J Angiol* 2017; 26(04): 259-63.
12. Henretta JP, Karch LA, Hodgson KJ, Mattos MA, Ramsey DE, McLafferty R, et al. Special iliac artery considerations during aneurysm endografting. *Am J Surg* 1999; 178(3): 212-8.
13. Wu T, Carson JG, Skelly CL. Use of Internal Endoconduits as an Adjunct to Endovascular Aneurysm Repair in the Setting of Challenging Aortoiliac Anatomy. *Ann Vasc Surg* 2010; 24(1): 114.e7-114.e11.
14. Jean-Baptiste E, Batt M, Azzaoui R, Koussa M, Hassen-Khodja R, Haulon S. A Comparison of the Mid-term Results Following the use of Bifurcated and Aorto-uniliac Devices in the Treatment of Abdominal Aortic Aneurysms. *Eur J Vasc Endovasc Surg* 2009; 38(3): 298-304.
15. Lee JH, Park KH. Self expandable stent application to prevent limb occlusion in external iliac artery during endovascular aneurysm repair. *Ann Surg Treat Res* 2016; 91(3): 139-44.

16. Conway AM, Modarai B, Taylor PR, Carrell TWG, Waltham M, Salter R, et al. Stent-Graft Limb Deployment in the External Iliac Artery Increases the Risk of Limb Occlusion Following Endovascular AAA Repair. *J Endovasc Ther* 2012; 19(1): 79–85.
17. Hobo R, Buth J. Secondary interventions following endovascular abdominal aortic aneurysm repair using current endografts. A EUROSTAR report. *J Vasc Surg* 2006; 43(5): 896-902.
18. Oshin OA, Fisher RK, Williams LA, Brennan JA, Gilling-Smith GL, Vallabhaneni SR, et al. Adjunctive Iliac Stents Reduce the Risk of Stent-Graft Limb Occlusion following Endovascular Aneurysm Repair with the Zenith Stent-Graft. *J Endovasc Ther* 2010; 17(1): 108–14.
19. Sivamurthy N, Schneider DB, Reilly LM, Rapp JH, Skovobogatyy H, Chuter TAM. Adjunctive primary stenting of Zenith endograft limbs during endovascular abdominal aortic aneurysm repair: Implications for limb patency. *J Vasc Surg* 2006; 43(4): 662–70.