

Missing Teeth as an Early Predictive “Sign” for Atherosclerosis: A Retrospective Study

Junaid Ahmed⁽¹⁾, T. Nithin⁽³⁾, Nanditha Sujir⁽³⁾, Nandita Shenoy⁽⁴⁾

Original Article

Abstract

BACKGROUND: Various mechanisms suggest that periodontal pathogens and inflammatory processes contribute to systemic pathogenic processes such as atherosclerosis. This study investigated the possibility of a correlation between the presence of incidentally found calcifications along the course of the internal carotid artery (ICA) and tooth loss and periodontal status.

METHODS: A retrospective CBCT analysis was performed on 110 patients. CBCT scans obtained as a part of the dental examinations were analyzed for missing teeth and evidence of any calcification along the ICA course. The mean age, gender, and the total number of missing teeth for all scans revealing calcifications were evaluated.

RESULTS: The study sample consisted of 110 scans, with the cohort's mean age (SD) of 50.01 (± 11.6) and gender distribution of 53.4% females and 43.6% males. A total of 17% of the scans exhibited the presence of calcification. A comparison of missing teeth between the two groups revealed that the group with calcification exhibited more missing teeth, which was statistically significant with a p-value of 0.01. Comparison of the apical lesions between the two groups revealed that apical lesion was higher in the group with calcification and was statistically significant with a p-value of 0.011.

CONCLUSIONS: The greater the number of missing teeth, the higher the chances of calcifications being detected along the course of the ICA.

Keywords: Cone-Beam CT, Tomography, CBCT, Carotid Atherosclerosis, Internal Carotid, Periapical Diseases, Periodontitis

Date of submission: 2021-Apr-05, Date of acceptance: 2022-May-17

Introduction

After remaining fairly constant for most of human history, life expectancy has nearly doubled in the last 100 years.¹ As people live longer, the leading cause of death in the world has shifted from infections to chronic diseases, with atherosclerosis being among the most prevalent.² Atherosclerosis is a progressive disease process that is relatively asymptomatic until a dangerous condition such as a stroke occurs; consequently, early detection is critical to cease further progression.²⁻⁵

Mural calcifications of major arteries that serve as atherosclerosis markers can be detected using appropriate imaging techniques.^{6,7}

How to cite this article: Ahmed J, Nithin T, Sujir N, Shenoy N. **Missing Teeth as an Early Predictive “Sign” for Atherosclerosis: A Retrospective Study.** RYA Atheroscler 2022; 18: 1-10.

1- Associate Dean & Professor, Department of Oral Medicine and Radiology Manipal College of Dental Sciences Mangalore Manipal Academy of Higher Education Karnataka, India, 575001

2- Senior Lecturer, Department of Oral Medicine and Radiology Srinivas Institute of Dental Sciences Mukka, India

3- Associate Professor, Department of Oral Medicine and Radiology Manipal College of Dental Sciences, Mangalore Manipal Academy of Higher Education Manipal, Karnataka, India, 576104

4- Associate Professor Department of Oral Medicine and Radiology Manipal College of Dental Sciences Mangalore Manipal Academy of Higher Education India, 575001

Address for correspondence: Nanditha Sujir; Department of Oral Medicine and Radiology, Manipal College of Dental Sciences Mangalore, Manipal Academy of Higher Education, India, 575001. Tel: +91 9480401324. Email: nanditha.sujir@manipal.edu

Calcified carotid plaques, which can be visualized through head and neck images, were found to be an independent predictor of ischaemic cerebrovascular and cardiac events.⁸ Computed Tomography (CT) scans do not significantly differ from Cone Beam Computed Tomography (CBCT) scans for visualizing atherosclerosis of the carotids, although the overall subjective image quality of the former is considered to be higher.^{9,10}

Dental literature has extensively studied the ability of widely used dental radiographs, i.e., Panoramic and Cephalometric imaging, to depict calcified carotid artery atherosclerosis, which is most often incidental. Calcifications of plaque in the carotid artery, also known as calcified carotid atherosclerotic plaque (CCAP), can be easily identified in a CBCT scan.¹¹ Moreover, CBCT can indicate the presence of these calcifications in both the extra- and intracranial course of the internal carotid artery (ICA). The presence of calcifications and its association with age, gender, and various confounding factors could serve as a vital marker in predicting any future risk in asymptomatic dental patients.¹² Screening of CBCT images increases the probability of early detection of CCAP and can help the patient prevent possible future life-threatening events.

Chronic oral infections are implicated in the pathogenesis of atherosclerosis. Symbiotic oral microflora and pathogenic microbes from periodontal and periapical infections like *Porphyromonas gingivalis*, *Campylobacter rectus*, *Porphyromonas endodontalis*, *Prevotella intermedia*, *Prevotella nigrescens*, and *Streptococcus mutans* have been identified in atherosclerotic plaques.¹³ Periodontal disease leads to soft tissue attachment loss and resorption of alveolar bone, eventually leading to teeth loss. Periodontitis affects 14% of adults aged 45 to 54 and 23% of adults aged 65 to 74 and is one of the leading causes of edentulism in 30% of adults.¹⁴ Current literature reveals a significant association between alveolar bone loss and carotid calcification, suggesting that periodontitis-associated inflammation resulting in teeth loss might play a potentially important role in the progression of cardiac disease.¹⁵⁻¹⁷

Few studies support systemic inflammation as both the cause and predictor of the progression of endothelial dysfunction.^{18,19} Studies have demonstrated that periodontitis is a chronic multifactorial infectious disease that can affect the tooth's supporting structures (root, periodontal ligament, and alveolar bone) and is a leading cause of tooth loss.²⁰ Loss of occlusal support due to missing teeth has also been shown to increase the risk of atherosclerosis in these individuals due to poor nutritional intake.²¹

Teeth loss, periapical lesions, and manifestations of periodontal disease are generally related to previous inflammatory events,²² and a linear relationship exists between teeth loss and degree of arterial stiffness.²³ Consequently, it is reasonable to investigate the possibility of a relationship between the presence of incidentally found calcifications along the ICA course and tooth loss and periodontal status.

Materials and Methods

A retrospective study was conducted in the Department of Oral Medicine and Radiology. Ethical approval for the study was obtained from the Institutional ethical committee (protocol ref. no 18080). A total of 110 patients were included in the study. From September 2017 to September 2019, full FOV CBCT scans with dimensions of 20x17cm of patients aged 30 to 70 were extracted from Oral Medicine and Radiology archives and evaluated. A full FOV scan enabled the visualization of the craniofacial region superiorly from an area approximating the frontal sinus to inferiorly coinciding with C3 and C4 vertebra regions. The scans were captured using a Planmeca Pro-max 3D mid-CBCT machine with parameters of 90kV and 8mA and a slice thickness of 0.4 mm. Romexis software (v. 4.6.2) was used to analyze the scans.

CBCT scans obtained as part of a dental exam were retrieved from the archives and analyzed for soft tissue calcification along the course of the ICA, utilizing a method previously described in the literature.²⁴ In addition, the status of missing teeth and periapical lesions associated with teeth present were also noted.

The inclusion criteria were as follows:

- Patients between the age of 30 – 70 years
- CBCT scans with Full/Large Field-Of-View (FOV)
- Scans without any artifacts

Medium and small FOV scans, patients with no missing teeth or missing teeth due to causes other than periodontitis, patients below 30 years of age, patients with significant medical history (diabetes, hypertension), and scans with inadequate resolution and artifacts were excluded from the study. The images were evaluated by a maxillofacial radiologist. The observer was blinded to the patient's medical and dental records.

In the full FOV CBCT scans, the radiologist noted the presence of any calcifications along the ICA anteromedial to the Sternocleidomastoid muscle and Postero-lateral to the oropharynx, approximately at the level of C3 and C4 vertebral region. Axially, the calcifications are most commonly located in the cervical soft tissue, approximately 0–10mm anterolateral to the anterior tubercle of the transverse

process, lateral or more often posterior-lateral to the greater cornu of the hyoid bone,²⁵ and present as single or multiple “rice grains” with a homogeneous opacity and a linear or curvilinear shape.

The images were standardized and evaluated in all three planes (axial, coronal, and sagittal) for each patient and were scrolled from one end to the other in each of the three planes (window-windowing). Radiopacities seen within the cervical part of the internal carotid artery, from the area of bifurcation until its entrance into the carotid canal, were considered to be extracranial calcifications of the ICA (Figure 1). A similar radio-opacity depicted along the artery's intracranial course –from the ascending part of the petrous part up to the cavernous part was considered as intracranial calcification (Figure 2).

The number of missing teeth (MT) was considered as a parameter strongly related to the presence of atherosclerosis in order to quantify the dental status.²⁶

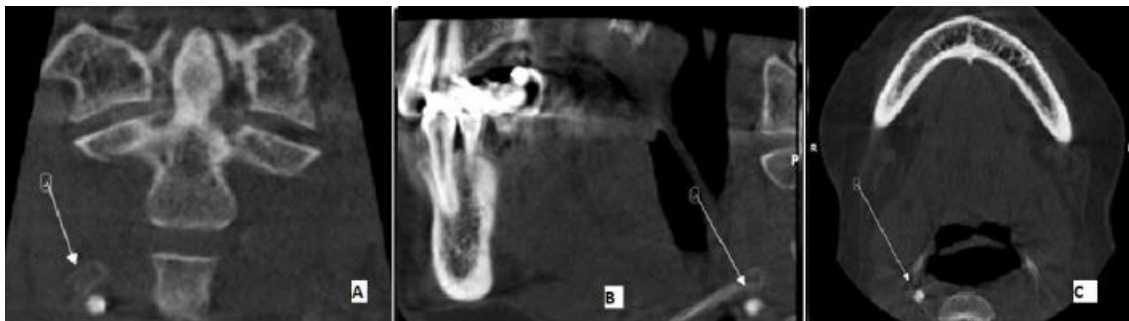

Figure 1. CBCT sections A. Coronal, B. Sagittal C. Axial CBCT sections showing calcification at the region of bifurcation of carotid artery

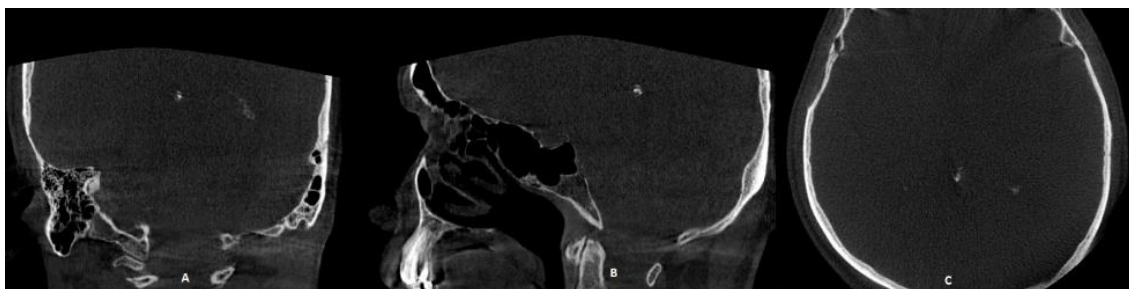


Figure 2. CBCT sections A. Coronal, B. Sagittal C. Axial CBCT sections showing intracranial calcification of Internal carotid artery

Missing teeth due to causes other than periodontitis were excluded based on the patient's dental records. We also documented several teeth with an apical lesion (TAL), endodontically treated teeth with an apical lesion (ETTAL), and endodontically treated teeth without any periapical changes (ETT). After two weeks, the maxillofacial radiologist performed a second evaluation of 20 CBCT scans to determine the interobserver reliability. The intraobserver reliability assessed through the kappa statistics was 0.90.

Statistical Analysis: Collected data were analyzed using the Statistical Package for the Social Sciences (SPSS) software 20.0 for Windows (SPSS, IBM Corp., Chicago, USA). Demographic details of age, gender, and prevalence of ICC calcifications were reported using descriptive statistics. An independent t-test was used to determine the difference in the number of missing teeth and the calcification seen along the ICA between males and females and different age groups. Pearson's correlation test was utilized to correlate age and various parameters. One-way analysis of variance (ANOVA), followed

by a post-hoc Tukey test, was employed to note the difference in the various parameters among different age groups. A p-value of < 0.05 was considered statistically significant.

Results

A total of 110 scans were analyzed, consisting of 48 males (43.6%) and 62 females (56.4%). The intracranial or extracranial course of the ICA was calcified in 19 scans (17.3%). Out of the 48 male patients, 9 (18.75%) showed evidence of calcification. Of 62 females, 10 (16.1%) indicated calcification along the ICA course.

Comparison of age, presence of missing teeth, apical lesions, ETT, and ETTAL between patients with and without calcifications revealed a statistically significant difference concerning missing teeth, apical lesions, and ETT with p-values of 0.001, 0.011, and 0.001, respectively. The group with calcifications revealed higher values for mean age and apical lesions, whereas the group without calcifications showed higher values among ETT (Table 1).

Table 1. Difference between various parameters and the presence of calcification

	Absent (N=91)	Present (N=19)	P-value
Age	49.1±10.612	54.42±14.938	0.154
MT	3.76±2.267	10.05±7.083	0.001*
TAL	1.45±1.128	2.21±1.357	0.011*
ETTAL	0.8±0.872	0.63±0.684	0.424
ETT	2.43±0.944	1.32±1.108	<0.001*

Abbreviations: MT: Missing teeth, TAL: Teeth with periapical lesions, ETT: Endodontically Treated Tooth, ETTAL: Endodontically Treated Tooth with Apical Lesion.

*Statistically significant value.

Statistical Test: Independent t-test.

Table 2. Correlation between age and various parameters in groups with and without Internal carotid artery calcifications

Calcification Status		Correlation (r)	P-value
Absent (n=91)	MT	0.433	<0.001*
	TAL	0.286	0.006
	ETTAL*	0.258	0.014
	ETT*	0.304	0.003
Present (n=19)	MT	0.787	<0.001*
	TAL	0.184	0.45
	ETTAL*	-0.468	0.043
	ETT*	-0.358	0.133

Abbreviations: MT: Missing teeth TAL: Teeth with periapical lesions, ETT: Endodontically Treated Tooth, ETTAL: Endodontically Treated Tooth with Apical Lesion

Statistical Test: Pearson's correlation test

*Statistically significant value

The correlation between mean age and other parameters within the groups with and without calcification revealed a significant

correlation between mean age and missing teeth in both groups with a p-value of <0.001 (Table 2).

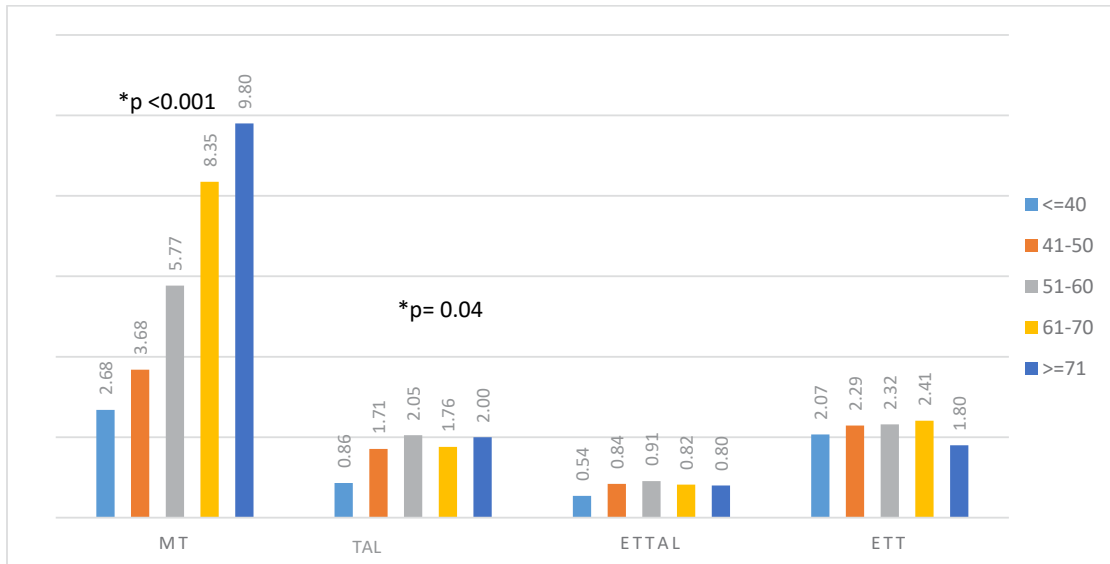


Figure 3. Distribution of various parameters according to age groups

Statistical test: One-way ANOVA

*Statistically significant results

Abbreviations: MT: Missing teeth, TAL: Teeth with periapical lesions, ETT: Endodontically Treated Tooth, ETTAL: Endodontically Treated Tooth with Apical Lesion

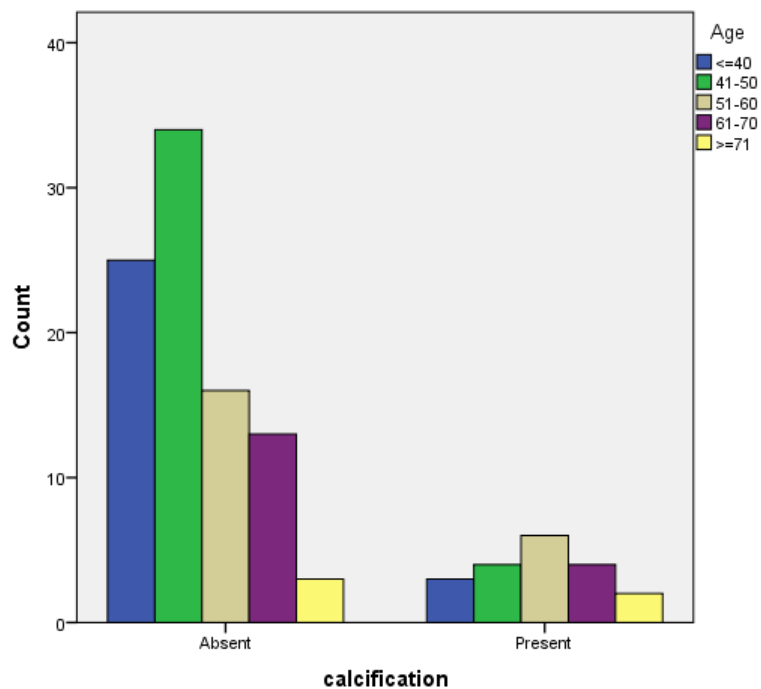


Figure 4. Bar Chart showing the age-wise distribution of internal carotid artery calcification

Statistical Test: Chi-square Test

There was no significant difference observed between the parameters

Figure 3 shows the distribution of various parameters across the age groups, i.e., ≤ 40 years, 41-50 years, 51-60 years, 61-70 years, and ≥ 71 years. Among the previously mentioned age groups, calcification was present in 10.7%, 10.5%, 27.3%, 23.5%, and 40.0%, respectively (Figure 4). There was no statistically significant difference (p-value 0.209) within the age groups concerning the presence of ICC.

Discussion

The present study investigated the association of MT and periapical inflammatory pathologies with calcifications along the course of ICA in full FOV CBCT scans. Several studies have suggested that the development of coronary heart disease (CHD) is related to various types of oral infections.²⁷⁻³⁰ Periodontitis is a chronic multifactorial infectious disease that affects supporting structures of the teeth, including the root, periodontal ligament, and alveolar bone, and is considered one of the major causes of teeth loss. Studies have demonstrated that positive findings of MT can be considered as a sign of previous inflammatory conditions, whereas any calcification along the course of the ICA can be considered as “signs” of atherosclerosis.³¹

We found a significant positive correlation between MT and the presence of calcifications within the course of the ICA. This agreed with the results of other studies providing strong evidence of the relationship between MT and atherosclerosis presence. In a study, Weiner et al.³² reported a strong association between the number of MT and the severity of atherosclerosis in elderly patients and a strong association between the number of missing teeth and cardiovascular diseases. Joshipura et al.³³ evidenced an increased risk of stroke in patients with a substantial number of missing teeth. The study concluded that periodontal disease and the presence of fewer teeth might be associated with an increased risk of ischemic stroke. Most studies examining the association between missing teeth and cardiovascular diseases have treated teeth loss as a nominal variable and primarily focused on the presence

or absence of cardiovascular disease.³⁴ In our study, we treated teeth loss as numeric variables.

Our results revealed that the presence of calcification in the course of ICA directly correlates with teeth loss, which is often a result of the breakdown of periodontal tissue caused by periodontal diseases. Considering teeth loss as a marker of current and long-term cumulative effects of periodontal disease,³⁵ our findings suggest that periodontal disease may play an important role in atherosclerosis progression. Our results corroborate the results of Liljestrand et al.²⁵ and Oluwagbemigun et al.³⁶, who stated that the number of MT might indicate an increased risk for cardiovascular disease, and it could be added to existing cardiovascular risk profiles as an additional risk factor.³⁶ Literature has shown multiple links between MT and atherosclerosis. The incidence of missing teeth is a strong indicator of the presence of oral chronic inflammation/infection, which has been implicated in the pathogenesis of atherosclerosis. MT can also result in compromised occlusion, causing significantly reduced nutritional intake.²¹

In the present study, we observed that the number of missing teeth increased with progressing age and was significant in the group with calcification. The group without calcification also showed an increase in MT with progressive age and was statistically significant. This agreed with the results of a study by Desvarieux et al.³¹, who reported an increase in teeth loss with progressive age in both males and females. The study concluded that the increase in the number of missing teeth with age could be predominantly attributed to periodontal disease, owing to its inflammatory background.

Our study found a significant association between teeth with TAL and ETT with the presence of ICA calcifications. The number of teeth with periapical lesions was significantly higher in the calcifications group. The long-term cumulative inflammatory effect was associated with atherosclerosis, in line with Liljestrand et al.²⁶, who found similar results in their study. Beck et al., who reported that periodontal pocket depth and alveolar bone

loss were significantly associated with coronary heart disease and stroke among US veterans, observed similar results.³⁷ Notably, the imaging modality used in our study, CBCT, can depict all the parameters examined in our study with an extremely high degree of accuracy.³⁸

In our study, we found that as age increases, the chances of finding calcification along the course of ICA increase in both males and females. The average age of patients with calcification was 54.42 versus 49.1 for those without calcification. This was consistent with the findings of Alisson *et al.*³⁹, who found similar results and concluded that the prevalence of calcium deposits in the arterial walls increases significantly with age in both genders and peaks in the seventh and eighth decade of life. In addition, older adults are more likely to develop periodontal disease and subsequent tooth loss and have a higher arterial stiffness.³⁹

In our study, ETT was significantly lower in a group with ICA calcifications, whereas ETTAL was higher, but the difference was not statistically significant. These findings are similar to the results of a study conducted by Petersen *et al.*,⁴⁰ who found that neither ETT nor ETTAL were important factors for the atherosclerotic burden. In our study, men had a higher prevalence of calcification (18.75%) than women (16.1%), although the difference was not statistically significant. The number of missing teeth in females was more in comparison to males. This was in line with Demmer *et al.*⁴¹, who reported an increased number of missing teeth in women. The study concluded that the gender difference found in the predisposition of MT could be attributed to several reasons, such as treatment bias, dental practice differences, sociocultural determinants, and increasing age.⁴¹

The presence of calcifications along the course of ICA is an indicator of an increased risk of stroke and myocardial infarction.⁴² Poor oral hygiene, dental status, and teeth loss are associated with a varying degree of carotid stenosis and can be a potential predictor for any future disease progression.⁴³ These findings could help identify patients at risk

of atherosclerosis by using MT as a surrogate marker. The large FOV is ideal for screening for calcification of ICA as the image includes the cervical vertebral region of C3-C4 (region of bifurcation of common carotid artery) to the upper third of the frontal bone. However, due to the significant radiation exposure, CBCT is not recommended for routine screening of ICA calcifications.

The findings of our study reinforce the suggestion that the progression of atherosclerosis is linearly associated with increased teeth loss.⁴⁴ Future prospective clinical follow-up of patients at risk for cerebrovascular disease and their correlation with the patient's dental status and presence of calcifications may provide additional evidence of the utility of MT and the number of teeth with periapical inflammatory pathology as an early predictive "sign" of atherosclerosis.

Conclusion

Our analysis, using CBCT data sets, revealed that the larger the number of MT, the greater the possibility of calcification that can be detected along the course of the internal carotid artery. A significant correlation exists between mean age (MA) and the number of missing teeth (MT) in patients with calcifications present along the ICA course. Hence, the number of MT and the patient's age can be predictive of atherosclerosis "signs." With the advancement of technology, dentists need to have a thorough understanding of the anatomy of the head and neck region and the location of important structures, as this information can aid in the detection of incidental findings in asymptomatic patients undergoing dental procedures. The presence of calcifications and their relationship to tooth loss and other dental parameters can help the clinician warn the patient of impending danger to their overall health.

Abbreviations

MT: Missing teeth

TAL: Teeth with periapical lesions

ETT: Endodontically Treated Tooth

ETTAL: Endodontically Treated Tooth with Apical Lesion

Data Availability

The data used to support the findings of this study are available from the corresponding author upon request.

Conflicts of Interest

The authors have no conflict of interest to report.

Funding Statement

No funding to declare.

Acknowledgments

None.

References

- Wei R, Curtin LR, Arias E, Anderson RN. US decennial life tables for 1999–2001: Methodology of the United States life tables. *National vital statistics reports*. 2008; 57(4): 1984-89.
- Guyer B, Freedman MA, Strobino DM, Sondik EJ. Annual summary of vital statistics: trends in the health of Americans during the 20th century. *Pediatrics*. 2000; 106(6): 1307-17.
- Marcus SE, Drury TF, Brown LJ, Zion GR. Tooth retention and tooth loss in the permanent dentition of adults: United States, 1988–1991. *J Dent Res*. 1996; 75(2_suppl): 684-95.
- Nazliel HE, Hersek N, Ozbek M, Karaagaoglu E. Oral health status in a group of the elderly population residing at home. *Gerodontology*. 2012; 29(2): e761-7.
- Krustrup U, Erik Petersen P. Periodontal conditions in 35–44 and 65–74-year-old adults in Denmark. *Acta Odontologica Scandinavica*. 2006; 64(2): 65-73.
- Hirota S, Imakita M, Kohri K, Ito A, Morii E, Adachi S, Kim HM, Kitamura Y, Yutani CH, Nomura S. Expression of osteopontin messenger RNA by macrophages in atherosclerotic plaques. A possible association with calcification. *The American journal of pathology*. 1993; 143(4): 1003.
- Woodcock Jr RJ, Goldstein JH, Kallmes DF, Cloft HJ, Phillips CD. Angiographic correlation of CT calcification in the carotid siphon. *American journal of neuroradiology*. 1999; 20(3): 495-9.
- Prabhakaran S, Singh R, Zhou X, Ramas R, Sacco RL, Rundek T. Presence of calcified carotid plaque predicts vascular events: the Northern Manhattan Study. *Atherosclerosis*. 2007; 195(1): e197-201.
- Heiland M, Pohlenz P, Blessmann M, Habermann CR, Oesterhelweg L, Begemann PC, Schmidgunst C, Blake FA, Püschel K, Schmelzle R, Schulze D. Cervical soft tissue imaging using a mobile CBCT scanner with a flat panel detector in comparison with corresponding CT and MRI data sets. *Oral Surgery, Oral Medicine, Oral Pathology, Oral Radiology, and Endodontology*. 2007; 104(6): 814-20.
- Hashimoto K, Kawashima S, Kameoka S, Akiyama Y, Honjaya T, Ejima K, Sawada K. Comparison of image validity between cone beam computed tomography for dental use and multidetector row helical computed tomography. *Dentomaxillofacial Radiology*. 2007; 36(8): 465-71.
- Ravon NA, Hollender LG, McDonald V, Persson GR. Signs of carotid calcification from dental panoramic radiographs are in agreement with Doppler sonography results. *Journal of clinical periodontology*. 2003; 30(12): 1084-90.
- Damaskos S, Tsiklakis K, Syriopoulos K, der Stelt PV. Extra-and intra-cranial arterial calcifications in adults depicted as incidental findings on cone beam CT images. *Acta Odontologica Scandinavica*. 2015; 73(3): 202-9.
- Aarabi G, Heydecke G, Seedorf U. Roles of oral infections in the pathomechanism of atherosclerosis. *International Journal of Molecular Sciences*. 2018; 19(7): 1978.
- National Institute of Dental, Craniofacial Research (US). Oral health in America: a report of the Surgeon General. US Public Health Service, Department of Health and Human Services; 2000.
- Persson RE, Hollender LG, Powell VL, MacEntee M, Wyatt CC, Kiyak HA, Persson GR. Assessment of periodontal conditions and systemic disease in older subjects: II. Focus on cardiovascular diseases. *Journal of clinical periodontology*. 2002; 29(9): 803-10.

16. Schenkein HA, Papapanou PN, Genco R, Sanz M. Mechanisms underlying the association between periodontitis and atherosclerotic disease. *Periodontology* 2000. 2020; 83(1): 90-106.
17. Rahimi A, Hadavi MM. Relationship between periodontitis and cardiovascular disease. *ARYA Atherosclerosis Journal*. 2020; 16(6): 306.
18. Higashi Y, Goto C, Hidaka T, Soga J, Nakamura S, Fujii Y, Hata T, Idei N, Fujimura N, Chayama K, Kihara Y. Oral infection-inflammatory pathway, periodontitis, is a risk factor for endothelial dysfunction in patients with coronary artery disease. *Atherosclerosis*. 2009; 206(2): 604-10.
19. Minn YK, Suk SH, Park H, Cheong JS, Yang H, Lee S, Do SY, Kang JS. Tooth loss is associated with brain white matter change and silent infarction among adults without dementia and stroke. *Journal of Korean medical science*. 2013; 28(6): 929-33.
20. Teeuw WJ, Slot DE, Susanto H, Gerdes VE, Abbas F, D'Aiuto F, Kastelein JJ, Loos BG. Treatment of periodontitis improves the atherosclerotic profile: a systematic review and meta-analysis. *Journal of clinical periodontology*. 2014; 41(1): 70-9.
21. Tada S, Ikebe K, Kamide K, Gondo Y, Inomata C, Takeshita H, Matsuda KI, Kitamura M, Murakami S, Kabayama M, Oguro R. Relationship between atherosclerosis and occlusal support of natural teeth with mediating effect of atheroprotective nutrients: From the SONIC study. *PLoS One*. 2017; 12(8): e0182563.
22. Genco R, Offenbacher S, Beck J. Periodontal disease and cardiovascular disease: epidemiology and possible mechanisms. *The Journal of the American Dental Association*. 2002; 133: 14S-22S.
23. Asai K, Yamori M, Yamazaki T, Yamaguchi A, Takahashi K, Sekine A, Kosugi S, Matsuda F, Nakayama T, Bessho K, Nagahama Study Group. Tooth loss and atherosclerosis: the Nagahama Study. *Journal of Dental Research*. 2015; 94(3_ suppl): 52S-8S.
24. da Silveira HL, Damaskos S, Arús NA, Tsiklakis K, Berkhout EW. The presence of calcifications along the course of internal carotid artery in Greek and Brazilian populations: a comparative and retrospective cone beam CT data analysis. *Oral Surgery, Oral Medicine, Oral Pathology and Oral Radiology*. 2016; 121(1): 81-90.
25. Scarfe WC, Farman AG. Soft tissue calcifications in the neck: Maxillofacial CBCT presentation and significance. *AADMRT Currents*. 2010; 2(2): 3-15.
26. Liljestrand JM, Havulinna AS, Paju S, Männistö S, Salomaa V, Pussinen PJ. Missing teeth predict incident cardiovascular events, diabetes, and death. *Journal of dental research*. 2015; 94(8): 1055-62.
27. Mattila KJ, Nieminen MS, Valtonen VV, Rasi VP, Kesäniemi YA, Syrjälä SL, Jungell PS, Isolouma M, Hietaniemi K, Jokinen MJ. Association between dental health and acute myocardial infarction. *British medical journal*. 1989; 298(6676): 779-81.
28. Mattila KJ, Valtonen VV, Nieminen M, Huttunen JK. Dental infection and the risk of new coronary events: prospective study of patients with documented coronary artery disease. *Clinical Infectious Diseases*. 1995; 20(3): 588-92.
29. DeStefano F, Anda RF, Kahn HS, Williamson DF, Russell CM. Dental disease and risk of coronary heart disease and mortality. *British Medical Journal*. 1993; 306(6879): 688-91.
30. Loesche WJ, Schork A, Terpenning MS, Chen YM, Dominguez BL, Grossman N. Assessing the relationship between dental disease and coronary heart disease in elderly US veterans. *The Journal of the American Dental Association*. 1998; 129(3): 301-11.
31. Desvarieux M, Demmer RT, Rundek T, Boden-Albala B, Jacobs Jr DR, Papapanou PN, Sacco RL. Relationship between periodontal disease, tooth loss, and carotid artery plaque: the Oral Infections and Vascular Disease Epidemiology Study (INVEST). *Stroke*. 2003; 34(9): 2120-5.
32. Wiener RC, Sambamoorthi U. Cross-sectional association between the number of missing teeth and cardiovascular disease among adults aged 50 or older: BRFSS 2010. *International journal of vascular medicine*. 2014; 2014.
33. Joshipura KJ, Hung HC, Rimm EB, Willett WC, Ascherio A. Periodontal disease, tooth loss, and incidence of ischemic stroke. *Stroke*. 2003; 34(1): 47-52.
34. Choe H, Kim YH, Park JW, Kim SY, Lee SY, Jee SH. Tooth loss, hypertension and risk for stroke in a Korean population. *Atherosclerosis* 2009; 203: 550-6.
35. Houshmand M, Holtfreter B, Berg MH, Schwahn C, Meisel P, Biffar R, Kindler S, Kocher T. Refining definitions of periodontal disease and caries for prediction models of incident tooth loss. *Journal of clinical periodontology*. 2012; 39(7): 635-44.

36. Oluwagbemigun K, Dietrich T, Pischon N, Bergmann M, Boeing H. Association between number of teeth and chronic systemic diseases: a cohort study followed for 13 years. *PLoS One*. 2015; 10(5): e0123879.
37. Beck JD, Offenbacher S, Williams R, Gibbs P, Garcia R. Periodontitis: a risk factor for coronary heart disease? *Annals of periodontology*. 1998; 3(1): 127-41.
38. Price JB, Thaw KL, Tyndall DA, Ludlow JB, Padilla RJ. Incidental findings from cone beam computed tomography of the maxillofacial region: a descriptive retrospective study. *Clinical oral implants research*. 2012; 23(11): 1261-8.
39. Allison MA, Criqui MH, Wright CM. Patterns and risk factors for systemic calcified atherosclerosis. *Arteriosclerosis, thrombosis, and vascular biology*. 2004; 24(2): 331-6.
40. Petersen J, Glaßl EM, Nasseri P, Crismani A, Luger AK, Schoenherr E, Bertl K, Glodny B. The association of chronic apical periodontitis and endodontic therapy with atherosclerosis. *Clinical oral investigations*. 2014; 18(7): 1813-23.
41. Demmer RT, Kocher T, Schwahn C, Völzke H, Jacobs Jr DR, Desvarieux M. Refining exposure definitions for studies of periodontal disease and systemic disease associations. *Community dentistry and oral epidemiology*. 2008; 36(6): 493-502.
42. Rennenberg RJ, Kessels AG, Schurgers LJ, Van Engelshoven JM, De Leeuw PW, Kroon AA. Vascular calcifications as a marker of increased cardiovascular risk: a meta-analysis. *Vascular health and risk management*. 2009; 5: 185.
43. Bos D, van der Rijk MJ, Geeraedts TE, Hofman A, Krestin GP, Witteman JC, van der Lugt A, Ikram MA, Vernooij MW. Intracranial carotid artery atherosclerosis: prevalence and risk factors in the general population. *Stroke*. 2012; 43(7): 1878-84.
44. Asai K, Yamori M, Yamazaki T, Yamaguchi A, Takahashi K, Sekine A, Kosugi S, Matsuda F, Nakayama T, Bessho K, Nagahama Study Group. Tooth loss and atherosclerosis: the Nagahama Study. *Journal of Dental Research*. 2015; 94(3_suppl): 52S-8S.