

## Diagnostic performance of 64-row coronary CT angiography in detecting significant stenosis as compared with conventional invasive coronary angiography

Amirreza Sajjadi<sup>(1)</sup>, Ali Hekmatnia<sup>(2)</sup>, Maryam Keivani<sup>(3)</sup>,  
Abdollah Asoodeh<sup>(4)</sup>, Masoud Pourmoghaddas<sup>(5)</sup>, Hamid Sanei<sup>(6)</sup>

### Original Article

#### Abstract

**BACKGROUND:** The aim of the present study is to evaluate the accuracy of 64-multidetector-row computed tomography angiography (CTA) in comparison to conventional invasive angiography (CIA) in the diagnosis of significant stenosis ( $\geq 50\%$ ) of coronary artery tree.

**METHODS:** Assessment of CTA in the detection of coronary artery disease (CAD) was performed in patients referred because of symptoms or stress studies suggestive of ischemia. For this purpose, among more than 1000 cases of coronary CTA in a 20 months period a study population of 54 patients suspected to have significant stenosis of the coronary artery tree was investigated. The CIA procedure was performed in these patients one month after CTA. The accuracy of CTA in detecting significant stenosis was compared to CIA.

**RESULTS:** For vessel based analysis of 179 coronary vessels, CTA had a sensitivity of 96%, specificity of 87.5%, positive predictive value of 90.5%, and negative predictive value of 94.6%. For patient-base analysis, the sensitivity, specificity, positive predictive value (PPV), and negative predictive value (NPV) of CTA were 97.9%, 28.6%, 66.6%, and 90.2%, respectively.

**CONCLUSION:** The findings of this study reveal that CT angiography with 64-slice scanner could be considered as a suitable technique for rapid triage of patients presenting to hospitals with chest pain. High values of sensitivity and PPV reveal the good performance of CTA in detecting CAD.

**Keywords:** Coronary Artery Disease (CAD), Computed Tomography Angiography (CTA), Conventional Invasive Angiography (CIA)

*Date of submission:* 11 Sep 2012, *Date of acceptance:* 30 Jan 2013

#### Introduction

Coronary artery disease (CAD) is one of the main causes of disability and death all over the world. For several decades, conventional invasive angiography (CIA) has been considered as the well-established gold standard for making the diagnosis of CAD. Conventional invasive angiography (CIA) is highly reliable compared to other indirect evaluation methods such as stress testing. CIA has a high diagnostic ability to determine the extent, location, and severity of coronary obstructive lesions. Thus, this method remains the main standard for the diagnosis of CADs. However, CIA is not a good choice in some cases due to its invasive nature and

the risk of complications, i.e. arrhythmia, myocardial infarction, stroke, access site problems, etc. Finally, nearly one third of CIAs were reported to be normal, and therefore this invasive procedure is not necessary for all patients.<sup>1</sup> Furthermore, there are constraints on the number of CIA that can be undertaken, in terms of the cardiologist's time.<sup>2</sup> Therefore, an accurate non-invasive alternative evaluation method for diagnosing CAD is highly desirable. Note that noninvasive modalities, like stress echocardiography and myocardial radionuclide scan, are unable to evaluate the coronary artery since these methods evaluate only the corresponding myocardial segment. In order to overcome

1- Interventional Cardiologist, Cardiac Rehabilitation Research Center, Isfahan Cardiovascular Research Institute, Isfahan University of Medical Sciences, Isfahan, Iran

2- Associate Professor, Department of Radiology, Isfahan University of Medical Sciences, Isfahan, Iran

3- Resident, Shahrekord University of Medical Sciences, Shahrekord, Iran

4- Resident, Cardiac Rehabilitation Research Center, Isfahan Cardiovascular Research Institute, Isfahan University of Medical Sciences, Isfahan, Iran

5- Professor, Isfahan Cardiovascular Research Center, Isfahan Cardiovascular Research Institute, Isfahan University of Medical Sciences, Isfahan, Iran

6- Associate Professor, Isfahan Cardiovascular Research Center, Isfahan Cardiovascular Research Institute, Isfahan University of Medical Sciences, Isfahan, Iran

Correspondence to: Ali Hekmatnia, Email: amir135236@yahoo.com

the complications of CIA, multi-slice computed tomography angiography (CTA) has been proposed in recent years as an alternative procedure for determining the presence of coronary obstructions. With the recent development in hardware with multiple detectors, the spatial and temporal resolutions of images have been significantly improved and consequently CTA has become the center of interest for clinicians. The 4-slice, 16-slice, and 64-slice imaging machines have been utilized in 1998, 2001, and 2004, respectively.<sup>2</sup> These machines facilitated the rapid identification and assessment of atherosclerosis within the moving coronary arteries and potentially reduced the necessity for CIA. Abdulla et al. evaluated the diagnostic accuracy of 64-slice CTA compared with the standard reference CAD.<sup>3</sup> Based on their systematic search, 27 studies including 1740 patients were considered for meta-analyses. Their review paper validated CTA as a potential alternative to CIA in patients suspected of having coronary stenosis. Mowatt et al. undertook another comprehensive systematic review and meta-analysis of the clinical effectiveness and cost-effectiveness of 64-slice or higher CTA as an alternative to CIA for detecting CAD. The diagnostic accuracy and prognostic studies enrolled over 2500 and 1700 people, respectively.<sup>4</sup> Other systematic reviews have also been conducted on evaluation of 64-slice CTA in the diagnosis and assessment of coronary artery disease.<sup>2,5,6</sup> Stein et al. performed a systematic review on 64-slice CTA for diagnosis of CAD.<sup>7</sup> They concluded that negative CTA reliably excluded significant CAD. However, the data suggest that stenoses shown on CTA need confirmation. Combining the results of 64-slice CTA with a pretest clinical probability assessment would strengthen the diagnosis.<sup>7</sup> Further useful findings can be found in other works that have examined the accuracy of CTA in comparison with CIA for detecting CADs.<sup>8-20</sup> The current investigation was conducted using a 64-row-detector CT scanner to evaluate the sensitivity, specificity, negative predictive value, and positive predictive value of CTA in identifying significant stenosis ( $\geq 50\%$ ). The accuracy of 64-row CTA is compared with that of the CIA method as the gold standard.

## Materials and Methods

### Patients

The study population was chosen from the 1000 patients who were suspected of having coronary artery disease and who referred to the Heart Center

of Al Zahra Hospital between March 2010 and January 2012.

In this study 54 patients asked to participate. According to the cardiologist all these patients underwent CIA one month after CTA was performed. Exclusion criteria for CTA were based on technical factors that made the patient unsuitable for the procedure. These included known allergic reaction to iodinated contrast agents, high baseline heart rate ( $> 70$  beats/min) with contraindication to beta-blockade, atrial fibrillation, inability to hold the breath for 15-s, inability to lie flat, abnormal renal function (serum creatinine level  $> 1.5$  mg/dL). The detailed characteristics of the study population are listed in table 1. The study was approved by the local ethical review board.

**Table 1.** Patient demographics and clinical indications (n = 54)

	Number	Percentage
Male	34	63
Mean age (years)	59	-
Diabetes mellitus	13	24
Hypertension	22	41
Smoking	15	28
Hyperlipidemia	21	39

### Preparation procedure

The patients' heart rates were assessed 1 hour before scanning. Patients with a prescan heart rate of higher than 60 beats/min received 50–100 mg oral metoprolol 1 hour before CTA. In the case of patients with anxiety, 0.5 mg alprazolam was given. If the heart rate was still higher than 60 beats/min at the time of the examination, intravenous propranolol ( $< 10$  mg) was used to achieve a target prescan heart rate of less than 60 beats/min. Sublingual nitrates were used before the procedure.

### Scanning Protocol

All patients were scanned with a 64-slice single-source CT scanner (Medical health care GE Work Station RDW 4.3, GE, USA). The scanning parameters applied have been reported in table 2. After calcium scanning, a bolus of 80-100 ml nonionic iodinated contrast medium (Ultravist-300) followed by 50–60 ml of normal saline was injected through an antecubital vein by way of an 18-gauge catheter using a dual injector at a flow rate of 4–6 ml/s. A dose of 15 ml contrast material was used during the bolus timing scan calculated (by the apparatus software) at the level of the descending

aorta. Seven seconds were added to the calculated time to carry out the CT procedure. All data sets acquired were reconstructed from the axial, coronal, and sagittal images using a retrospective electrocardiogram gating with the GE Advantage Windows Workstation 4.3. The data set was reconstructed at 75% of R-R intervals. In cases that motion artifacts resulted in low image quality, additional data sets were reconstructed between 25% and 85% of R-R interval to obtain optimal image quality.

**Table 2.** Angiographic Scan Parameters

Number of Slices per rotation	64 × 1
Individual detector width	0.625 mm
Rotation time	0.33 sec
Tube voltage	120 kVp
Tube current	320 mA

### CTA Image Evaluation

The reconstructed images were visually evaluated for estimation of coronary artery narrowing. Axial images, postprocessing volume-rendered 3D images, the maximum intensity projections, multiplanar reconstructions, and linear conformation of the vessels were used to evaluate vessel stenosis. A significant lesion was defined as more than 50% reduction in lumen diameter. The judgment about the absence/presence of CAD was made after viewing the various images and checking stenosis of main coronary vessels, i.e. left main artery, left anterior descending, circumflex artery, first diagonal, second diagonal, obtuse marginal, right coronary artery and the posterior descending artery.

### CIA procedure and analysis

Routine CIA procedure was performed via the femoral or radial artery. All evaluated vessels were classified as normal vessels, having non-significant disease (luminal irregularities resulting in narrowing < 50%), or as having significant stenosis (luminal narrowing ≥ 50%). Accordingly, patients were classified as positive for the presence of significant CAD if there was a significant stenosis in any artery. Comparisons were then made between CTA and

CIA findings.

### Statistical Analysis

The CTA accuracy for detecting vessel stenosis was evaluated by four indicative statistical parameters including sensitivity, specificity, positive predictive value (PPV), and negative predictive value (NPV). These parameters were calculated for vessels and for the patients and presented as percentages [95% confidence interval]. The sensitivity parameter shows that there is positive CTA among patients with positive CIA. The sensitivity is mathematically determined as the sum of true positive divided by the sum of diseased. The specificity parameter implies the negative CTA among patients with negative CIA. The specificity is calculated as the sum of true negative divided by the sum of non diseased.

## Results

### Patient-Based Analysis

The characteristics of the 54 patients were analyzed and the results are presented in table 3. The obtained results reveal that 2 patients were diagnosed as normal by both CIA and CTA (true negative). Only 1 patient was considered as normal based on CTA findings, but this patient was diagnosed as abnormal by CIA. This reveals that 1 case was reported as false negative. Figure 1 depicts the typical example of false negative cases where CTA reveals normal coronary arteries but CIA shows obstructive CAD. Of the remaining 51 subjects diagnosed as abnormal on CTA, 46 were confirmed by CIA (true positive). Figure 2 depicts a typical example of true positive cases where both CTA and CIA reveal CAD. Finally, 5 cases were reported abnormal on CTA while proved to be normal by CIA (false positive).

### Vessel-Based Analysis

The obtained results of the vessel-based analysis have been reported in table 4. For this analysis 179 vessels were evaluated using both CTA and CIA procedures. According to the vessel-based obtained data presented in table 4, 95 true positive, 70 true negative, 10 false positive, and 4 false negative cases were reported in this study when compared to CIA procedure.

**Table 3.** Diagnostic performance of CTA for the detection of > 50% stenosis for patient-based analysis

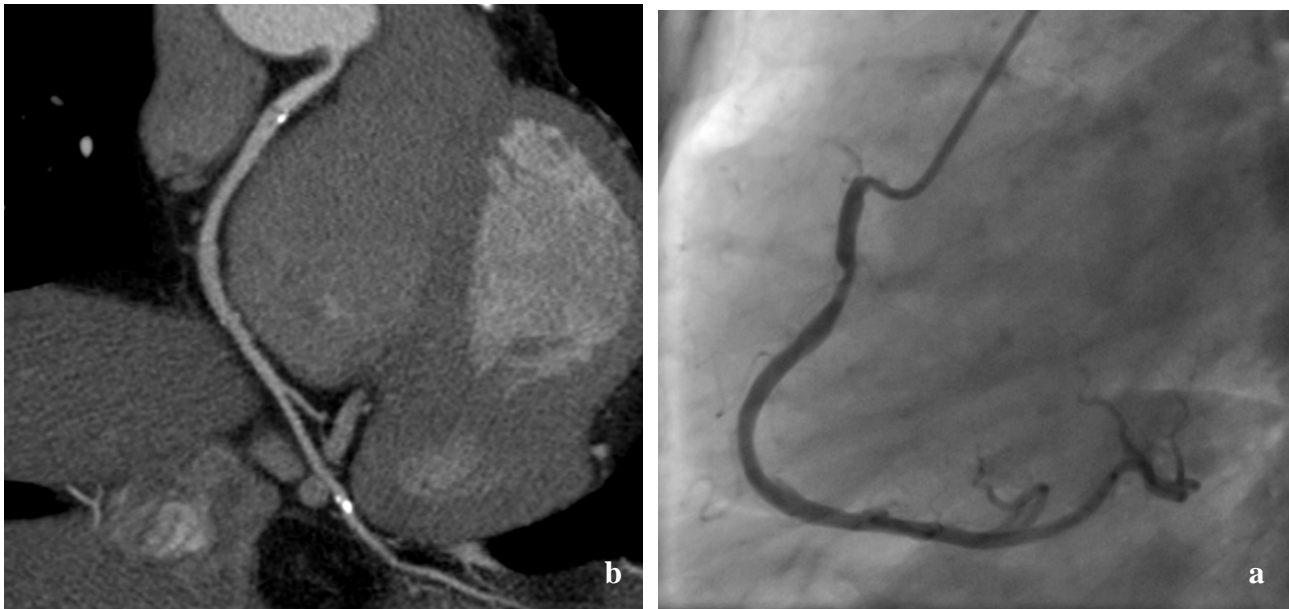Analysis	N	TP	TN	FP	FN	Sensitivity %	Specificity %	PPV %	NPV %
Patient-based	54	46	2	5	1	97.9	28.6	90.2	66.6

TP: True positive; TN: True negative; FP: False positive; FN: False negative; PPV: positive predictive value; NPV: negative predictive value

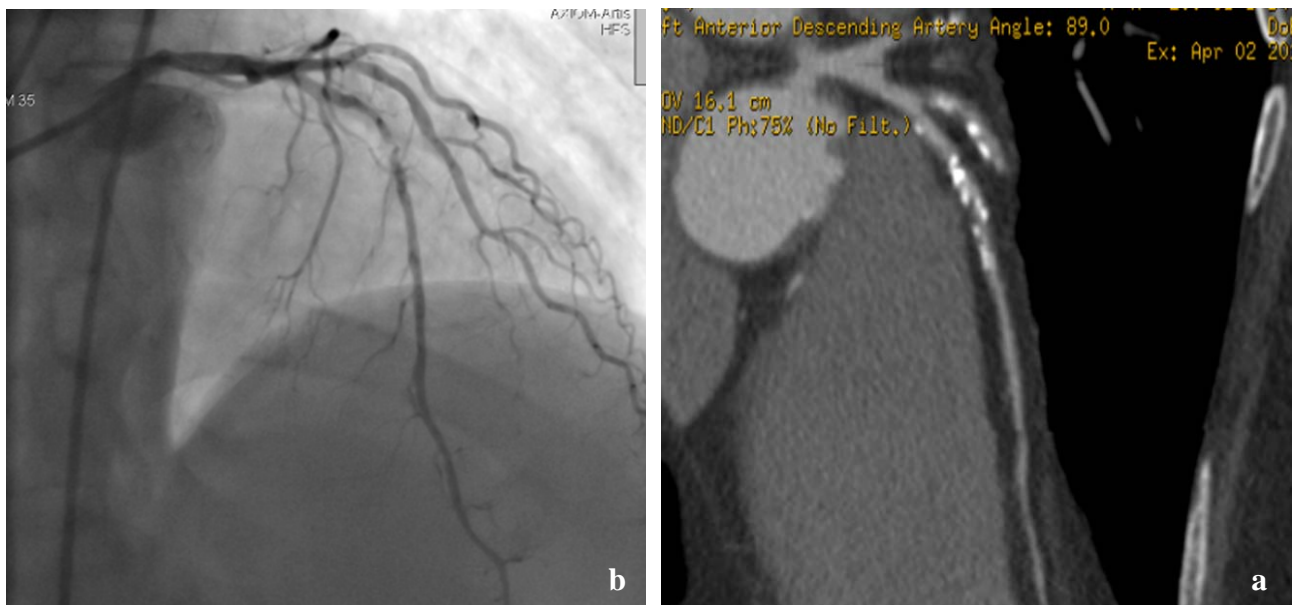
**Table 4.** Diagnostic performance of CTA for the detection of > 50% stenosis for vessel-based analysis

Analysis	N	TP	TN	FP	FN	Sensitivity %	Specificity %	PPV	NPV
Vessel-based	179	95	70	10	4	96	87.5	90.5	94.6

TP: True positive; TN: True negative; FP: False positive; FN: False negative; PPV: positive predictive value; NPV: negative predictive value



**Figure 1.** A typical example of false negative cases where (a) computed tomography angiography (CTA) reveals no significant stenosis while (b) conventional invasive angiography (CIA) shows a significant stenosis at proximal part of right coronary artery



**Figure 2.** A typical example of true positive cases where both computed tomography angiography (CTA) (a) and conventional invasive angiography (CIA) (b) show a significant stenosis

### Discussion

Many progresses have been accomplished to provide time-saving accurate diagnostic protocols for CAD suspected patients. The advent of 64-slice

CT scanners accelerated this evolution. CTA is recommended as useful especially for patients with higher complications of CIA. However, a crucial issue is to understand how close the CTA and CIA

findings are. According to the patient-based data presented in table 3, CTA has a sensitivity of 97.9%, a specificity of 28.6%, a positive predictive value of 90.2%, and a negative predictive value of 66.6% when compared to CIA procedure. Furthermore, a sensitivity of 96%, a specificity of 87.5%, a positive predictive value of 90.5%, and a negative predictive value of 94.6% is reported for vessel-based analysis. Comparison between the obtained results and those presented in other review papers show that both patient-based and vessel-based sensitivity of the present study are very close to the values reported by previous researchers for 64-slice CTA.<sup>5,6</sup> The high sensitivity of CTA reveals the reliability of this method as a conservative approach for ruling out CAD via a negative CTA result. Note that due to the high sensitivity of CTA it is very improbable to miss any positive case via this method. A similar trend is observed for the PPV parameter. Comparing the present study with other investigations reveals that the computed PPV (90.2% for patient-based and 90.5% for vessel-based analysis) is close to those reported in previous literature.<sup>5,6</sup> This reveals the good performance of CTA in detecting CAD, and one can conclude that a positive CTA result indicates a significant CAD. In this study, the low values of patient-based specificity and NPV might be attributed to the conservative selection of the study population. Note that CTA was conducted on patients suspected to have a significant CAD instead of randomly selected patients. This conservative approach results in a selection bias and the consequent reduction of the real negative cases, specificity. However, this difference is not observed in the case of vessel-based analysis in which the computed parameters are close to those reported in previous literature.<sup>5,9,18,19</sup> Interestingly, most (70%) false reports, i.e. false positive and false negative cases, are reported for left anterior descending (LAD) artery. This finding is in accordance with the findings of Sheikh et al., who reported lower sensitivity for LAD vessel in comparison with those of other main vascular tree vessels (RCA and Cx artery).<sup>9</sup> Moreover, CTA can reliably detect patients who need revascularization (interventionally or surgically) based on the involved vessels and segments. This is important from the clinical point of view.<sup>11</sup>

### Technological advancements

It is expected that the new generation of scanning machines with higher number of slice per rotation (rows) and higher temporal resolution can diminish the inaccuracies of the present 64-slice CT scanners.

Previous research on different generation of multi-detector CT machines (4-slice, 16-slice, and 64-slice scanners) revealed that increase in number of slice per rotation results in more accurate results.<sup>21</sup> This trend is expected to be continued for the forthcoming multisection scanners with higher number of detectors. For example, new generated 320-row scanners improved image acquisition as well as reduced radiation dose compared with retrospectively gated 64-row CTA.<sup>15</sup> Moreover, in recent years, several modified techniques, i.e. dose modulation, eliminating helical oversampling, prospectively gated approach with electrocardiogram triggering, and etc., have been developed to decrease CTA radiation dose.<sup>22-24</sup> These technological advances show that the reliability of CTA can reach that of CIA in the future. Furthermore, a systematic heart rate control might significantly improve the diagnostic accuracy of the present single-source CTA. Note that a comparison between single-source and dual-source CTA revealed the significant influence of heart rate control on enhancing the diagnostic accuracy of single-source 192 CTA.<sup>8</sup>

### Limitations

It should be remarked that the present study was preformed based on single-center data, hence the obtained results might not be generalized. The following limitations to the present study should be considered. First, patients were exposed to a higher dose of radiation in CTA procedure in comparison with CIA.<sup>12</sup> Therefore, concerns should be raised about applying conservative radiation dose, and careful patient selection especially in the cases of young people and women of childbearing age.<sup>25</sup> Moreover, note that CTA was conducted on patients suspected to have a significant CAD referred for CIA. This, results in a selection bias in the study. Therefore, the present diagnostic performance may not be directly applicable to patients with a lower prevalence of CAD. Finally, it should be noted that heavy coronary calcification and the consequent beam hardening are the major limitations to reliable evaluation of all coronary arteries.<sup>26-28</sup> In these cases CIA might be more useful than CTA in obtain completely reliable diagnoses. It should be noted that while a calcium score of higher than 600 is known as a limiting parameter for CTA, this was not a dominant limitation in present study. Some technical tricks like higher flow rates of contrast injection, lower heart rates, and reconstruction with sharper kernels and wider window level improved the image quality.<sup>29</sup>

### Future directions

For increasing the diagnostic performance of CTA, one might evaluate the myocardial perfusion. This can be preformed by combining the anatomic data with physiologic significance of the atherosclerotic lesions. Further investigation is required to develop appropriate acquisition protocols for optimal image acquisition and decreased radiation dose. With the developments in CTA technology, future studies should be conducted on reducing radiation exposure, while maintaining high image quality.

### Conclusion

The present study may have applied clinical implications for the detection of stenosis of higher than 50%. Results demonstrated moderately good diagnostic accuracy for the assessment of obstructive CAD using 64-row CTA. For vessel based analysis, CTA had the sensitivity, specificity, positive predictive value, and NPV of 96%, 87.5%, 90.5%, and 94.6%, respectively. For patient-based analysis, these values were 97.9%, 28.6%, 66.6%, and 90.2%, respectively. The high value of sensitivity reveals the good performance of CTA in ruling -out CAD. Similarly, it has been reported that high PPV indicates the reliability of CTA in diagnosing CAD. While the mean specificity and NPV of patient-based analysis is lower than those reported in previous literature, this difference is not observed in vessel-based analysis. The findings reveal that CT angiography with 64-slice scanner could be considered as a suitable technique for rapid triage of patients presenting to hospital with chest pains. It should be noted that further investigation is required to determine whether 64-row scanning technology has sufficient resolution to delineate CAD.

### Acknowledgements

The technical support of the multi-slice CT ward of Alzahra Hospital and the angiography ward of Sina Hospital are acknowledged. Furthermore, the financial support of the Isfahan University of Medical Science is gratefully acknowledged.

### Conflict of Interests

Authors have no conflict of interests.

### References

- Xu Y, Tang L, Zhu X, Xu H, Tang J, Yang Z, et al. Comparison of dual-source CT coronary angiography and conventional coronary angiography for detecting coronary artery disease. *Int J Cardiovasc Imaging* 2010; 26(Suppl 1): 75-81.
- Mowatt G, Cook JA, Hillis GS, Walker S, Fraser C, Jia X, et al. 64-Slice computed tomography angiography in the diagnosis and assessment of coronary artery disease: systematic review and meta-analysis. *Heart* 2008; 94(11): 1386-93.
- Abdulla J, Abildstrom SZ, Gotzsche O, Christensen E, Kober L, Torp-Pedersen C. 64-multislice detector computed tomography coronary angiography as potential alternative to conventional coronary angiography: a systematic review and meta-analysis. *Eur Heart J* 2007; 28(24): 3042-50.
- Mowatt G, Cummins E, Waugh N, Walker S, Cook J, Jia X, et al. Systematic review of the clinical effectiveness and cost-effectiveness of 64-slice or higher computed tomography angiography as an alternative to invasive coronary angiography in the investigation of coronary artery disease. *Health Technol Assess* 2008; 12(17): iii-143.
- Sun Z, Lin C, Davidson R, Dong C, Liao Y. Diagnostic value of 64-slice CT angiography in coronary artery disease: a systematic review. *Eur J Radiol* 2008; 67(1): 78-84.
- Paech DC, Weston AR. A systematic review of the clinical effectiveness of 64-slice or higher computed tomography angiography as an alternative to invasive coronary angiography in the investigation of suspected coronary artery disease. *BMC Cardiovasc Disord* 2011; 11: 32.
- Stein PD, Yaekoub AY, Matta F, Sostman HD. 64-slice CT for diagnosis of coronary artery disease: a systematic review. *Am J Med* 2008; 121(8): 715-25.
- Achenbach S, Ropers U, Kuettner A, Anders K, Pflederer T, Komatsu S, et al. Randomized comparison of 64-slice single- and dual-source computed tomography coronary angiography for the detection of coronary artery disease. *JACC Cardiovasc Imaging* 2008; 1(2): 177-86.
- Sheikh M, Ben-Nakhi A, Shukkur AM, Sinan T, Al-Rashdan I. Accuracy of 64-multidetector-row computed tomography in the diagnosis of coronary artery disease. *Med Princ Pract* 2009; 18(4): 323-8.
- Carrascosa P, Capunay C, Deviggiano A, Goldsmit A, Tajer C, Bettinotti M, et al. Accuracy of low-dose prospectively gated axial coronary CT angiography for the assessment of coronary artery stenosis in patients with stable heart rate. *J Cardiovasc Comput Tomogr* 2010; 4(3): 197-205.
- Miller JM, Rochitte CE, Dewey M, Arbab-Zadeh A, Niinuma H, Gottlieb I, et al. Diagnostic performance of coronary angiography by 64-row CT. *N Engl J Med* 2008; 359(22): 2324-36.
- Coles DR, Smail MA, Negus IS, Wilde P, Oberhoff M, Karsch KR, et al. Comparison of radiation doses from multislice computed tomography coronary angiography and conventional diagnostic angiography. *J Am Coll Cardiol* 2006; 47(9): 1840-5.
- Piers LH, Dijkers R, Willems TP, de Smet BJ, Oudkerk M, Zijlstra F, et al. Computed

- tomographic angiography or conventional coronary angiography in therapeutic decision-making. *Eur Heart J* 2008; 29(23): 2902-7.
14. Leber AW, Johnson T, Becker A, von ZF, Tittus J, Nikolaou K, et al. Diagnostic accuracy of dual-source multi-slice CT-coronary angiography in patients with an intermediate pretest likelihood for coronary artery disease. *Eur Heart J* 2007; 28(19): 2354-60.
  15. de Graaf FR, Schuijf JD, van Velzen JE, Kroft LJ, de Roos A, Reiber JH, et al. Diagnostic accuracy of 320-row multidetector computed tomography coronary angiography in the non-invasive evaluation of significant coronary artery disease. *Eur Heart J* 2010; 31(15): 1908-15.
  16. Rodevand O, Hogalmen G, Gudim LP, Indrebo T, Molstad P, Vandvik PO. Limited usefulness of non-invasive coronary angiography with 16-detector multislice computer tomography at a community hospital. *Scand Cardiovasc J* 2006; 40(2): 76-82.
  17. Nieman K, Cademartiri F, Lemos PA, Raaijmakers R, Pattynama PM, de Feyter PJ. Reliable noninvasive coronary angiography with fast submillimeter multislice spiral computed tomography. *Circulation* 2002; 106(16): 2051-4.
  18. Vanhoenacker PK, Heijnenbroek-Kal MH, Van Heste R, Decramer I, Van Hoe LR, Wijns W, et al. Diagnostic performance of multidetector CT angiography for assessment of coronary artery disease: meta-analysis. *Radiology* 2007; 244(2): 419-28.
  19. Hamon M, Biondi-Zoccai GG, Malagutti P, Agostoni P, Morello R, Valgimigli M, et al. Diagnostic performance of multislice spiral computed tomography of coronary arteries as compared with conventional invasive coronary angiography: a meta-analysis. *J Am Coll Cardiol* 2006; 48(9): 1896-910.
  20. Taylor AJ, Cerqueira M, Hodgson JM, Mark D, Min J, O'Gara P, et al. ACCF/SCCT/ACR/AHA/ASE/ASNC/NASCI/SCAI/SCMR 2010 Appropriate Use Criteria for Cardiac Computed Tomography. A Report of the American College of Cardiology Foundation Appropriate Use Criteria Task Force, the Society of Cardiovascular Computed Tomography, the American College of Radiology, the American Heart Association, the American Society of Echocardiography, the American Society of Nuclear Cardiology, the North American Society for Cardiovascular Imaging, the Society for Cardiovascular Angiography and Interventions, and the Society for Cardiovascular Magnetic Resonance. *Circulation* 2010; 122(21): e525-e555.
  21. Pugliese F, Mollet NR, Hunink MG, Cademartiri F, Nieman K, van Domburg RT, et al. Diagnostic performance of coronary CT angiography by using different generations of multisection scanners: single-center experience. *Radiology* 2008; 246(2): 384-93.
  22. Raff GL, Chinnaiyan KM, Share DA, Goraya TY, Kazerooni EA, Moscucci M, et al. Radiation dose from cardiac computed tomography before and after implementation of radiation dose-reduction techniques. *JAMA* 2009; 301(22): 2340-8.
  23. Mori S, Endo M, Nishizawa K, Murase K, Fujiwara H, Tanada S. Comparison of patient doses in 256-slice CT and 16-slice CT scanners. *Br J Radiol* 2006; 79(937): 56-61.
  24. Steigner ML, Otero HJ, Cai T, Mitsouras D, Nallamshetty L, Whitmore AG, et al. Narrowing the phase window width in prospectively ECG-gated single heart beat 320-detector row coronary CT angiography. *Int J Cardiovasc Imaging* 2009; 25(1): 85-90.
  25. Einstein AJ, Henzlova MJ, Rajagopalan S. Estimating risk of cancer associated with radiation exposure from 64-slice computed tomography coronary angiography. *JAMA* 2007; 298(3): 317-23.
  26. Ropers D, Baum U, Pohle K, Anders K, Ulzheimer S, Ohnesorge B, et al. Detection of coronary artery stenoses with thin-slice multi-detector row spiral computed tomography and multiplanar reconstruction. *Circulation* 2003; 107(5): 664-6.
  27. Martuscelli E, Romagnoli A, D'Eliseo A, Razzini C, Tomassini M, Sperandio M, et al. Accuracy of thin-slice computed tomography in the detection of coronary stenoses. *Eur Heart J* 2004; 25(12): 1043-8.
  28. Raff GL, Gallagher MJ, O'Neill WW, Goldstein JA. Diagnostic accuracy of noninvasive coronary angiography using 64-slice spiral computed tomography. *J Am Coll Cardiol* 2005; 46(3): 552-7.
  29. Garcia MJ, Lessick J, Hoffmann MH. Accuracy of 16-row multidetector computed tomography for the assessment of coronary artery stenosis. *JAMA* 2006; 296(4): 403-11.

**How to cite this article:** Sajjadih A, Hekmatnia A, Keivani M, Asoodeh A, Pourmoghaddas M, Sanei H. **Diagnostic performance of 64-row coronary CT angiography in detecting significant stenosis as compared with conventional invasive coronary angiography.** *ARYA Atheroscler* 2013; 9(2): 157-63.