

Refractory Atrial Flutter, the Unusual Presentation of Covid-19 Infection in a Neonate: A Case Report and Review of Literature

Seyed Hossein Saadat⁽¹⁾, Marjan Tariverdi⁽²⁾, Mohammadreza Kargarfard Jahromi⁽³⁾, Deepak Sharma⁽⁴⁾, Nazanin Farahbakhsh⁽⁵⁾

Case Report

Abstract

INTRODUCTION: The accurate incidence of different cardiovascular consequences of COVID-19 in the pediatric population has been inadequately defined due to ongoing genotype changes in the virus. Although COVID-19 is known to increase inflammatory markers associated with atrial arrhythmias, the contemporary literature has poorly described new onset arrhythmias as a complication in previously healthy neonates with COVID-19.

CASE PRESENTATION: A twenty-day-old female term neonate, born by caesarean section with immediate cry, developed labored breathing, cyanosis, and tachycardia after having close contact with a confirmed case of COVID-19. The neonate developed atrial flutter, which was refractory to cardioversion and drugs, namely Amiodarone, Flecainide, and Propranolol. The authors treated the neonate with IVIG. This is the first reported case of atrial flutter in the neonatal period secondary to COVID-19.

CONCLUSION: Since the start of the SARS-CoV-2 pandemic, all attention and concerns have been mainly on respiratory manifestations and complications. The cardiovascular complications and treatment have been neglected. This case reports tachyarrhythmia (Atrial Flutter) as an unusual presentation of acute COVID-19 in the neonatal population and shows the role of IVIG in the treatment of refractory arrhythmias.

Keywords: Atrial Flutter, Neonates, Covid-19

Date of submission: 2023-May-05, Date of acceptance: 2023-Oct-29

Introduction

Cardiac complications of the SARS-CoV virus have been reported in children, such as coronary artery involvement, myocarditis, and arrhythmia. The accurate incidence of cardiovascular consequences of COVID-19 in children is inadequately defined due to ongoing genotype changes in the virus¹. Available literature has focused mainly on the

adult population; therefore data are limited regarding cardiovascular manifestations in the pediatric population. Furthermore, published literature about COVID-19 infection in neonates is hardly available. It is presumed that the incidence of cardiac complications is low, especially in the acute phase of the disease². New-onset atrial fibrillation and atrial flutter have been reported in hospitalized adult patients with COVID-19, suggesting that the

1- Faculty of Medicine, Clinical Research Development Center of children's Hospital, Hormozgan University of Medical Sciences, Bandar Abbas, IraC

2- Assistant Professor of Pediatric Infectious Disease Department of Pediatrics, School of Medicine Hormozgan University of Medical Sciences

3- Assistant Professor of Pediatric Cardiology Department of Pediatrics, School of Medicine Pediatrics hospital, Hormozgan University of Medical Science, Bandar Abbas, Iran

4- Department of neonatology, NIMS Medical College, SobhaNgar, Jaipur, Rajasthan, India

5- Department of Pediatric Pulmonology, Mofid Pediatrics Hospital, Shahid Beheshti University of Medical Sciences, Tehran, Iran

Address for correspondence: Nazanin Farahbakhsh, Assistant Professor, Department of Pediatric Pulmonology, Mofid Pediatrics Hospital, Shahid Beheshti University of Medical Sciences, Tehran, Iran. E-mail address: nazanin26farahbakhsh@yahoo.com

arrhythmias and COVID-19 are related to the general inflammatory state, which is seen in COVID-19³. Although COVID-19 was known to increase inflammatory markers associated with atrial arrhythmias, the published literature has not reported new onset arrhythmias as a complication in previously healthy neonates with COVID-19. Here, the authors report the first case of new onset atrial flutter in a 20-day-old neonate, which was refractory to conventional treatment.

Case Presentation

A twenty-day-old female neonate presented in the emergency department with complaints of difficulty in breathing and poor feeding. The neonate was born by cesarean section at 38 weeks with a birth weight of 3600 grams and had an immediate cry after birth. She was exclusively breastfed. The mother had

no history of any specific disease during pregnancy and no history of hospitalization after birth. At the first examination in the authors' hospital, the neonate had central cyanosis (O_2 saturation=70%), tachycardia (HR=285/min), tachypnea (RR=90/min), and hypothermia ($T=35.7^\circ$) with normal blood pressure (BP=65/40 mmHg). The neonate was slightly irritable. Lung auscultation was normal. Other system examinations were also normal. The neonate had a history of contact with three SARS-CoV-2 positive persons, one of whom was her mother.

Initially, the neonate was transferred to the NICU under an incubator, and the necessary measures were taken to make her normothermic. Intravenous fluid and oxygen support were started immediately. A sepsis workup was performed. The results of the laboratory tests are summarized in Table 1.

Table 1. Laboratory results

Lab test	value	Lab test	value
PH(ABG)	7.36	AST	41U/L (10-40)
PaCO2	26.5	ALT	56 U/L (10-50)
PaO2	32.3	ALP	547 U/L (48-406)
HCO3	14.6 mmol/L	LDH(1 st day / 2 nd day)	446 U/L (160-450) 798U/L (160-450)
BE	- 10.8 MMOL/L	CPK(1 st day / 2 nd day)	82 U/L (< 400) 281 U/L (< 400)
WBC	$11 \times [10]^3/\mu\text{L}$ (5000 – 15000) Neutrophil = 50% Lymphocyte = 43.8% Mixed = 6.2 %	Bilirubin	Total =6.4mg/dL Direct = 0.5mg/dL
RBC	$4.99 \times [10]^6/\mu\text{L}$ (3.9 – 5.8)	D-Dimer	3392 ng/dL (0-500)
Hb	12.8 /dL (12-18)	Troponin	19.7 ng/L(<18)
HCT	39.7 %. (32-49)	ferritin	1645 $\mu\text{g/L}$ (200-600)
MCV	79.6 fl (95-105)	Urea	40 mg/dL (15-45)
MCH	25.7 pg (27-32)	Creatinine	0.6 mg/dL (0.44-0.66)
MCHC	32.2 (31-36)	Na	137 mEq/L (135-145)
PLT	$640 \times [10]^3/\mu\text{L}$ (150-450)	K	3.5 mEq/L (3.5-5.4)
Esr	2 mm (1-10)	Ca	9.8 mg/dL (9-10.5)
Crp	C Reactive Protein = 1 mg/dL (0-6)	p	5mg/dl
Blood culture	Negative	Blood sugar	81 mg/dL (60-110)

A Chest X-ray (CXR) was taken, and an RT-PCR test for the COVID-19 virus was sent. An ECG was performed for the patient due to tachycardia. An arrhythmia with a probability of supraventricular tachycardia (SVT) was observed on the ECG. Intravenous adenosine 100 mg/kg and 200 mg/kg were administered twice, but the arrhythmia did not respond to adenosine. The re-ECG showed saw-tooth flutter waves, suggesting atrial flutter (Figure 1). The patient was given three DC cardioversions. 1 J/kg was given in the first round and 2 J/kg in the second round, but the arrhythmia did not respond to these actions. The neonate had refractory atrial flutter. Due to the lack of response to treatment, amiodarone was started for the patient at a dose of 5 mcg/kg/min. Simultaneously, the neonate became normothermic. There was persistence of atrial flutter after 12 hours of amiodarone infusion. Vital signs at this point in time were a pulse rate of 250/min, a respiratory rate of 85/min, and a mean blood pressure of 40mmHg. Echocardiography performed showed an Ejection Fraction (EF) of 30% and there was severe TR and severe MR. The patient underwent re-DC cardioversion three times, the first time being 1 J/kg and the second and third times being 2 J/kg, but the arrhythmia did not respond. Amiodarone was discontinued

and oral flecainide 3 mg/kg every 12 hours and propranolol 1 mg/kg every 8 hours were started after discussion with a pediatric cardiologist. The arrhythmia was resistant to both flecainide and propranolol.

As the patient had refractory AF with a positive history of close contact with confirmed cases of COVID-19, the authors considered the patient as a case of arrhythmia secondary to Covid-19 myocarditis. Consultation with the infectious disease department was done and IVIG was started for the patient (1 gram/kg/day for 2 days). After starting the first dose of IVIG, a dramatic response to atrial flutter was observed and the heart rate became normal after two days, with the heart rate being 120 beats per minute. On repeat echocardiography, the Ejection Fraction increased to 50% with Moderate to severe TR and Mild to Moderate MR. The Ejection fraction reached 65% with Mild MR and Mild TR as seen in the echocardiography done four days later. The patient was discharged with flecainide and propranolol. Two months after discharge, flecainide was tapered and discontinued and the patient was on propranolol. The propranolol was also discontinued at age 6 months. The patient had been followed for one year and there was no episode of any arrhythmia in follow up.

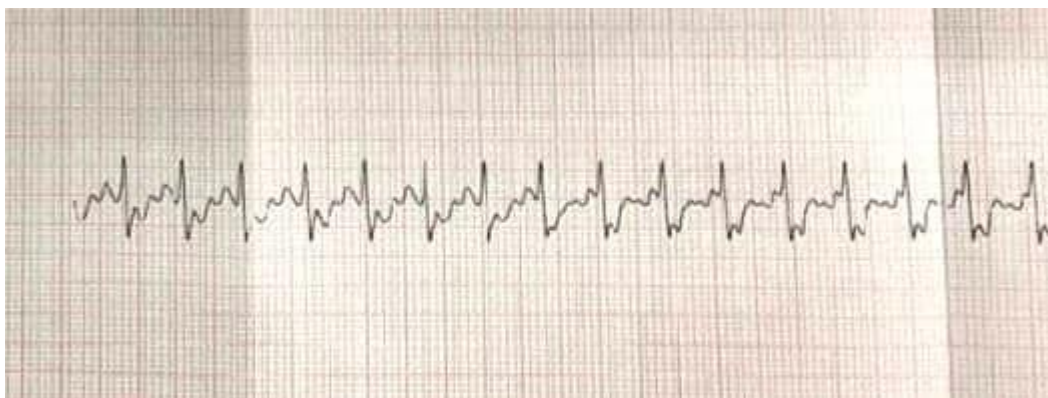


Figure 1. ECG from the patient (lead 3)

Discussion

Although COVID-19 is mostly characterized by respiratory symptoms, cardiovascular pathology and cardiac complications frequently arise in COVID-19 patients, thus increasing morbidity and mortality⁴. Cardiac involvement is associated with acute COVID-19 in children, similar to other viruses¹. Hopkins et al. reported a neonate with COVID-19 infection who developed supraventricular tachyarrhythmia⁵. The index case is unique as the patient presented with a new onset atrial flutter in the setting of acute COVID-19 infection during a pandemic, which to the best of the authors' knowledge, is the first case to be reported in the neonatal period.

Only two cases of AF with COVID-19 infection have been reported previously. One was a 17-year-old girl who was COVID-19 positive two weeks prior to the initiation of atrial fibrillation. She was treated with cardioversion⁶. The second case was a 15-year-old COVID-19 positive girl with hypotension who developed atrial fibrillation responsive to amiodarone⁷. In contrast to the previous cases where both were in adolescence and were responsive to conventional treatment for AF, the index case was unique as it is the first case of atrial flutter secondary to COVID-19 infection in the neonatal period and was refractory to cardioversion and amiodarone.

Atrial flutter in newborns is mostly well tolerated. Furthermore, new onset atrial flutter with a structurally normal heart has a good prognosis with a good response to synchronized electrical cardioversion⁸. The authors' case was unique as the Atrial Flutter was refractory to both cardioversion and amiodarone.

In published literature, Intravenous Immunoglobulin (IVIG) has not been mentioned as a treatment strategy in patients with Atrial Flutter. Some studies have shown the beneficial effect of high-dose IVIG in myocarditis in children⁹. As the authors considered the patient's tachyarrhythmia secondary to inflammation from acute COVID-19, they started her on IVIG. This had a dramatic effect on stopping the Atrial

Flutter. Yozgat et al. first reported treating AF secondary to myocarditis in pediatrics with IVIG in 2021. They described a 12-year-old boy with fulminant myocarditis and refractory AF¹⁰.

Conclusion

Since the start of the SARS-CoV-2 pandemic, all attention and concerns have been mainly on respiratory manifestations and complications. The cardiovascular complications and treatment have been neglected. This case reports tachyarrhythmia (Atrial Flutter) as an unusual presentation of MISC in the neonatal population and shows the role of IVIG in the treatment of refractory arrhythmias.

Declarations

Ethics approval and consent to participate: Not applicable.

Consent for publication: Written consent was obtained from the patient's parents for publication of this case report.

Competing interests: The authors declare that they have no conflicts of interest

Funding: None

Authors' contributions: SHS and MT examined the patient. MK and NF was consulted on appropriate laboratory tests, collected the samples, and performed the tests. NF took a comprehensive history from the patient's parents. NF and SHS wrote the manuscript. DS revised the manuscript. All authors read and approved the final manuscript.

Acknowledgements: The authors are sincerely thankful to their counsellors in the Clinical Research Development Center of Children's Hospital, Bandar Abbas, Iran.

References

1. Alsaied T, Tremoulet AH, Burns JC, Saidi A, Dionne A, Lang SM, Newburger JW, de Ferranti S, Friedman KG. Review of Cardiac Involvement in Multisystem Inflammatory Syndrome in Children. *Circulation* 2021; 143(1): 78-88. <https://doi.org/10.1161/CIRCULATIONAHA.120.049836>
2. Wei M, Yuan J, Liu Y, Fu T, Yu X, Zhang ZJ. Novel Coronavirus Infection in Hospitalized Infants Under 1 Year of Age in China. *JAMA* 2020; 323(13): 1313-1314. <https://doi.org/10.1001/jama.2020.2131>
3. Dherange P, Lang J, Qian P, Oberfeld B, Sauer WH, Koplan B, Tedrow U. Arrhythmias and COVID-19: A Review. *JACC Clin Electrophysiol.* 2020; 6(9): 1193-1204. <https://doi.org/10.1016/j.jacep.2020.08.002>
4. Kohli U, Lodha R. Cardiac Involvement in Children With COVID-19. *Indian Pediatr* 2020; 57(10): 936-939. <https://doi.org/10.1007/s13312-020-1998-0>
5. Hopkins KA, Webster G. Aberrated supraventricular tachycardia associated with neonatal fever and COVID-19 infection. *BMJ Case Rep* 2021; 14(4): e241846. <https://doi.org/10.1136/bcr-2021-241846>
6. Santi AD, Aquino P, Dorfman M. Atrial fibrillation in a child with COVID-19 infection. *Cardiol Young* 2021; 31(2): 318-321. <https://doi.org/10.1017/S1047951120003893>
7. Kohli U, Meinert E, Chong G, Teshler M, Jani P. Fulminant myocarditis and atrial fibrillation in child with acute COVID-19. *J Electrocardiol* 2020; S0022-0736(20): 30571-9. <https://doi.org/10.1016/j.jelectrocard.2020.10.004>
8. Yılmaz-Semerci S, Bornaun H, Kurnaz D, Cebeci B, Babayigit A, Büyükkale G, Çetinkaya M. Neonatal atrial flutter: Three cases and review of the literature. *Turk J Pediatr* 2018; 60(3): 306-309. <https://doi.org/10.24953/turkped.2018.03.011>
9. Al-Saeed S, Dilawar M. Combined use of intravenous immune globulin and steroid for acute myocarditis in pediatric population. *Heart Views* 2008; 9: 137-41. <https://journals.lww.com/hrtv/toc/2008/09040>
10. Yozgat CY, Yesilbas O, Uzuner S, Bayramova N, Ergun G, Nurmammadova L, Tekin E, Temur HO, Yozgat Y. The Possible Role of IVIG in the Treatment of Atrial Fibrillation Accompanied by Fulminant Myocarditis in a 12-Year-Old Pediatric Patient. *Case Rep Pediatr* 2021; 2021: 6689865. <https://doi.org/10.1155/2021/6689865>

How to cite this article: Saadat SH, Tariverdi M, Kargarfard Jahromi M, Sharma D, Farahbakhsh N. **Refractory Atrial Flutter, the Unusual Presentation of Covid-19 Infection in a Neonate: A Case Report and Review of Literature.** *ARYA Atheroscler* 2023; 19(6): 44-48.