



## Trans-snuff box approach as a new access site for coronary angiography and angioplasty versus trans-radial approach in terms of feasibility, safety, and complications

Farshad Roghani-Dehkordi<sup>(1)</sup> , Alireza Riazi<sup>(1)</sup>, Davood Shafie<sup>(2)</sup>,  
Alireza Khosravi<sup>(3)</sup>, Masoumeh Sadeghi<sup>(4)</sup>, Mehrbod Vakhshoori<sup>(2)</sup>, Soraya Massoudi<sup>(5)</sup>,  
Mohammad Kermani-Alghoraishi<sup>(1)</sup> 

### Original Article

#### Abstract

**BACKGROUND:** The feasibility and safety of coronary angiography (CAG) and angioplasty via trans-snuffbox approach (TSA) is still concerned; therefore, in this study, we aimed to assess possible complications occurring after TSA versus trans-radial approach (TRA).

**METHODS:** This prospective observational study was undertaken from June 2017 till March 2018. Individuals aged at least 18 years who were admitted for CAG through upper extremity were eligible and categorized to TSA (n = 70) and TRA (n = 56) groups. Occurrence of complications including hematoma, pain or paresthesia, pseudoaneurysm formation, arterial obstruction, limb ischemia, and major adverse cardiovascular events (MACE) including death, myocardial infarction (MI), stroke, and emergency vessel revascularization was assessed after the procedure and in two separate visits three and six months afterwards.

**RESULTS:** The mean age of participants in TSA and TRA groups was  $55.1 \pm 9.7$  and  $56.5 \pm 9.6$  years, respectively (P = 0.415). Men were the dominant group in both approaches [TSA: 44 (62.8%), TRA: 36 (64.3%), P = 0.868]. Success rates in TSA and TRA were 88.6% and 94.6%, respectively (P = 0.230). Radial artery occlusion (RAO) was reported in two (3.2%) and one (1.8%) case in TRA and TSA, respectively (P = 0.653). MACE incidence was not significantly different in TSA compared with TRA group (1.8% vs. 4.8%, respectively, P = 0.389). There was no major procedural complication, neither in TSA nor in TRA category.

**CONCLUSION:** Our results revealed that TSA could be classified as an alternative modality to other common CAG and angioplasty methods due to its high safety rate and lower complications. Several comprehensive population-based studies are necessary for confirming these findings.

**Keywords:** Radial Artery; Vascular Access Devices; Coronary Angiography; Coronary Angioplasty

*Date of submission:* 23 May 2019, *Date of acceptance:* 05 May 2020

#### Introduction

Since the initiation of coronary angiography (CAG) in 1929, this procedure became one of the most common approaches in terms of diagnosis and treatment of coronary artery diseases (CADs).<sup>1</sup> Based on human vascular system, there are several angiographic procedures available including trans-femoral approach (TFA), trans-radial approach (TRA), and trans-ulnar approach (TUA), that each

one has its own advantages and disadvantages.<sup>2-6</sup>

**How to cite this article:** Roghani-Dehkordi F, Riazi A, Shafie D, Khosravi A, Sadeghi M, Vakhshoori M, et al. **Trans-snuff box approach as a new access site for coronary angiography and angioplasty versus trans-radial approach in terms of feasibility, safety, and complications.** ARYA Atheroscler 2020; 16(6): 263-8.

1- Interventional Cardiology Research Center, Cardiovascular Research Institute, Isfahan University of Medical Sciences, Isfahan, Iran

2- Heart Failure Research Center, Cardiovascular Research Institute, Isfahan University of Medical Sciences, Isfahan, Iran

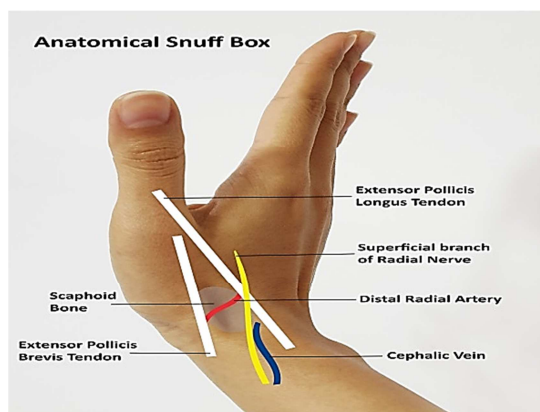
3- Hypertension Research Center, Cardiovascular Research Institute, Isfahan University of Medical Sciences, Isfahan, Iran

4- Cardiac Rehabilitation Research Center, Cardiovascular Research Institute, Isfahan University of Medical Sciences, Isfahan, Iran

5- Isfahan Cardiovascular Research Center, Cardiovascular Research Institute, Isfahan University of Medical Sciences, Isfahan, Iran

Address for correspondence: Mohammad Kermani-Alghoraishi; Interventional Cardiology Research Center, Cardiovascular Research Institute, Isfahan University of Medical Sciences, Isfahan, Iran; Email: [sm.kermani@med.mui.ac.ir](mailto:sm.kermani@med.mui.ac.ir)

For instance, the most traditional method named TFA was associated with higher rates of complications such as bleeding or patient discomfort versus its advantages of possibility of passing large-bore devices.<sup>6</sup> On the other hand, trans-radial angiography and intervention first reported by Campeau<sup>7</sup> in 1989, and Kiemeneij and Laarman<sup>8</sup> in 1993, respectively, demonstrated to be superior to TFA in terms of multiple strengths including less likelihood of bleeding, decreased hospital stay length, early mobilization, lower costs, and patient satisfaction in a way that it is becoming the first choice for CAG.<sup>4,9,10</sup> A novel CAG method which its safety has been demonstrated in multiple researches is trans-snuffbox approach (TSA). Its anatomical position contained triangular depressed shape on dorsum of hand at levels of carpal bones including scaphoid and trapezium which is also known as radial fossa clearly visible by thumb extension. Extensor pollicis longus (EPL) and extensor pollicis brevis (EPB) bounded medial and lateral borders of this triangle, respectively. This collection consisted of distal radial artery (RA), cephalic vein, and a branch of radial nerve (Figure 1).<sup>11</sup> TSA was previously suggested and introduced by Kaledin et al.<sup>12</sup> in 2014, Babunashvili<sup>13</sup> in 2016, Roghani-Dehkordi<sup>14</sup> in 2016, and Kiemeneij<sup>15</sup> in 2016.



**Figure 1.** Schematic of anatomical snuffbox

This new technique has some priorities compared with TRA like the followings: early hemostasis due to carpal bones and small distal RA diameter and no requirements for wrist compression, possibility of shifting to TRA in times of TSA failure, less likelihood of compartment syndrome and providing more RA length for candidate patients for coronary artery bypass graft (CABG).<sup>11,16,17</sup> However, this technique is not free from disadvantages and some of them include more needling difficulties, increased chance of nerve irritation, and inability to pass

through larger sheaths.<sup>11</sup>

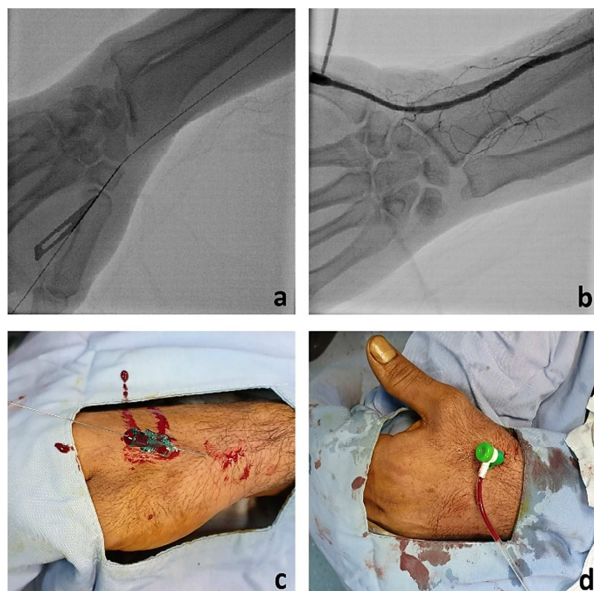
To the best of our knowledge, there are a few studies comparing outcomes of TRA and TSA which revealed controversial results. Due to inconsistencies in results of those aforementioned procedures, in this study, we aimed at evaluating feasibility, safety, and complications of TSA compared to TRA in our centers.

## Materials and Methods

This prospective observational study was performed in two distinct referral hospitals (Shahid Chamran Heart Center and Khorshid Hospital) located in Isfahan, Iran. From June 2017 to March 2018, anyone aged more than 18 years who had indications for CAG was eligible to be recruited in our study. Presence of cardiogenic shock with/without hemodynamic instability, suffering from acute coronary syndrome (ACS), being under hemodialysis treatment, past history of CABG, elective candidate for TFA, existence of vascular disorders of upper limb, Raynaud's disease, or hand problems including deformities, osteomyelitis, tenosynovitis, or history of scaphoid fracture were defined as exclusion criteria. Before initiation of procedure, all research aims were explained to each individual and a written consent form was signed by each participant before procedure initiation. A total of 126 cases of CAG were performed through upper extremity; 70 patients underwent TSA and 56 of them were categorized in TRA. This study was approved by the Ethics Committee affiliated to Isfahan University of Medical Sciences (IR.MUI.MED.REC.1397.278).

After preparation of puncture site, 2-2.5 ml of lidocaine 2% was injected subcutaneously in anatomic snuffbox and 3 cm above first proximal wrist crease in TSA and TRA, respectively. Extra intravenous midazolam (1-2 mg) plus 0.4 mg sublingual trinitroglycerin (TNG) was administered in order to decrease arterial spasm and patient stress. A 21-gauge (G) needle was used for puncturing desired artery and 5-6 French sheaths were passed through 0.018-inch guidewires (Figure 2). In cases of failure, 0.014-inch guidewire was utilized alternatively, especially among patients who underwent TSA. Spasmolytic cocktail which consisted of 200-250 micrograms of nitrate and verapamil (2.5 mg) was introduced through the sheaths. Unfractionated heparin [2500-5000 international unit (IU)] was used as an anticoagulant in both groups. After TSA termination, the first 10 to 15 minutes of initial hemostasis was

accomplished by local pressure using contralateral thumb over puncture site and other four fingers below the patients' wrist with addition of appropriate bandage packs for completion of hemostasis in the next 1-2 hours. TR band was used for inducing hemostasis after sheath extraction in individuals who underwent TRA.



**Figure 2.** Angiographic depiction of the snuffbox approach (a, b) and cannulation of distal radial artery (RA) in anatomical snuffbox (c, d)

Age, sex, body mass index (BMI), presence/absence of hypertension (HTN), diabetes mellitus (DM), dyslipidemia, smoking status, family history of cardiovascular diseases (CVDs), and past history of myocardial infarction (MI) were recorded in the checklist.

Correct arterial cannulation in each group was defined as successful access. Furthermore, properties of each approach were assessed by measurement of pre-defined variables including access and total procedure time plus fluoroscopy time as well as contrast volume. Complications including hematoma, pain/paresthesia, pseudoaneurysm formation, arterial obstruction, limb ischemia, and major adverse cardiovascular events (MACE) including death, MI, stroke, and emergency vessel revascularization were assessed after procedure and in two distinct clinical visits three and six months apart by the same interventional cardiologist.

Continuous and categorical variables were reported as mean  $\pm$  standard deviation (SD) and frequencies with percentages, respectively. The basic characteristics and procedural properties were compared between groups. The comparisons were made using the independent t-test (quantitative variables) and chi-square test (qualitative variables). SPSS software (version 15.0, SPSS Inc., Chicago, IL, USA) was used for all analyses and P-values less than 0.05 were considered statistically significant.

## Results

The mean age of our study population in TSA and TRA group was  $55.1 \pm 9.7$  and  $56.5 \pm 9.6$  years, respectively ( $P = 0.415$ ). Men were the dominant group in both approaches [TSA: 44 (62.8%), TRA: 36 (64.3%),  $P = 0.868$ ]. In 70 patients who underwent TSA, we had a successful access rate of 88.6% ( $n = 62$ ), while this percentage was 94.6% for TRA (53 out of 56 cases) ( $P = 0.230$ ). Table 1 provides data of general characteristics of individuals according to distinct arterial approach.

**Table 1.** Basic characteristics of participants in trans-snuffbox and trans-radial methods

Variables	TSA (n = 70)	TRA (n = 56)	P
Age (year)	$55.1 \pm 9.7$	$56.5 \pm 9.6$	0.415
BMI ( $\text{kg}/\text{m}^2$ )	$28.4 \pm 3.3$	$27.2 \pm 3.9$	0.074
Gender (male)	44 (62.8)	36 (64.3)	0.868
HTN	40 (57.1)	38 (67.8)	0.218
DM	52 (74.2)	45 (80.3)	0.421
Dyslipidemia	22 (31.4)	16 (28.6)	0.728
Current smoker	47 (67.1)	44 (78.6)	0.154
Family history of CVDs	3 (4.3)	6 (10.7)	0.163
History of previous MI	13 (18.6)	10 (17.8)	0.917
CAG success	62 (88.6)	53 (94.6)	0.230
PCI	35 (50.0)	20 (35.7)	0.108

Values are expressed as mean  $\pm$  standard deviation (SD) for quantitative variables and number (%) for qualitative variables. Chi-square test and independent t-test were used where appropriate.

TSA: Trans-snuffbox approach; TRA: Trans-radial approach; BMI: Body mass index; HTN: Hypertension; DM: Diabetes mellitus; CVD: Cardiovascular disease; MI: Myocardial infarction; CAG: Coronary angiography; PCI: Percutaneous coronary intervention

**Table 2.** Procedural properties of trans-snuffbox approach (TSA) and trans-radial approach (TRA)

Variables		TSA (n = 62)	TRA (n = 53)	P
Access time (minute)		4.75 ± 0.46	4.65 ± 0.65	0.419
Total procedure time (minute)	CAG	17.50 ± 5.10	16.90 ± 4.80	0.333
	PCI	32.50 ± 8.30	33.40 ± 7.70	0.432
Fluoroscopy time (minute)	CAG	5.50 ± 1.10	5.10 ± 1.80	0.451
	PCI	10.60 ± 1.90	10.10 ± 2.80	0.265
Contrast volume (ml)	CAG	122.00 ± 20.00	127.00 ± 15.00	0.764
	PCI	256.00 ± 22.00	250.00 ± 19.00	0.523

Values are mean ± standard deviation (SD). Independent t-test was used.

TSA: Trans-snuffbox approach; TRA: Trans-radial approach; CAG: Coronary angiography; PCI: Percutaneous coronary intervention

Although participants who underwent TSA had higher BMI means ( $28.4 \pm 3.3$  vs.  $27.2 \pm 3.9$ ), their differences was not statistically significant ( $P = 0.074$ ). There were no remarkable differences between the groups in term of HTN, DM, dyslipidemia, smoking status, CVDs family history, or previous MI experience. 35 (50.0%) of TSA and 20 (35.7%) of TRA patients underwent percutaneous coronary intervention (PCI) in addition to CAG.

Procedural characteristics of TSA and TRA, as depicted in table 2, were the same and no significant differences were found in terms of access and total procedure duration or fluoroscopy time as well as contrast volume between two groups.

In three- and six-month follow-up duration, there were no adverse complications including hematoma, pain or paresthesia, pseudoaneurysm formation, and limb ischemia in neither TSA nor TRA groups as well as in-hospital period. Radial artery occlusion (RAO) was found in two (3.2%) and one (1.8%) patient in TRA and TSA, respectively ( $P = 0.653$ ). The only relation found in terms of MACE (death, MI, stroke, and emergency vessel revascularization) was mostly observed in patients who underwent TRA in comparison to TSA [3 (4.8%) vs. 1 (1.8%), respectively] that was non-significant ( $P = 0.389$ ).

## Discussion

The ultimate aim of the current study was evaluating the relation between TSA and TRA in terms of complications. Our findings revealed that there was not any incidence of hematoma, pain or paresthesia, pseudoaneurysm formation, and limb ischemia. MACE occurred less frequently in patients who underwent TSA comparing to TRA group. Since this approach was associated with lower rates of complications, it could be utilized as an alternative modality on their own or in cases of failure of other arterial approaches. Several studies were in agreement with our outcomes. For instance, 100 patients were divided equally into two groups and

underwent CAG with either TRA or TSA. Their final outcomes showed that patients with experience of TRA had higher prevalence of hematoma, numbness, and spasm and stayed in hospital for a longer duration ( $P < 0.001$ ).<sup>18</sup> Likewise, 54 individuals with mean age of 59.3 years were recruited in a study in order to evaluate the feasibility of CAG with left snuffbox artery. In addition to 100% success rate, no cases of RAO, hand paresthesia, or hematoma were reported.<sup>19</sup> Similar findings were also found in 94% (142 out of 151 cases) of successful snuffbox approaches showing no ischemic adverse events with an exception of mild bleeding reported in only one subject.<sup>20</sup> Roghani-Dehkordi et al. performed the aforementioned approach on 235 individuals with a success rate of 94.1%. Their results declared that complications including distal forearm ecchymosis and RAO were observed in 5.1% and 0.9% of patients, respectively, with no reports of hematoma or major cardiovascular events including infection, need for amputation, nerve palsy, or hand dysfunction.<sup>16</sup> With an 88% success rate in CAG or angioplasty with left snuffbox artery performed on 150 individuals with mean age of  $65.9 \pm 12.8$  years with dominant male gender, Kim et al. found that except forearm bruising and edema observed in 4.9% of patients which healed conservatively, no major vascular adverse events occurred.<sup>21</sup>

On the other hand, few studies revealed opposing results especially in terms of procedure process. Aoi et al. performed a retrospective study in order to investigate the association of distal RA approach and conventional approach based on safety and complications. They enrolled 202 individuals with distal RA approach and 206 subjects with traditional TRA as control group. Their outcomes suggested that in spite of more than 90% of successful access rate in each group, distal RA approach was associated with prolonged access time and more prevalence of minor bleeding at puncture site compared to conventional RA access

( $P < 0.001$ ) with no considerable differences in terms of hematoma formation ( $P = 0.770$ ).<sup>22</sup> Moreover, Koutouzis et al. randomly assigned 200 individuals prepared for CAG into two distinct groups of TSA and TRA and evaluated their outcomes according to modality itself and their complications. Their results revealed that although there were no statistically significant differences in terms of their pre-defined complications including RAO, hematoma, or vascular spasm, patients who underwent TSA had less successful access rate, prolonged access time, and higher rates of attempts and skin punctures comparing to traditional approach (30% vs. 2%,  $P < 0.001$ ,  $269 \pm 251$  seconds vs.  $140 \pm 161$  seconds,  $P < 0.001$ ,  $6.8 \pm 6.2$  vs.  $3.4 \pm 4.5$ ,  $P < 0.001$ , and  $2.4 \pm 1.7$  vs.  $1.6 \pm 1.2$ ,  $P < 0.001$ , respectively).<sup>23</sup>

In addition to implementation of both TSA and TRA by expert physician in this regard, reasonable follow-up duration enabling us to assess occurrence of probable complications in each group by the same interventional cardiologist were some strengths of this study. By the way, quite small sample size which might influence the generalization of our findings would be presumed as a limitation in this research project. Furthermore, we did not gather data about each modality itself which might be effective in concluding feasibility of procedures.

### Conclusion

Our findings suggested that TSA could be categorized as an alternative CAG method compared to other previously-announced methods due to its high safety and few complications. Multiple comprehensive population-based studies are required for proving these outcomes.

### Acknowledgments

The authors gratefully acknowledge Mahshad Hosseini (Art University of Isfahan) for her cooperation and editing this paper. This study has been derived from interventional cardiology fellowship dissertation (No. 397653) approved by Isfahan University of Medical Sciences.

### Conflict of Interests

Authors have no conflict of interests.

### References

- Mueller RL, Sanborn TA. The history of interventional cardiology: Cardiac catheterization, angioplasty, and related interventions. *Am Heart J* 1995; 129(1): 146-72.
- Roghani-Dehkordi F, Mansouri R, Khosravi A, Mahaki B, Akbarzadeh M, Kermani-Alghoraishi M. Transulnar versus transradial approach for coronary angiography and angioplasty: Considering their complications. *ARYA Atheroscler* 2018; 14(3): 128-31.
- Mason PJ, Shah B, Tamis-Holland JE, Bittl JA, Cohen MG, Safirstein J, et al. An update on radial artery access and best practices for transradial coronary angiography and intervention in acute coronary syndrome: A scientific statement from the American Heart Association. *Circ Cardiovasc Interv* 2018; 11(9): e000035.
- Liu P, Gao XL, Li BF, Ding XZ, Wang ZH, Dang YP, et al. Radial versus femoral artery access for percutaneous coronary angiography and intervention: A systematic review and meta-analysis of randomized controlled trials in Chinese population. *Int J Clin Exp Med* 2015; 8(10): 17151-66.
- Sattur S, Singh M, Kaluski E. Trans-ulnar catheterization and coronary interventions: From technique to outcomes. *Cardiovasc Revasc Med* 2017; 18(4): 299-303.
- Al-Azizi KM, Lotfi AS. The distal left radial artery access for coronary angiography and intervention: A new era. *Cardiovasc Revasc Med* 2018; 19(8S): 35-40.
- Campeau L. Percutaneous radial artery approach for coronary angiography. *Cathet Cardiovasc Diagn* 1989; 16(1): 3-7.
- Kiemeneij F, Laarman GJ. Percutaneous transradial artery approach for coronary stent implantation. *Cathet Cardiovasc Diagn* 1993; 30(2): 173-8.
- Brener MI, Bush A, Miller JM, Hasan RK. Influence of radial versus femoral access site on coronary angiography and intervention outcomes: A systematic review and meta-analysis. *Catheter Cardiovasc Interv* 2017; 90(7): 1093-104.
- Caputo RP, Tremmel JA, Rao S, Gilchrist IC, Pyne C, Pancholy S, et al. Transradial arterial access for coronary and peripheral procedures: executive summary by the Transradial Committee of the SCAI. *Catheter Cardiovasc Interv* 2011; 78(6): 823-39.
- Roh JH, Lee JH. Distal radial approach through the anatomical snuff box for coronary angiography and percutaneous coronary intervention. *Korean Circ J* 2018; 48(12): 1131-4.
- Kaledin A, Kochanov I, Podmetin P, Ardeev VN. Distal radial artery in endovascular interventions [Online]. [cited 2017]; Available from: URL: [https://www.researchgate.net/publication/319162208\\_Distal\\_radial\\_artery\\_in\\_endovascular\\_interventions](https://www.researchgate.net/publication/319162208_Distal_radial_artery_in_endovascular_interventions)
- Babunashvili A. Novel snuff-box technique for trans-radial approach: Let's go distal. *Proceedings of the Aim-Radial* 2016; 2016: 22-3.

14. Roghani-Dehkordi F. Merits of more distal accesses in the hand for coronary angiography and intervention. Proceedings of the 4<sup>th</sup> International Cardiovascular Joint Congress in Isfahan; 2016 Nov. 24-25; Isfahan, Iran.
15. Kiemeneij F. Left distal transradial access in the anatomical snuffbox for coronary angiography (ldTRA) and interventions (ldTRI). *EuroIntervention* 2017; 13(7): 851-7.
16. Roghani-Dehkordi F, Hashemifard O, Sadeghi M, Mansouri R, Akbarzadeh M, Dehghani A, et al. Distal accesses in the hand (two novel techniques) for percutaneous coronary angiography and intervention. *ARYA Atheroscler* 2018; 14(2): 95-100.
17. Davies RE, Gilchrist IC. Back hand approach to radial access: The snuff box approach. *Cardiovasc Revasc Med* 2018; 19(3 Pt B): 324-6.
18. Amin MR, Singha CK, Banerjee SK, Hoque H, Mahabub SE, Hoque M, et al. Comparison of distal transradial in the anatomical snuffbox versus conventional transradial access for coronary angiography and intervention-an experience in 100 cases. *Univ Heart J* 2017; 13(2): 40-5.
19. Soydan E, Akin M. Coronary angiography using the left distal radial approach-An alternative site to conventional radial coronary angiography. *Anatol J Cardiol* 2018; 19(4): 243-8.
20. Toledo JF, Gubolino LA, Teixeirens PT, Bragalha AM, Filho IJ. Diagnostic and interventional coronary procedures by the distal radial artery in the anatomical snuffbox: A real world analysis. *J Cardiovasc Dis Diagn* 2018; 6(5): 1000337.
21. Kim Y, Ahn Y, Kim I, Lee DH, Kim MC, Sim DS, et al. Feasibility of coronary angiography and percutaneous coronary intervention via left snuffbox approach. *Korean Circ J* 2018; 48(12): 1120-30.
22. Aoi S, Htun WW, Freeo S, Lee S, Kyaw H, Alfaro V, et al. Distal transradial artery access in the anatomical snuffbox for coronary angiography as an alternative access site for faster hemostasis. *Catheter Cardiovasc Interv* 2019; 94(5): 651-7.
23. Koutouzis M, Kontopodis E, Tassopoulos A, Tsiafoutis I, Katsanou K, Rigatou A, et al. Distal versus traditional radial approach for coronary angiography. *Cardiovasc Revasc Med* 2019; 20(8): 678-80.