

## Complete Heart Block: A Case Report and Review of a Rare Manifestation of COVID-19

Mahsa Behnemoon<sup>(1)</sup>, Asghar Mohamadi<sup>(2)</sup>

### Case Report

#### Abstract

Covid19 is still one of the major public health problems of all countries nowadays. The most common cardiac manifestations reported till now are acute coronary syndrome, myocarditis, and arrhythmia. The prevalence of COVID-19 induced arrhythmias is different in recent reports and varies from benign sinus tachycardia to more ominous cases of severe bradycardia or even malignant ventricular arrhythmias. Here in, we describe a case of complete heart block in severe covid-19 pneumonia and review all recent relevant case reports published to date in order to understand the probable mechanisms and contributing factors of this rare complication of the disease.

**Keywords:** Covid-19; Pneumonia; Complete heart block

**Date of submission:** 2021-Jan-06, **Date of acceptance:** 2022-May-17

#### Introduction

In December 2019, Coronavirus Disease 2019 (COVID-19) emerged in Wuhan, China, and on March 11, 2020, the World Health Organization (WHO) declared the COVID-19 outbreak a pandemic.<sup>1</sup> The COVID-19 pandemic has affected people worldwide and caused countless hospitalizations and deaths.<sup>2</sup>

This disease is caused by a new coronavirus subtype that manifests as fever, cough, and breathing difficulties.<sup>3</sup> Although pulmonary symptoms are the most prevalent clinical manifestations of the new coronavirus, there have been reports of extra-pulmonary involvement, including thromboembolic events, myocardial dysfunction, arrhythmia, acute coronary syndrome, acute kidney injury, gastrointestinal symptoms, and dermatological problems, among others.<sup>4,5</sup>

Once the disease has affected the cardiovascular system, cardiac arrhythmias are among the most serious complications.<sup>6-8</sup> In the current study, we first describe a case of complete

heart block with severe COVID-19 pneumonia and otherwise normal cardiac structure, followed by a review of all relevant case reports published to date to determine the likely mechanisms and contributing factors underlying this rare complication.

#### Case Presentation

A 68-year-old male with a history of diabetes and renal transplant presented to our emergency department complaining of extreme fatigue and shortness of breath. Before admission, the patient had been experiencing flu-like symptoms, diarrhea, and extreme weakness for five days; COVID-19 RT-PCR and IgM antibody tests were positive.

**How to cite this article:** Behnemoon M, Mohamadi A. **Complete Heart Block: A Case Report and Review of a Rare Manifestation of COVID-19.** ARYA Atheroscler 2022; 18(6): 2357.

1- Department of Cardiology, Urmia University of Medical Sciences, Urmia, Iran

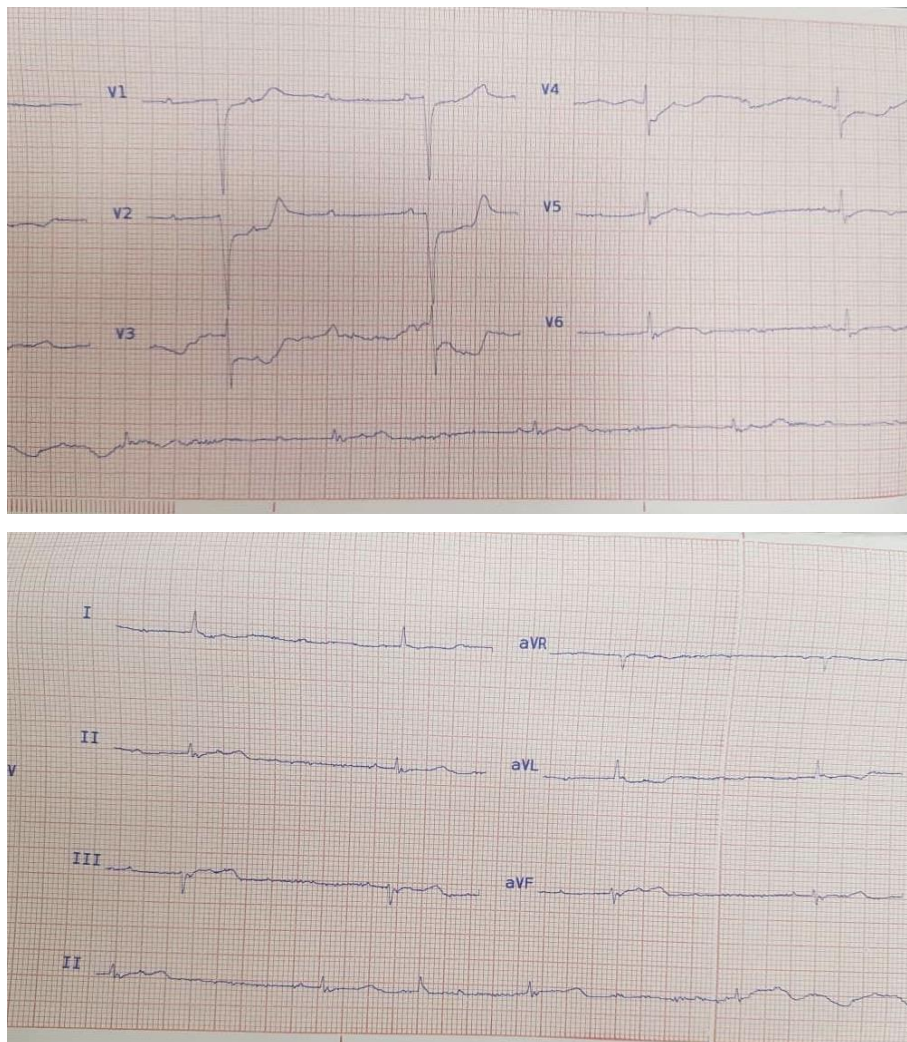
2- Cardiovascular Research Center, Shahid-Rahimi Hospital, Lorestan University of Medical Sciences, Khorramabad, Iran  
**Address for correspondence:** Asghar Mohamadi; Cardiovascular Research Center, Shahid-Rahimi Hospital, Lorestan University of Medical Sciences, Khorramabad, Iran. Tel: +989106042707. Fax: 06632228901. Email: drmazhin@gmail.com

Outpatient laboratory assessment revealed near-normal findings except for significant hyponatremia and moderate chronic anemia (Cr=1.4 mg/dl, K=4.6 meq/l, Na=124 meq/l, WBC=6700, lymph=39%, BS=190 mg/dl, Hb=8.9 g/dl). The patient's initial vital signs at the time of admission were significant for severe hypotension (70/30mmhg), bradycardia (35 bpm), and hypoxia (70% oxygen saturation on arterial blood gas examination).

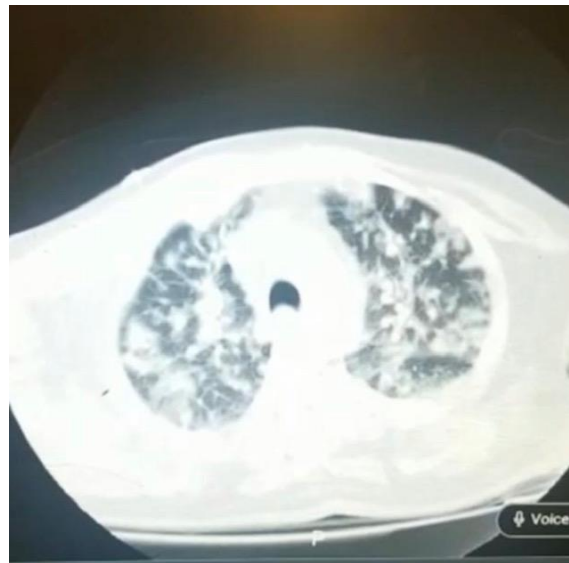By applying emergency face mask supplement oxygen, his saturation improved momentarily to 90%, allowing us to implant a temporary venous pacemaker (TPM) in our catheterization laboratory due to a complete heart block on his initial ECG (Figure 1).

Several years ago, he was prescribed oral anti-glycemic, immunosuppressive, and diltiazem medications, but he refused consumption at the onset of his symptoms due to extreme anorexia and nausea.

After TPM placement stabilized his heart rhythm, his blood pressure temporarily increased to 90/40 mmHg, and we were able to perform a chest CT scan to determine the cause of his persistent hypoxia. The scan revealed bilateral patchy and nodular consolidations in both central and peripheral zones, interlobular septal thickening, and pleural effusion, all of which were suggestive of COVID-19 pneumonia and probable bacterial or fungal superinfection (Figure 2).



**Figure 1.** ECG at the presentation consistent with CHB



**Figure 2.** A chest CT scan of the patient reveals patchy bilateral infiltrations in favor of COVID-19 pneumonia

In addition, echocardiography was performed to identify the potential underlying cardiac involvement as the cause of his complete heart block. However, it was unremarkable, with preserved left ventricular ejection fraction, moderate chronic mitral regurgitation, and normal size and function of the right ventricle without effusion. Despite initial supportive therapies and functional TPM, his oxygen saturation and blood pressure gradually decreased after 10 hours of admission, necessitating endotracheal intubation and vasopressor infusion. Unfortunately, the patient died several hours later due to severe respiratory failure.

### Discussion

Although the lungs are the primary organs affected by COVID-19 disease, the cardiovascular system is also impacted by this novel virus.<sup>7</sup> Cardiac manifestations include acute coronary syndrome, myocarditis, congestive heart failure, venous thromboembolic events, and arrhythmias.<sup>8</sup> There have been numerous reports of arrhythmias in myocarditis caused by the influenza virus, Epstein-Barr virus (EBV), and human immunodeficiency virus (HIV)<sup>9</sup>, but high-grade atrioventricular (AV) block is uncommon in the aforementioned viral infec-

tions.

After sinus tachycardia, atrial fibrillation (AF), Brady arrhythmias (e.g, sinus bradycardia), and nonsustained ventricular tachycardia (NSVT) are the most common arrhythmias reported in COVID-19.<sup>6</sup> The precise mechanism of the arrhythmia caused by COVID-19 is not completely understood; however, viral myocarditis, ischemia-induced AV block, electrolyte disturbance, as well as medication side effects, and hypoxia are among the potential causes.<sup>9</sup>

To date, there have been only 12 published case reports of complete heart block (CHB) in COVID-19 patients (including the current study). Two of these cases were observed during the recovery phase of the disease (after two months), while the remaining cases occurred during the acute phase.<sup>10-19</sup> In addition to our case where the patient died despite early TPM placement, two other cases reported patients who died from severe COVID-19 pneumonia despite having sinus rhythm prior to death<sup>15, 19</sup>; all other patients were discharged from the hospital without a major cardiac event. Half of the reported cases did not experience severe hypoxia or intubation prior to the onset of CHB.<sup>11-14, 16, 18</sup>

These findings suggest that CHB can occur even after complete disease recovery, most

likely due to post-infection myocarditis<sup>12</sup> and that the possible mechanism of death or intubation in these patients is not related to CHB itself; this hypothesis contrasts with Pavri's study, which concluded that involvement of the cardiac conduction system by COVID-19 may be a marker of increased mortality<sup>20</sup>, as most case reports of this complication have been discharged and followed up without significant sequels.

From all discharged case reports who experienced CHB during hospitalization, half were treated with a permanent dual chamber pacemaker (PPM) due to persistent CHB<sup>13,14,16-18</sup>, while the other half were free of bradyarrhythmia even after four weeks of follow-up.<sup>10-12,15,19</sup>

Only one patient out of 13 who received PPM and were monitored for an average of one month was predominantly in sinus rhythm, while the rest were dependent on the paced rhythm.<sup>14, 18</sup> The mentioned case of transient CHB was diagnosed as viral myocarditis by cardiac magnetic resonance imaging (CMR), which may suggest that in the case of myocarditis as a potential underlying cause for CHB, COVID-19 patients may benefit from close monitoring of symptoms and hemodynamic parameters in addition to supportive cares before PPM placement.<sup>13</sup>

The majority of reported cases of advanced AV block (8 of 13) occurred in patients who received drugs with possible effects on AV node conduction, such as sedatives, amiodarone, digoxin, beta-blockers, calcium channel blockers, and antiviral medication, prior to the onset of CHB (e.g., hydroxychloroquine, azithromycin, remdesivir). One patient (63-year-old male) with chronic atrial fibrillation rhythm and sick sinus syndrome required PPM prior to referral to a rehabilitation center.<sup>17</sup> Before death or discharge from the hospital, the remaining patients were all in sinus rhythm.<sup>11, 12, 15, 16, 19</sup> Among four patients with no reversible cause for CHB who were still alive, only one (a 72-year-old female) was discharged without PPM treatment due to the transient nature of the conduction abnormality.<sup>10, 13, 14, 18</sup>

We recommend that physicians be aware of the possibility of considering PPM as a final

rhythm control therapy for COVID-19 patients with persistent advanced levels of conduction disturbance without probable reversible mechanisms. Larger cohort studies with longer follow-up periods are required to make this hypothesis a consensus recommendation.

Most COVID-19 patients with CHB were male (10 out of 13). The majority had otherwise normal cardiac structure (9 out of 13 cases) and no prior medical history. In contrast, myocarditis and pulmonary embolism were reported in three and one patient, respectively, as possible mechanisms of conduction abnormality.<sup>11-13</sup> In the majority of cases, laboratory findings other than cell blood counts were within normal ranges, except for hyponatremia, which was an incidental finding in both Haddadin's case report and ours<sup>14</sup>, and multi-organ failure in the other two patients in a case series study.<sup>15</sup>

Another case of hyponatremia in a COVID-19 patient due to adrenal insufficiency (AI) secondary to a pituitary macroadenoma that was not accompanied by CHB and, therefore, unrelated to our review was reported.<sup>21</sup> In most cases, cardiac enzyme and troponin levels were within normal limits (except for 4 cases of definite myocarditis and pulmonary embolism discussed before). This evidence supports the possibility of an inflammatory process secondary to the direct invasion of the virus into the cardiac conduction system, without affecting the heart muscle in the majority of cases, and may explain the normal values of cardiac enzymes in the majority of CHB cases without underlying viral myocarditis.

As AV node involvement in other infectious etiologies, such as Lyme disease, is now well recognized via electrophysiological studies on patients with Lyme carditis<sup>22</sup>, it may support similar patterns and mechanisms of cardiac involvement in the novel coronavirus. Future electrophysiology studies can help us understand the exact mechanism of COVID-19 conduction system involvement in the new vaccination era against this ominous pandemic.

1- As a result of compiling all of these data, we can conclude the following about this rare complication of the disease, which requires confirmation by additional large-scale stud-

- ies: 1- Advanced AV block is best treated as a complication of COVID-19 pneumonia rather than as a side effect of administered antiviral drugs or required sedatives during intubation; male patients may be more susceptible.
- 2- CHB may occur even after complete recovery from the disease, most likely due to post-infection myocarditis despite negative PCR.
  - 3- The potential mechanism of death or intubation in COVID-19 patients is unrelated to CHB.
  - 4- In the case of transient and stable CHB, myocarditis should be considered (in addition to other reversible causes) as a potential underlying cause of this complication, and cases with a confirmed diagnosis of myocarditis may benefit from delayed PPM placement, in addition to close monitoring and other supportive cares.
  - 5- Future electrophysiology studies can help us comprehend the precise mechanism by which the COVID-19 conduction system is involved in the new vaccination era against this ominous pandemic.

### Conclusion

Even in the absence of viral myocarditis or ventricular dysfunction, complete heart block may be a complication of COVID-19 pneumonia. It is unknown whether this is associated with a poorer patient prognosis. However, it is preferable to treat it as a complication of COVID-19 pneumonia rather than as a side effect of antiviral or sedative drugs. According to reported cases, it may occur even a few months after the disease has been completely treated.

### References

1. Hajizadeh R, Behnemoon M. Is the new coronavirus disease (COVID-19) pandemic halted by malaria epidemics?. *Arch Bone Joint Surg* 2020; 8(Suppl 1): 319-20.
2. Wiersinga WJ, Rhodes A, Cheng AC, Peacock SJ, Prescott HC. Pathophysiology, transmission, diagnosis, and treatment of coronavirus disease 2019 (COVID-19): a review. *Jama* 2020; 324(8): 782-93.
3. Adhikari SP, Meng S, Wu YJ, Mao YP, Ye RX, Wang QZ, et al. Epidemiology, causes, clinical manifestation and diagnosis, prevention and control of coronavirus disease (COVID-19) during the early outbreak period: a scoping review. *Infect Dis Poverty* 2020; 9(1): 1-2.
4. Gupta A, Madhavan MV, Sehgal K, Nair N, Mahajan S, Sehrawat TS, et al. Extrapulmonary manifestations of COVID-19. *Nat Med* 2020; 26(7): 1017-32.
5. Bansal M. Cardiovascular disease and COVID-19. *Diabetes Metab Syndr* 2020; 14(3): 247-50.
6. Kochi AN, Tagliari AP, Forleo GB, Fassini GM, Tondo C. Cardiac and arrhythmic complications in patients with COVID-19. *J Cardiovas Electrophysiol* 2020; 31(5): 1003-8.
7. Bhatla A, Mayer MM, Adusumalli S, Hyman MC, Oh E, Tierney A, et al. COVID-19 and cardiac arrhythmias. *Heart Rhythm* 2020; 17(9): 1439-44.
8. Long B, Brady WJ, Koefman A, Gottlieb M. Cardiovascular complications in COVID-19. *Am J Emergency Med* 2020; 38(7): 1504-7.
9. Babapoor-Farrokhran S, Rasekhi RT, Gill D, Babapoor S, Amanullah A. Arrhythmia in COVID-19. *SN Compr Clin Med* 2020; 2(9): 1430-5.
10. Mohamed A. Complete heart block secondary to COVID-19. *Cureus* 2021; 13(5): e14970.
11. El-Assaad I, Hood-Pishchany MI, Kheir J, Mistry K, Dixit A, Halyabar O, et al. Complete heart block, severe ventricular dysfunction, and myocardial inflammation in a child with COVID-19 infection. *JACC Case Rep* 2020; 2(9): 1351-5.
12. Nikoo MH, Mozaffari R, Hatamnejad MR, Bazrafshan M, Kasaei M, Bazrafshan H. Systolic dysfunction and complete heart block as complications of fulminant myocarditis in a recovered COVID-19 patient. *J Cardiol Cases* 2021; 24(4): 177-81.
13. Al-Assaf O, Mirza M, Musa A. Atypical presentation of COVID-19 as subclinical myocarditis with persistent high-degree atrioventricular block treated with pacemaker implant. *Heart Rhythm Case Rep* 2020; 6(11): 884-7.
14. Haddadin FI, Mahdawi TE, Hattar L, Beydoun H, Fram F, Homoud M. A case of complete heart block in a COVID-19 infected patient. *J Cardiol Cases* 2021; 23(1): 27-30.
15. Mahdawi TE, Wang H, Haddadin FI, Al-Qaysi D, Wylie JV. Heart block in patients with coronavirus

- disease 2019: a case series of 3 patients infected with SARS-CoV-2. *HeartRhythm Case Rep* 2020; 6(9): 652-6.
16. Hosseini Z, Ghodsi S, Hejazi SF. Persistent complete heart block in a patient with COVID-19 infection: a case report. *SN Comprehen Clin Med* 2021; 3(1): 259-62.
  17. Villasmil RJ, Lorenzo CJ, Abdelal QK, Conte JI, Lattanzio N. Complete Heart Block in a Patient with COVID-19. *Int Arch Cardiovasc Dis* 2021; 5(1): 039.
  18. Maknojia A, Gilani A, Ghatak A. Complete Heart Block: A Rare Presentation of COVID-19. *Cath Lab Digest* 2021; 29(5).
  19. Azarkish M, Laleh Far V, Eslami M, Mollazadeh R. Transient complete heart block in a patient with critical COVID-19. *Eur Heart J* 2020; 41(22): 2131.
  20. Pavri BB, Kloo J, Farzad D, Riley JM. Behavior of the PR interval with increasing heart rate in patients with COVID-19. *Heart rhythm* 2020; 17(9): 1434-8.
  21. Merino JC, Reyes LM, Gravalos TL, Conde AR, Del Pozo MR. An unusual case of severe acute hyponatremia in patient with COVID-19 infection. *Nefrología* 2020; 40(3):356-8.
  22. Steere AC, Batsford WP, Weinberg M, Alexander J, Berger HJ, Wolfson S, et al. Lyme cardi-tis: cardiac abnormalities of Lyme disease. *Ann Int Med* 1980; 93(1): 8-16.