



## Large pericardial mesothelial cyst coexisting with hypertrophic obstructive cardiomyopathy

Anita Sadeghpour<sup>(1)</sup> , Alireza Alizadeh-Ghavidel<sup>(2)</sup>, Kambiz Mozaffari<sup>(3)</sup>,  
Hamidreza Pouraliakbar<sup>(4)</sup>, Behshid Ghadrdoost<sup>(5)</sup>, Mohaddeseh Behjati<sup>(6)</sup> ,

### Case Report

#### Abstract

**BACKGROUND:** Pericardial mesothelioma cyst occurs rarely, and is often found incidentally. The coexistence between large pericardial mesothelial cyst and hypertrophic obstructive cardiomyopathy (HOCM) can make difficulties in medical management.

**CASE REPORT:** Our case was a 33-year-old man presented with dizziness and pallor while standing since four years before, and recent syncope. On admission, transthoracic echocardiography revealed presence of hypertrophic cardiomyopathy in association with relatively small right ventricular and atrium due to compression effect by a large echo-free space at the right side of heart suggestive of pericardial cyst. Cardiac computed tomography confirmed presence of HOCM and large pericardial cyst. Patient underwent surgical septal myectomy and large mesothelial pericardial cyst excision because of persistent symptoms and compression effect of cyst on the right chambers despite beta-blocker therapy.

**CONCLUSION:** To best of our knowledge, the coexistence of the large pericardial mesothelial cyst and HOCM has not been reported before.

**Keywords:** Mesothelioma; Pericardial Cyst; Cardiomyopathy Hypertrophic Obstructive

*Date of submission:* 14 Apr. 2019, *Date of acceptance:* 26 Oct. 2019

#### Introduction

Pericardial mesothelioma cyst, or so-called benign cystic mesothelioma, occur with an incidence of approximately one per 100,000.<sup>1</sup> These cysts are commonly with few symptoms, and are often found incidentally.<sup>2</sup> The coexistence between large pericardial mesothelial cyst and hypertrophic obstructive cardiomyopathy (HOCM) has not been reported before. Hereby, we report coexistent large pericardial mesothelial cyst and HOCM, which can make difficulties in medical management; as when the cyst is large size with compressive effect on the right chambers, giving high dose of beta-blockers would be risky.

#### Case Report

Our case was a 33-year-old man presented with dizziness and pallor while standing since last four years, which the last time was associated with syncope and face trauma; so, patient was admitted. He had positive family of sudden cardiac death in his

**How to cite this article:** Sadeghpour A, Alizadeh-Ghavidel A, Mozaffari K, Pouraliakbar H, Ghadrdoost B, Behjati M. **Large pericardial mesothelial cyst coexisting with hypertrophic obstructive cardiomyopathy.** ARYA Atheroscler 2020; 16(2): ????.

1- Professor, Department of Cardiology, Echocardiography Research Center, Rajaie Cardiovascular Medical and Research Center, Iran University of Medical Sciences, Tehran, Iran

2- Associate Professor, Department of Cardiac Surgery, Heart Valve Research Center, Rajaie Cardiovascular Medical and Research Center, Iran University of Medical Sciences, Tehran, Iran

3- Assistant Professor, Department of Pathology, Rajaie Cardiovascular Medical and Research Center, Iran University of Medical Sciences, Tehran, Iran

4- Associate Professor, Department of Radiology, Rajaie Cardiovascular Medical and Research Center, Iran University of Medical Sciences, Tehran, Iran

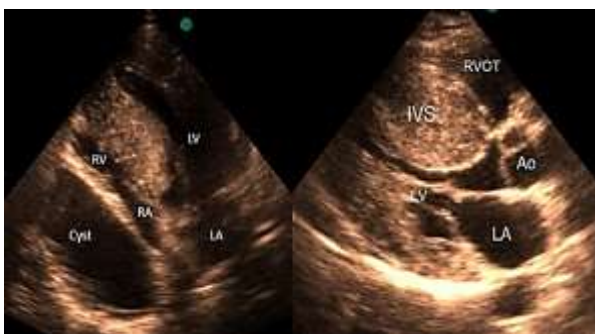5- Assistant Professor, Department of Physiology, Rajaie Cardiovascular Medical and Research Center. Iran University of Medical Sciences, Tehran, Iran

6- Fellowship, Echocardiography Research Center, Rajaie Cardiovascular Medical and Research Center, Iran University of Medical Sciences, Tehran, Iran

Address for correspondence: Mohaddeseh Behjati; Fellowship, Echocardiography Research Center, Rajaie Cardiovascular Medical and Research Center, Iran University of Medical Sciences, Tehran, Iran; Email: [dr.mohaddesehbehjati@gmail.com](mailto:dr.mohaddesehbehjati@gmail.com)

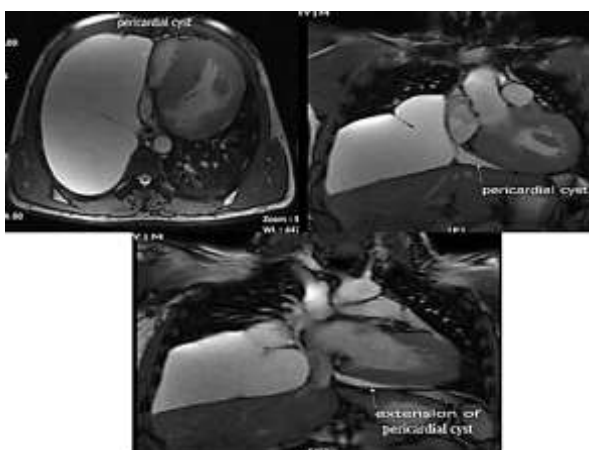
father at the age of 43 years old.

Chest X-ray showed large cystic lesion in right lung space. Transthoracic echocardiography showed normal left ventricular size and mild systolic dysfunction, severe left ventricular hypertrophy with significant asymmetric septal hypertrophy, severe systolic anterior motion resulting in significant left ventricular outflow tract (LVOT) obstruction consistent with HOCM (maximal late peaking gradient at rest = 64 mmHg), and relatively small right ventricular size due to compression effect of a large echo-free space at the right side of heart suggestive of pericardial cyst, which had compressive effect on right atrium, too (Figure 1).



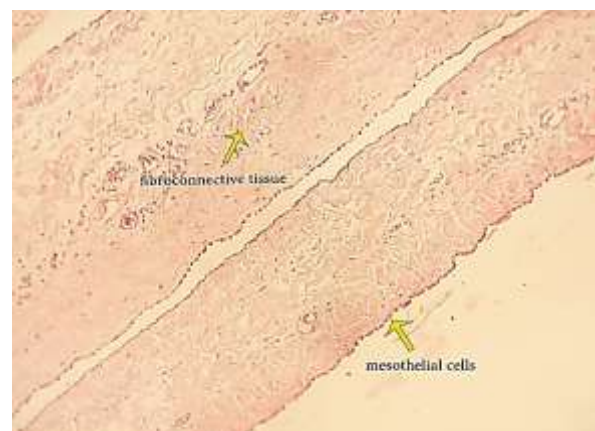**Figure 1.** Transthoracic echocardiography view demonstrates the presence of hypertrophic obstructive cardiomyopathy

Cardiac computed tomography (CT) scan confirmed the presence of HOCM, and introduced the echo-free space as a large pericardial cyst (Figure 2). After electrophysiology consultation and rule out of ventricular arrhythmia, myectomy and excision of pericardial cyst was recommended.



**Figure 2.** Cardiac computed tomography (CT) demonstrates an echo-free space as a large pericardial cyst in association with hypertrophic obstructive cardiomyopathy (HOCM)

He underwent transaortic surgical septal myectomy via a standard median sternotomy, and by surgical exploration, a large cyst was found attached to the pericardium, anterior of right phrenic nerve, with 5 cm distance from diaphragm, and was extended totally into right pleural space. The cyst was excised and macroscopic examination showed the cystic pieces (12 × 12 × 3 cm) with smooth interior wall and wall thickness of about 1 mm, consistent with mesothelial cyst. Microscopic evaluation [hematoxylin and eosin (H&E) ×100] identified thin-walled cyst lined by single cell lining of non-pleomorphic cells with abundant eosinophilic cytoplasm, vesicular nuclei, and small nucleoli (Figure 3).



**Figure 3.** Fibroconnective tissue lined by a layer of mesothelial cells in microscopic evaluation

## Discussion

HOCM is a genetic disease with various presentations as heart failure, arrhythmia, sudden cardiac death, and so on. Indications for septal myectomy, as gold standard therapy, include symptomatic patients with left ventricular outflow tract gradient of more than 50 mmHg, and symptoms refractory to medical therapy.<sup>3</sup>

Pericardial cysts are often intrathoracic and most common are considered as congenital cysts.<sup>4</sup> Congenital cysts are fluid-filled enclosed space, lined by mesothelial cells.<sup>5</sup> These cysts are often found incidentally, and are benign lesions. Treatment is just advocated for symptomatic cases due to compression effect of cyst. The differentiation between pericardial and plural cyst are most often straight forwards; but in some circumstances, it would be difficult. Pericardial cysts have no communication with pericardial space, but attached to pericardium directly or by a pedicle.<sup>6</sup> Mesothelial cysts occur due to aberration in

formation of somatic cavities.<sup>7</sup> To best of our knowledge, the coexistence of large mesothelial cyst and HOCM has not been reported previously.

Coexisted large pericardial mesothelial cyst and HOCM is a rare abnormality, which make difficulties in medical management; since giving beta-blocker in HOCM is treatment of choice. But in the presence of a large cyst with compressive effect on the right chambers, giving high dose of beta-blocker would be risky. Despite the fact that coexisting of HOCM and mesothelial cysts can be an incidental finding, the possible common genetic origin can be assessed.

### Acknowledgments

We thank all colleagues who collaborate with us in Rajaie Cardiovascular Medical and Research Center, Tehran, Iran.

### Conflict of Interests

Authors have no conflict of interests.

### References

1. Sharma R, Harden S, Peebles C, Dawkins KD. Percutaneous aspiration of a pericardial cyst: An acceptable treatment for a rare disorder. *Heart* 2007; 93(1): 22.
2. Elamin WF, Hannan K. Pericardial cyst: An unusual cause of pneumonia. *Cases J* 2008; 1(1): 26.
3. van der Wall EE. New ESC guidelines on hypertrophic cardiomyopathy: New insights in invasive treatment? *Neth Heart J* 2015; 23(1): 1-3.
4. Comoglio C, Sansone F, Delsedime L, Campanella A, Ceresa F, Rinaldi M. Mesothelial cyst of the pericardium, absent on earlier computed tomography. *Tex Heart Inst J* 2010; 37(3): 354-7.
5. Klein AL, Abbara S, Agler DA, Appleton CP, Asher CR, Hoit B, et al. American Society of Echocardiography clinical recommendations for multimodality cardiovascular imaging of patients with pericardial disease: Endorsed by the Society for Cardiovascular Magnetic Resonance and Society of Cardiovascular Computed Tomography. *J Am Soc Echocardiogr* 2013; 26(9): 965-1012.
6. Michelotto E, Tarantino N, Ostuni V, Pedote P, Colonna P, Guglielmi R. An Uncommon Pericardial Cyst in the Central Mediastinum: Incremental Diagnosis with Contrast-Enhanced Three-Dimensional Transesophageal Echocardiography. *J Cardiovasc Echogr* 2013; 23(4): 106-10.
7. Patel S, Hajmedi P, Fischbein J. Common symptoms with rare entity: A giant pericardial cyst. *Am J Med* 2015; 128(10): e27-e28.