




## Youngest documented rheumatic mitral stenosis with regurgitation in a 28-month-old girl

**Santosh Kumar Sinha**<sup>(1)</sup> , **Mohammad Asif**<sup>(2)</sup>, **Vikas Mishra**<sup>(2)</sup>,  
**Mahmodulla Razi**<sup>(3)</sup>, **Vinay Krishna**<sup>(4)</sup>

### Case Report

#### Abstract

**BACKGROUND:** Acute rheumatic fever (ARF) and rheumatic heart disease (RHD) are the leading causes of acquired diseases in children and young adults in developing countries carrying considerable morbidity and mortality. Rheumatic fever (RF) commonly affects children between 5-15 years old and is rarely seen in < 5 years old. Mitral stenosis (MS) is the most common sequela, as it bears maximum onslaught. In India, few patients follow an unusually rapid course in developing severe MS because of its fulminant nature following attack of ARF.

**CASE REPORT:** Our patient was a 28-month-old girl who had developed severe MS, mitral regurgitation (MR), and pulmonary hypertension (PH) as the sequelae of ARF which she had suffered at the age of 18 months old.

**CONCLUSION:** To the best of our knowledge, this is the youngest reported case of rheumatic MS following ARF after extensive search in the literature. This case highlights the fact that very young population is not immune to ARF contrary to prior belief and therefore, more stringent preventive measures need to be implemented for it and possibility of ARF should be kept in mind while evaluating carditis in a child.

**Keywords:** Acute Rheumatic Fever, Mitral Stenosis, Mitral Regurgitation, Pulmonary Hypertension

*Date of submission:* 30 Dec. 2017, *Date of acceptance:* 15 Sep. 2019

#### Introduction

Rheumatic fever (RF) is an autoimmune disorder, being a hypersensitivity reaction of immune system to group A beta-hemolytic streptococci (GABHS) strain. With the passage of time, it is on a declining path which began prior to introduction of modern antibiotic and accelerated with introduction of penicillin. Decline in preantibiotic era was due to improvement in environmental factors, decrease in rheumatogenicity of streptococcal strain, and improved specificity in diagnosis. Rheumatic heart disease (RHD), a sequela of RF, continues to be the major health hazard in most developing countries. Recent resurgence of RF in developing countries may be due to change in virulence of the existing strain, emergence of new strain, increased overcrowding and poor sanitation due to population explosion, and improper implementation of preventive measures. As a result, cases have been reported in much younger population (< 5 years old)

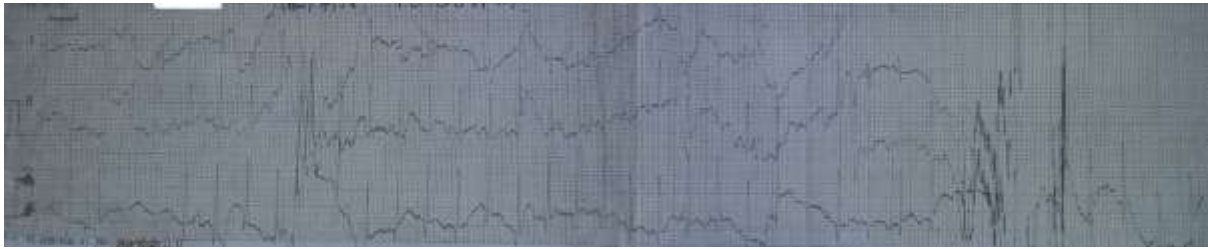with its devastating consequences. Rheumatic mitral stenosis (MS) may rarely occur in children < 5 years of age, wherein rapid hemodynamic progression and cardiac morbidity and mortality may occur.

#### Case Report

An 18-month girl weighing 10 kg was admitted to our hospital with complaints of respiratory distress, poor feeding, and irritability for past 2 weeks. Her past history included low-grade fever and sore throat which subsided by itself. There was no exanthem accompanying fever. After an interval of few weeks, arthralgia of knee and ankle joints was noted.

**How to cite this article:** Sinha SK, Asif M, Mishra V, Razi M, Krishna V. **Youngest documented rheumatic mitral stenosis with regurgitation in a 28-month-old girl.** ARYA Atheroscler 2019; 15(6): ??-?

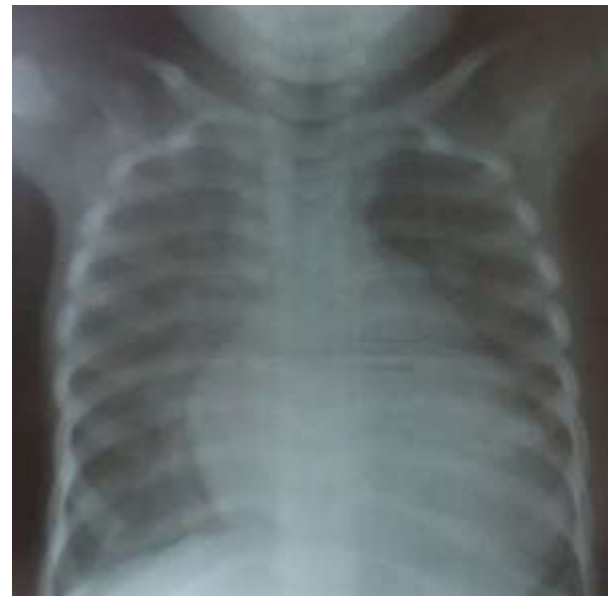- 1- Associate Professor, Department of Cardiology, Ganesh Shankar Vidyarthi Memorial Medical College, LPS Institute of Cardiology, Kanpur, Uttar Pradesh, India
  - 2- Senior Registrar, Department of Cardiology, Ganesh Shankar Vidyarthi Memorial Medical College, LPS Institute of Cardiology, Kanpur, Uttar Pradesh, India
  - 3- Assistant Professor, Department of Cardiology, Ganesh Shankar Vidyarthi Memorial Medical College, LPS Institute of Cardiology, Kanpur, Uttar Pradesh, India
  - 4- Department of Cardiology, Ganesh Shankar Vidyarthi Memorial Medical College, LPS Institute of Cardiology, Kanpur, Uttar Pradesh, India
- Correspondence to: Santosh Kumar Sinha, Email: [fionasan@rediffmail.com](mailto:fionasan@rediffmail.com)



**Figure 1.** Electrocardiogram (ECG) at initial presentation in a 18-month-old girl

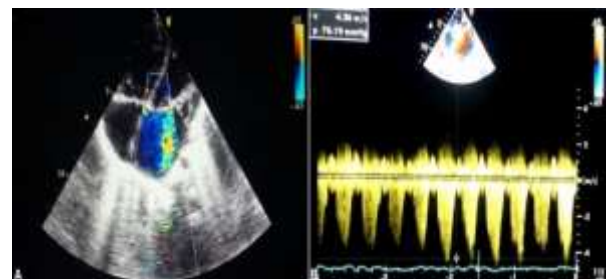
It was so painful as she refused to crawl. It was not accompanied by swelling and redness and was non-migratory. Her arthralgia got dramatic relief after treatment with analgesics containing salicylates as advised by her paediatrician. The parents denied any history of vomiting, involuntary movements, urinary problem, redness of tongue, swelling in neck, and desquamative lesions. Birth, family, and past histories were insignificant except that she had been fed with formula milk till 9 months of age. She was referred to unit of paediatric cardiology. On examination, blood pressure (BP) and pulse rate were 82/54 mmHg and 140 beats per minute (bpm), respectively. On cardiovascular system examination, apex beat was situated in 6<sup>th</sup> intercostal space, 1 cm lateral to midclavicular line which was hyperdynamic in character. There was grade I parasternal heave. On auscultation, the first heart sound (S1) was soft, second heart sound (S2) was wide with variable split with loud pulmonic component (P2), and the third heart sound (S3) was audible. There was a soft, blowing grade 3/6 pansystolic murmur which was best audible at apex although it was also radiating to axilla. Bilateral fine basal crepitations were also present. There was tender hepatomegaly, palpable 2 cm below the right subcostal margin. Electrocardiogram (ECG) indicated sinus tachycardia (Figure 1). Chest X-ray revealed cardiomegaly with evidence of pulmonary venous hypertension (PVH) (Figure 2). Routine haemogram revealed normal leukocyte and platelet count and mild anaemia. Antistreptolysin O (ASO) titer, C-reactive protein (CRP), and erythrocyte sedimentation rate (ESR) were 653 IU/ml (normal limit: 240 IU/ml), 98 mg/l, and 88 mm in 1 hour, respectively, whereas antinuclear antibody (ANA) and troponin level were negative. Echocardiogram revealed dilated left atrium and left ventricle. Color Doppler interrogation showed severe mitral regurgitation (MR) as confirmed by presence of jet in  $\geq 2$  views, jet length  $\geq 2$  cm in at least 1 view, peak velocity  $> 3$  m/s, and pansystolic jet in at least 1 envelope along with tricuspid regurgitation (TR) with  $V_{max}/PG_{max}$  of 4.36 m.sec/76 mmHg. Left

ventricular function was within normal limit (Figures 3A, 3B).



**Figure 2.** Chest X-ray showing cardiomegaly with pulmonary venous hypertension (PVH) during the first episode of rheumatic carditis

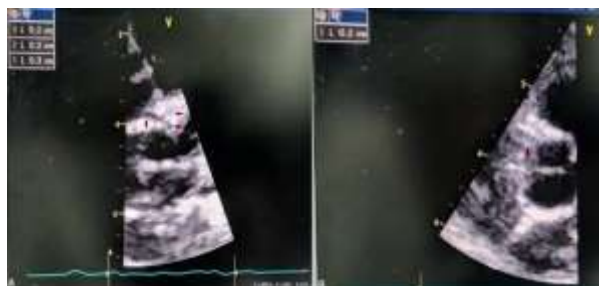
Juvenile rheumatoid arthritis (JRA) was ruled out; patient had only arthralgia which got relieved with salicylates and had severe carditis which is not seen in JRA. Collagen vascular disorders were ruled out by negative ANA and presence of severe carditis.



**Figure 3.** Severe mitral regurgitation (MR) (A) with tricuspid regurgitation (TR) (B) during the first episode of rheumatic carditis

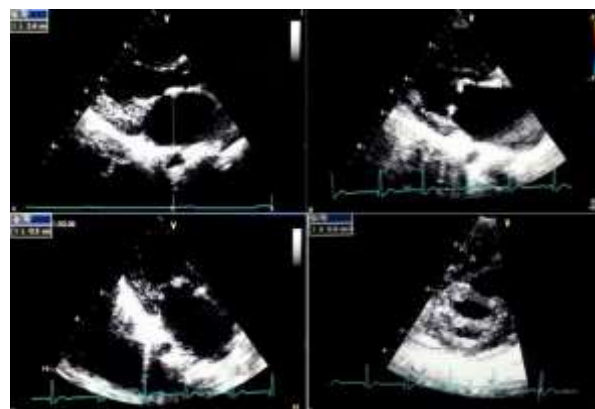
Fever without exanthem and severe carditis

ruled out viral disorders like rubella, herpes virus, and parvovirus. Viral myocarditis was ruled out with characteristic arthralgia, negative troponin level, lack of any left ventricular dysfunction, and characteristic jet of MR on echocardiogram. Kawasaki disease was ruled out as fever was not accompanied by rash, lymphadenopathy, and desquamative lesions, and platelet count and diameter of proximal coronary arteries were normal (Figure 4).



**Figure 4.** Parasternal short-axis (PSAX) view showing proximal diameter of coronary arteries (left main coronary artery, left anterior descending artery, circumflex artery) (A); right coronary artery (B)

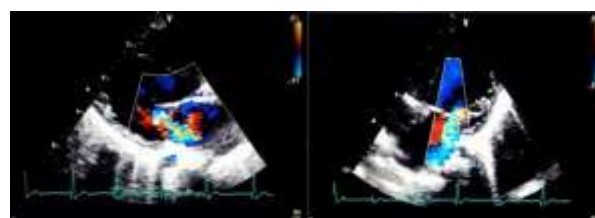
The baby was managed with supportive therapy including benzathine penicillin 0.6 million units intramuscularly, intravenous furosemide 1mg/kg twice daily, and prednisolone 2 mg/kg in four divided doses daily. She was stabilized after 5 weeks when ESR and CRP level came to normal. Aspirin 90 mg/kg in four divided doses daily was started after 5 weeks, tapered to 60 mg/kg after two weeks, and continued for 3 months while prednisolone was continued for 6 weeks. She was discharged in stable condition with haematinic for anaemia correction and benzathine penicillin 0.6 million units intramuscularly every 3 weeks. With treatment, the patient improved symptomatically. MR was persisting at the time of discharge though her congestive symptoms resolved. On the follow-up after 8 months, S1 was loud, S2 was loud with wide variable split, and a long mid diastolic rumble with presystolic accentuation was heard along with pansystolic murmur of mitral leak on auscultation. Her echocardiogram revealed severe MS as mitral valve area (MVA) was 0.9 cm<sup>2</sup> (1.1 cm<sup>2</sup>/m<sup>2</sup> body surface area), thickened mitral leaflets (5 mm), fixed posterior mitral leaflet (PML), and doming of anterior mitral leaflet (AML) imparting characteristic hockey stick appearance, commissural fusion, and enlarged left atrium (Figure 5) with severe MR (Figure 6). She was referred to cardiovascular surgery department for possible repair or replacement.



**Figure 5.** Severe mitral stenosis (MS) on follow-up after 8 months interval: enlarged left atrium (A); characteristic hockey stick appearance of anterior mitral leaflet (AML) and fixed posterior mitral leaflet (PML) (B); thickened mitral leaflet (C); fish mouth appearance with mitral valve area (MVA) of 0.9 cm<sup>2</sup> by planimetry (D)

## Discussion

Although acute rheumatic fever (ARF) has declined in developed nations in the past 5 decades, it still remains one of the most important causes of cardiovascular morbidity and mortality among socioeconomically-challenged populations in the developing countries where its incidence reaches epidemic levels.<sup>1-3</sup>



**Figure 6.** Severe chronic mitral regurgitation (MR) on follow-up after 8 months interval; A: Parasternal long axis view, B: Apical 4 chamber view

ARF is a host's immunological response to infection by GABHS. It is rare below six months of age as babies are protected from maternal antibodies transferred transplacentally and later on as they are breastfed which gives similar degree of protection. In our case, she was fed on formula milk which might have been one of the reasons that first episode of ARF occurred at 18 months of age. MS is rarely seen in children and adolescents except in developing countries where RF is still very common.<sup>4-6</sup> MS may rarely be congenital. Congenital MS occurs due to the presence of supralvalvular ring of the left atrium, accessory mitral valve tissue (AMVT), congenital commissural

fusion, shortened chordae tendinae, anomalous mitral arcade, anomalous position of the papillary muscles, and parachute mitral valve (PMV). Firstly, these features were not seen in our case. Secondly, the temporal development of MS in the background of mitral leak is seen only as a sequela of ARF. Furthermore, echocardiographic findings were pathognomonic of rheumatic MS in our case (Figure 5). Latent period for rheumatic MS to manifest is 10-30 years in developing countries, whereas it may be as long as 50 years in developed countries after the initial episode of ARF. In developing countries like India, early evidence of MS may develop as early as the teenage years, presumably because of a more aggressive initial attack and/or recurrent bouts of RF which has been coined as juvenile MS (JMS).<sup>4</sup> RF causes more often moderate to severe carditis with milder form of arthritis or sometimes only arthralgia when presents in age less than 5 years compared to older individuals.<sup>1</sup> Among the few case reports of RHD in children aged < 5 years, the youngest patient documented till now was a 2 year and 6 months old.<sup>7</sup> Our case was just 20 months old at the time of rheumatic carditis and 28 months old at the time of RHD, the youngest of JMS with severe MR ever reported. This is also unique and surprising that the patient developed stenosis within a span of just 8 months which shows complex interplay of host genetic susceptibility, immune response, environmental influence, and virulence of GABHS. As the younger age is associated with more severe valvulitis, prompt recognition and treatment of sore throat because of GABHS should be done. Therefore, ARF may occur in babies in their second year of life when severe carditis may accompany mild arthralgia. Furthermore, ARF may present with only arthralgia as the earliest manifestation and therefore opportunity to diagnose it may be missed

as it appears minor to the family. Severe MS may occur as early as 10 months following onset of acute rheumatic carditis as a result of virulent strain and infidel genetic susceptibility, and exuberant immune response may be the responsible factor behind such a malignant course and outcome of RF.

### Acknowledgments

None.

### Conflict of Interests

Authors have no conflict of interests.

### References

1. Tani LY, Veasy LG, Minich LL, Shaddy RE. Rheumatic fever in children younger than 5 years: Is the presentation different? *Pediatrics* 2003; 112(5): 1065-8.
2. Stollerman GH. Rheumatic fever in the 21<sup>st</sup> century. *Clin Infect Dis* 2001; 33(6): 806-14.
3. Seckeler MD, Hoke TR. The worldwide epidemiology of acute rheumatic fever and rheumatic heart disease. *Clin Epidemiol* 2011; 3: 67-84.
4. Roy SB, Bhatia ML, Lazaro EJ, Ramalingaswami V. Juvenile mitral stenosis in India. *Lancet* 1963; 2(7319): 1193-5.
5. Reale A, Colella C, Bruno AM. Mitral stenosis in childhood: Clinical and therapeutic aspects. *Am Heart J* 1963; 66: 15-28.
6. Bhayana JN, Khanna SK, Gupta BK, Sharma SR, Gupta MP, Padmavati S. Mitral stenosis in the young in developing countries. *J Thorac Cardiovasc Surg* 1974; 68(1): 126-30.
7. Sarkar A, Patil S, Ahmed I. Balloon mitral valvotomy in youngest documented rheumatic mitral stenosis patient. *Catheter Cardiovasc Interv* 2015; 86(5): E213-E216.